

# Imaging Knee/Ankle/Foot Case Based

February 1-5, 2017

ACSM Team Physician<sup>SM</sup> Course – Part II

## Essentials of Sports Medicine: From Sideline to the Clinic

**Mary Lloyd Ireland, M.D.**

Associate Professor

University of Kentucky

Dept. of Orthopaedic Surgery and  
Sports Medicine

Lexington, Kentucky

[www.MaryLloydIreland.com](http://www.MaryLloydIreland.com)

**San Diego**

Sheraton San Diego  
Hotel & Marina  
San Diego, California



**AMERICAN COLLEGE  
of SPORTS MEDICINE**  
LEADING THE WAY



**ACSM  
TEAM  
PHYSICIAN<sup>SM</sup>  
COURSE** Part II  
AMERICAN COLLEGE of SPORTS MEDICINE

## Menu

## KNEE

### Patellar Dislocation

### Meniscus Tear

- Skeletally Immature

### OCD

### Extensor Mechanism Injuries

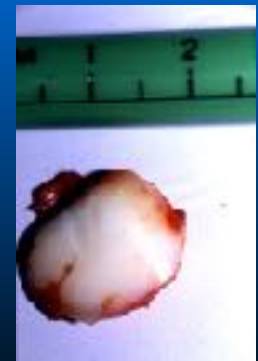
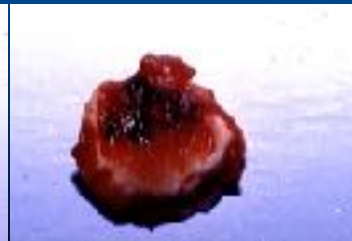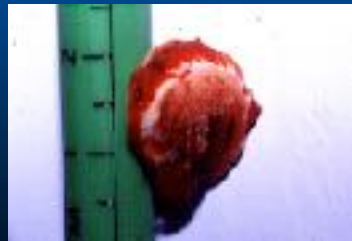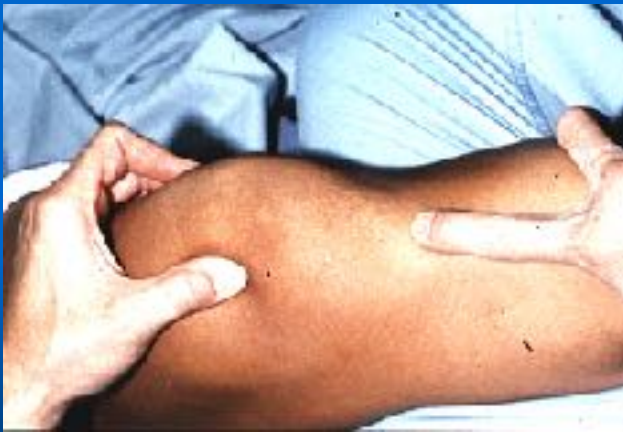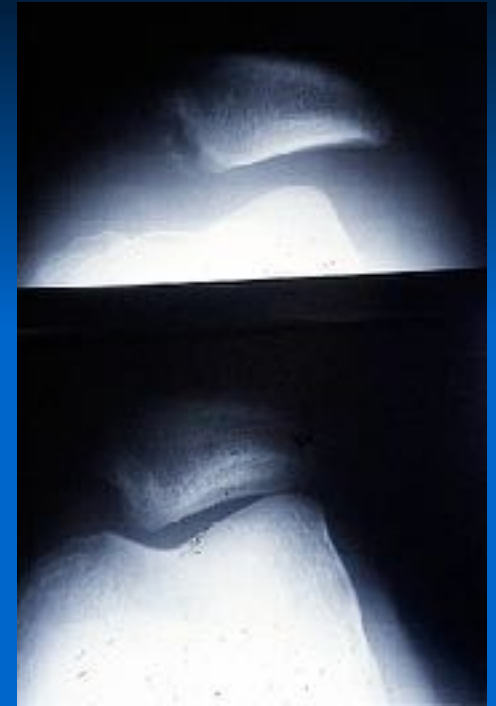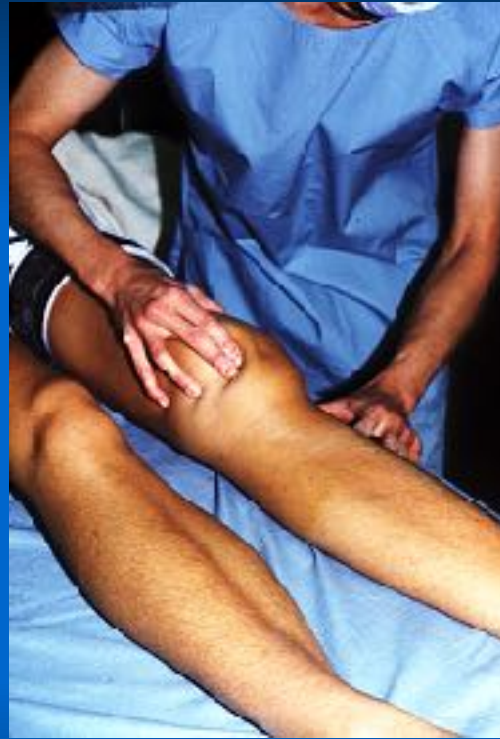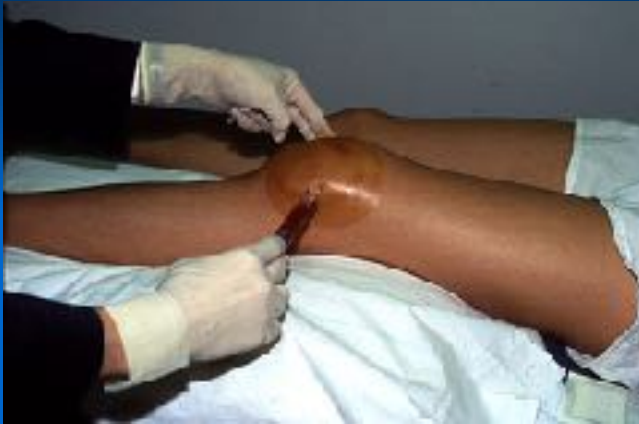- Skeletally Immature
- Mature
- Tumors

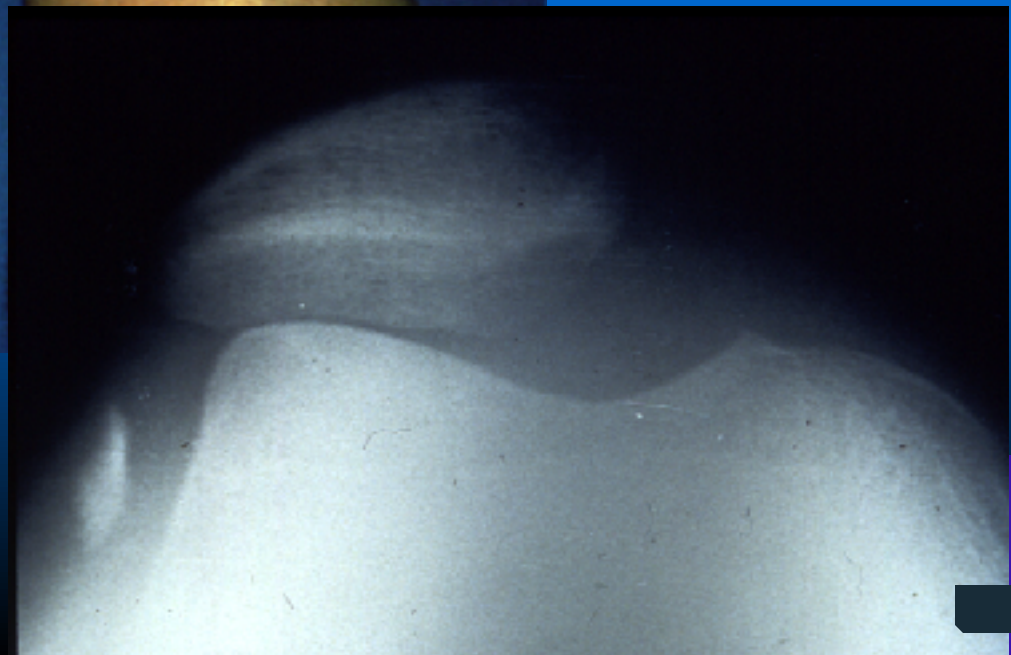
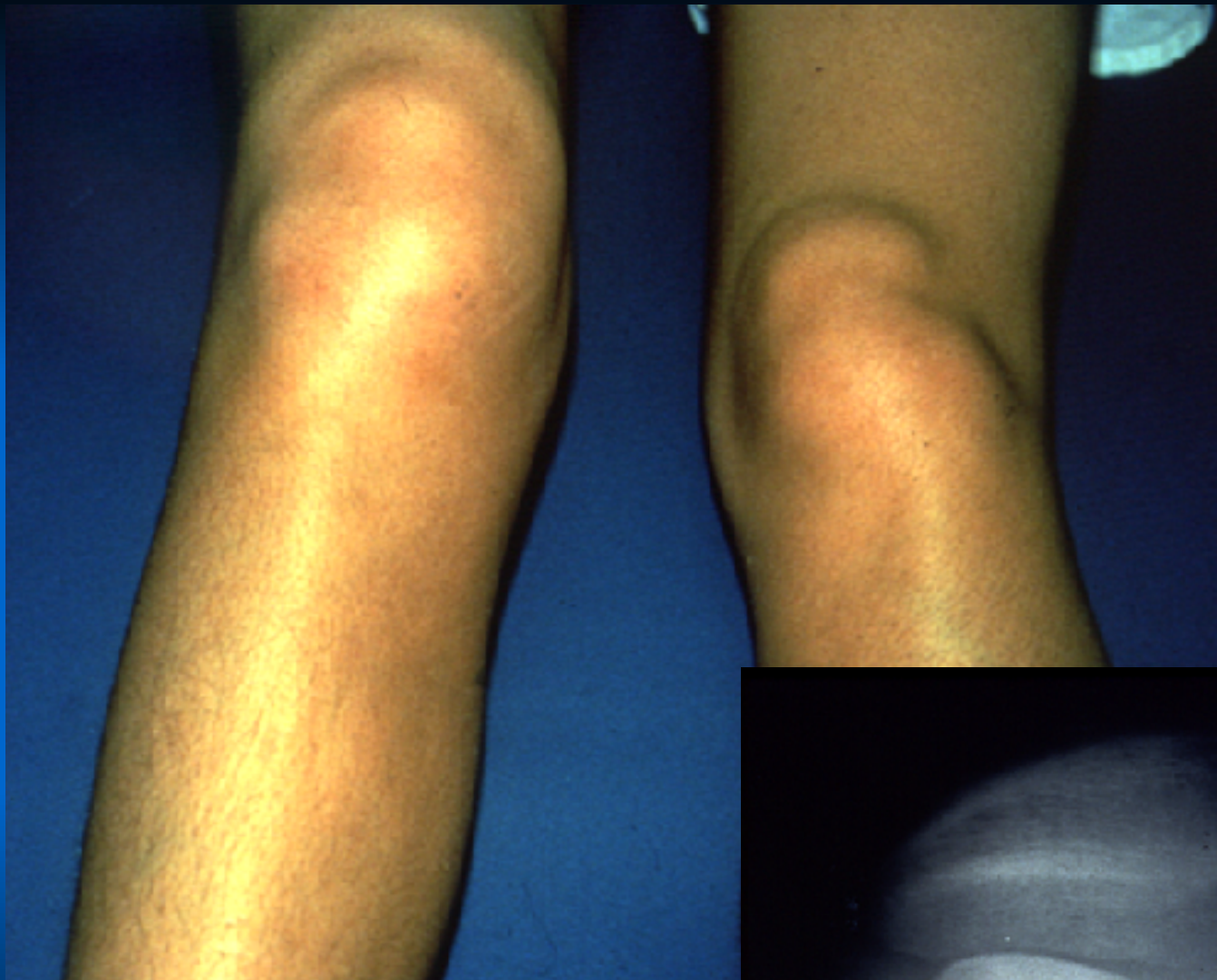
## ANKLE / FOOT

- Tillaux Fracture
- Toe / Foot

### The End

# Patellar Dislocations







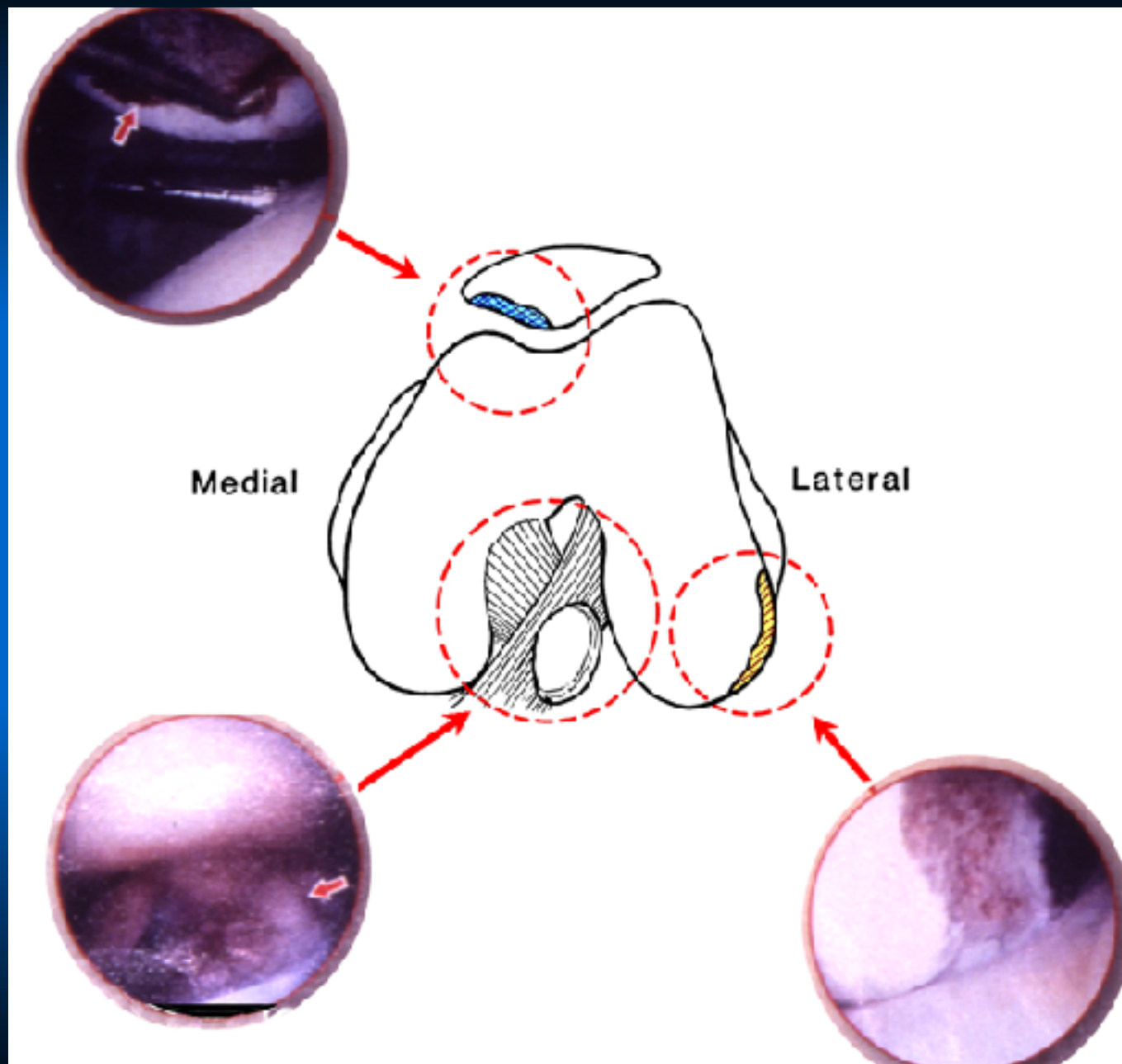
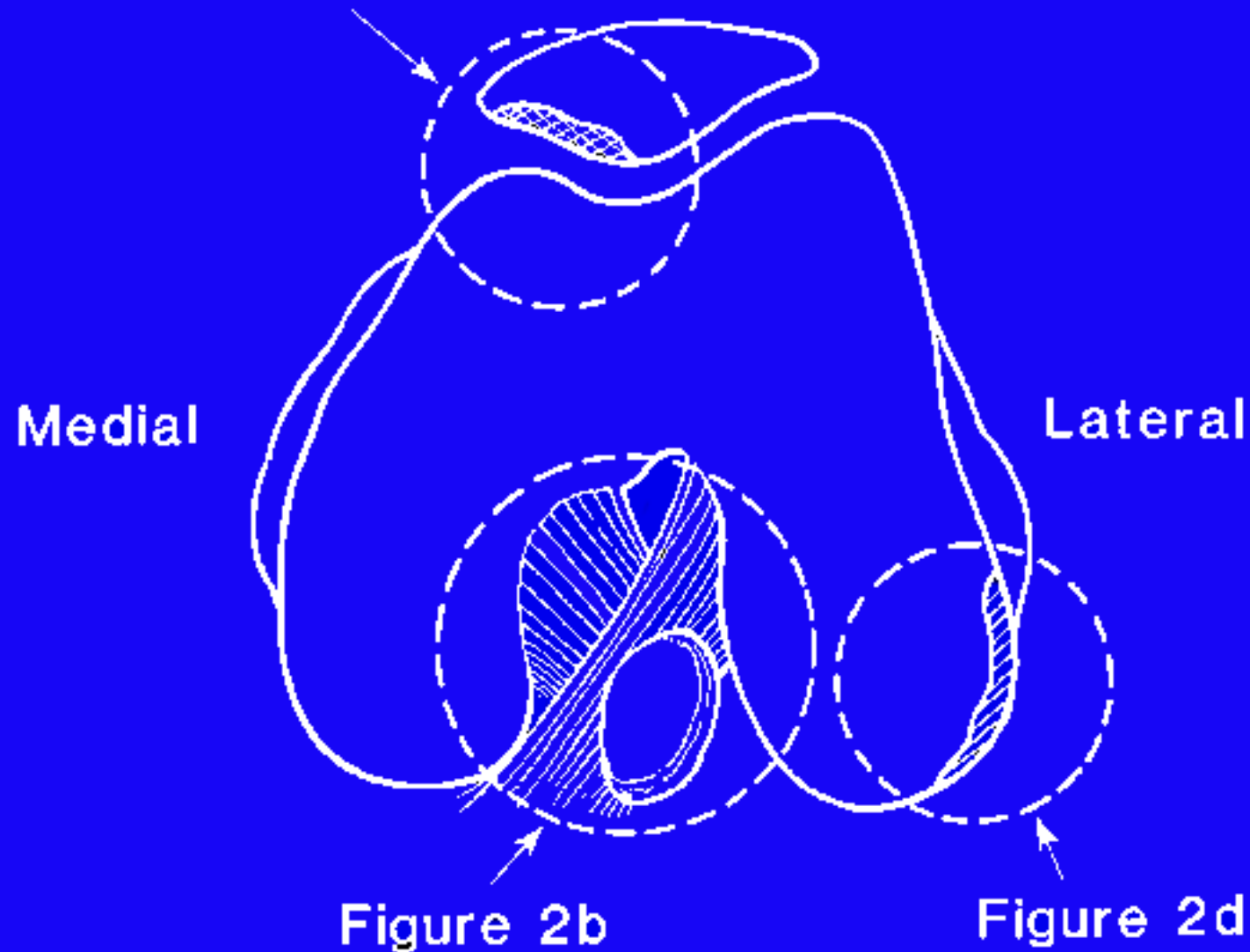


Figure 2c

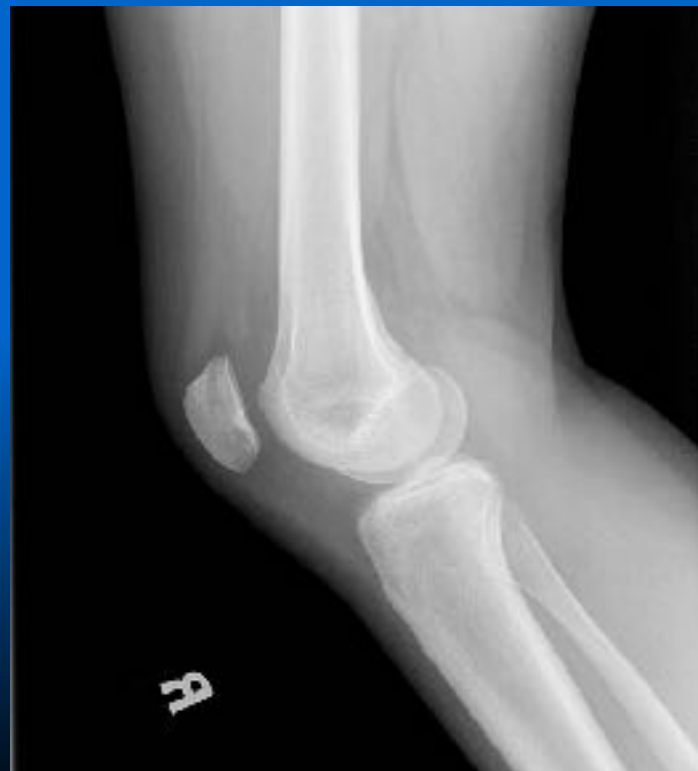
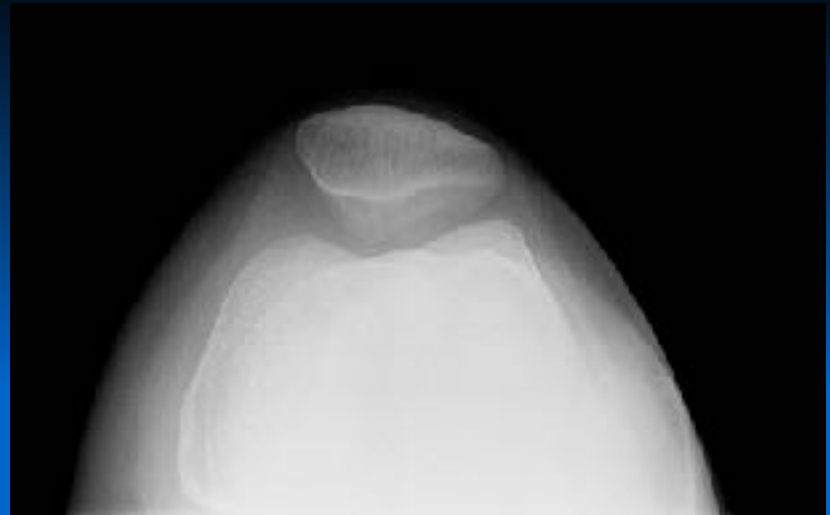
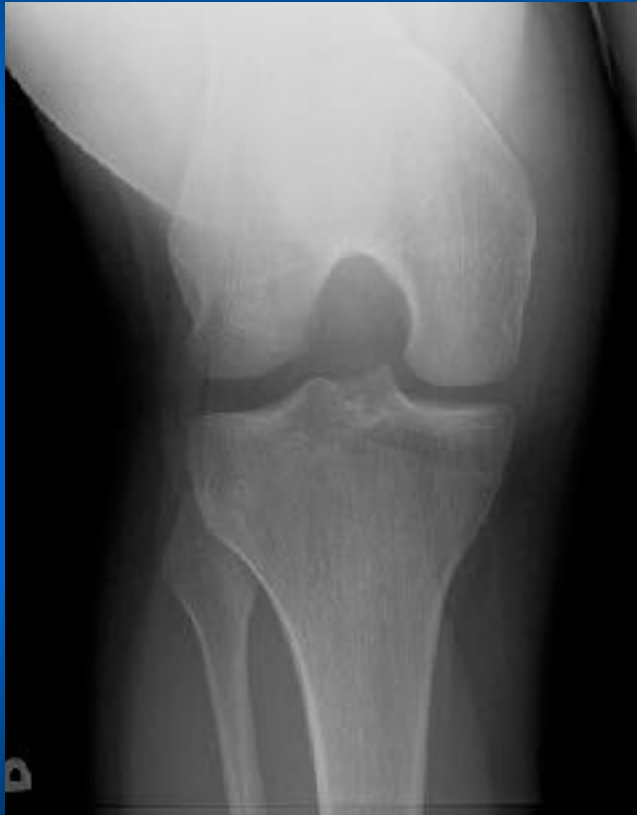## **17YO white female**

- Right knee: direct blow on the patella
- Landed flexed position ice skating
- Initial patellar dislocation two years ago playing lacrosse
- PE:
  - Moderate effusion
  - Positive apprehension test
  - Active range of motion 10-60°

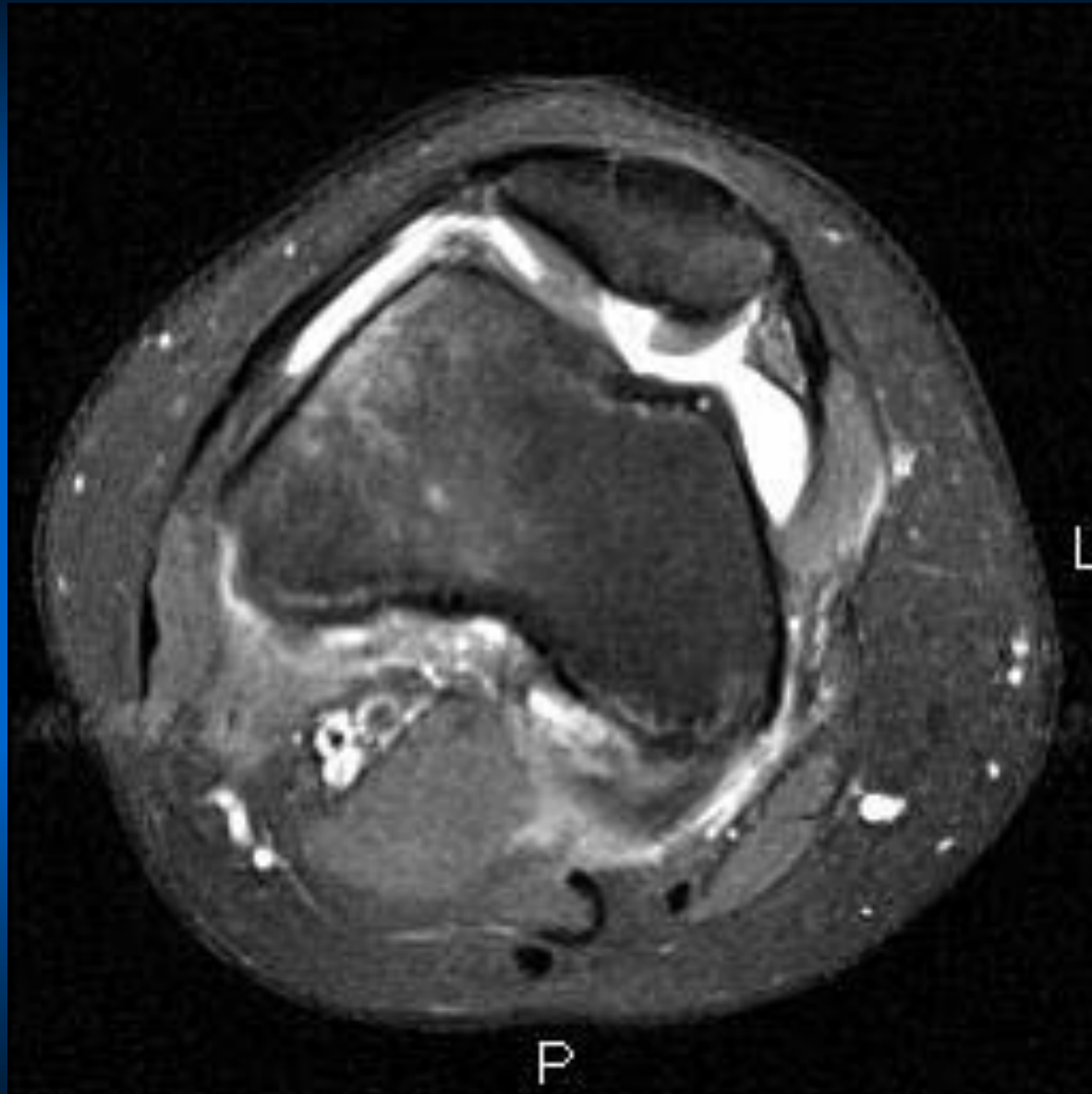
# Imaging Studies

## Plane x-rays

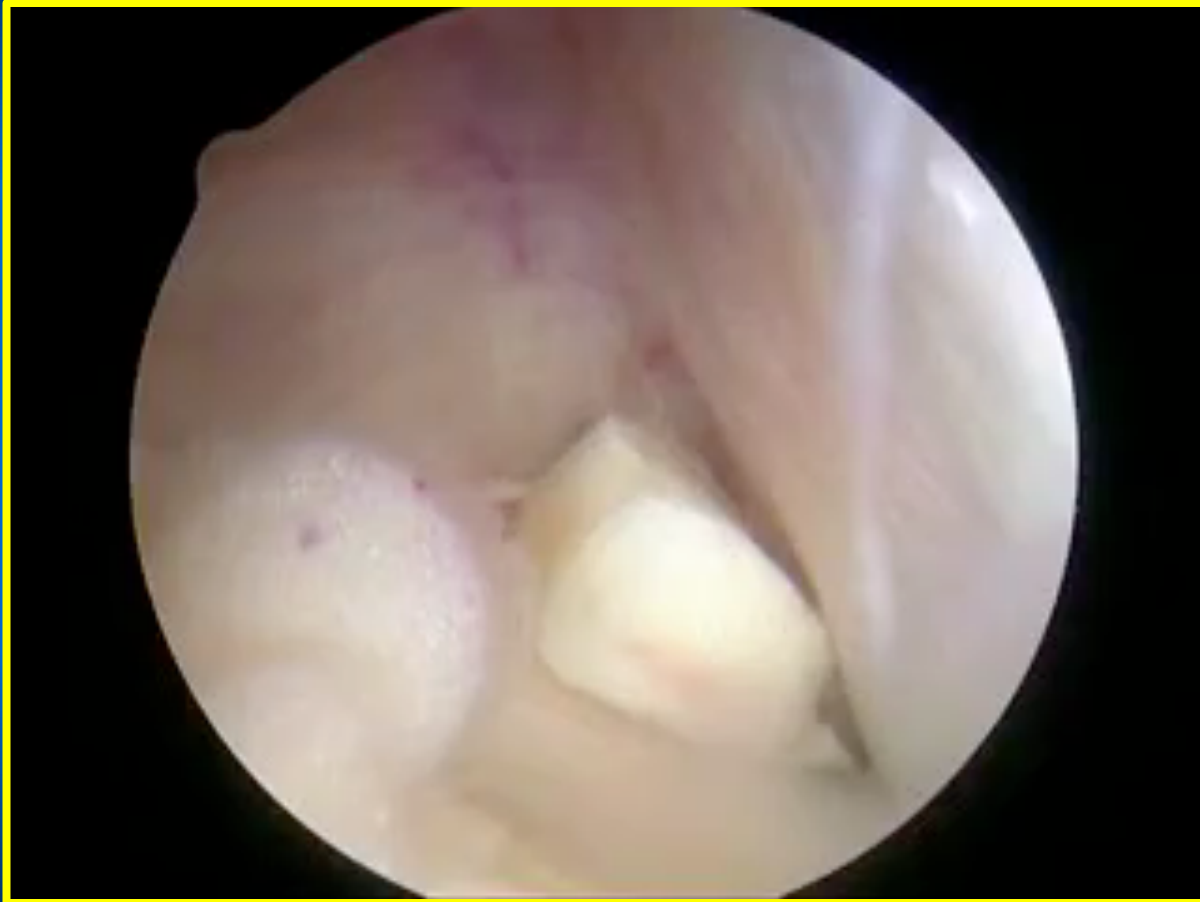



# MRI

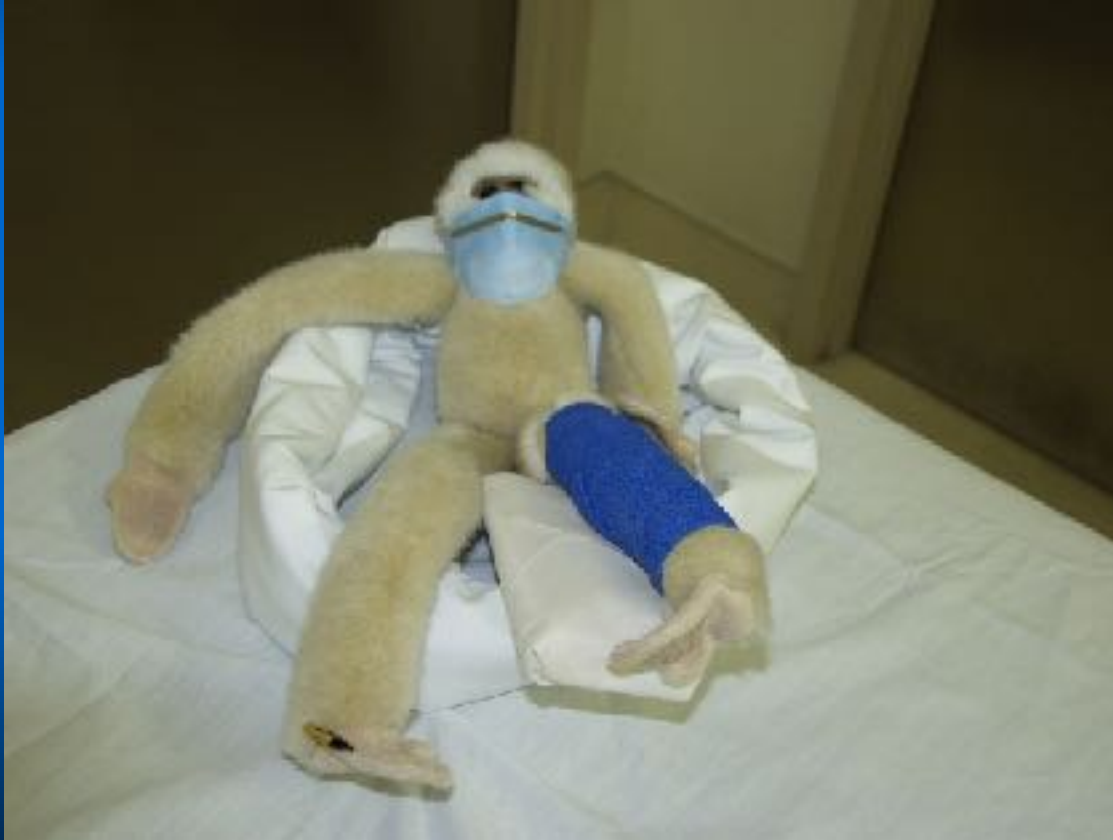

# Arthroscopy, Right Knee

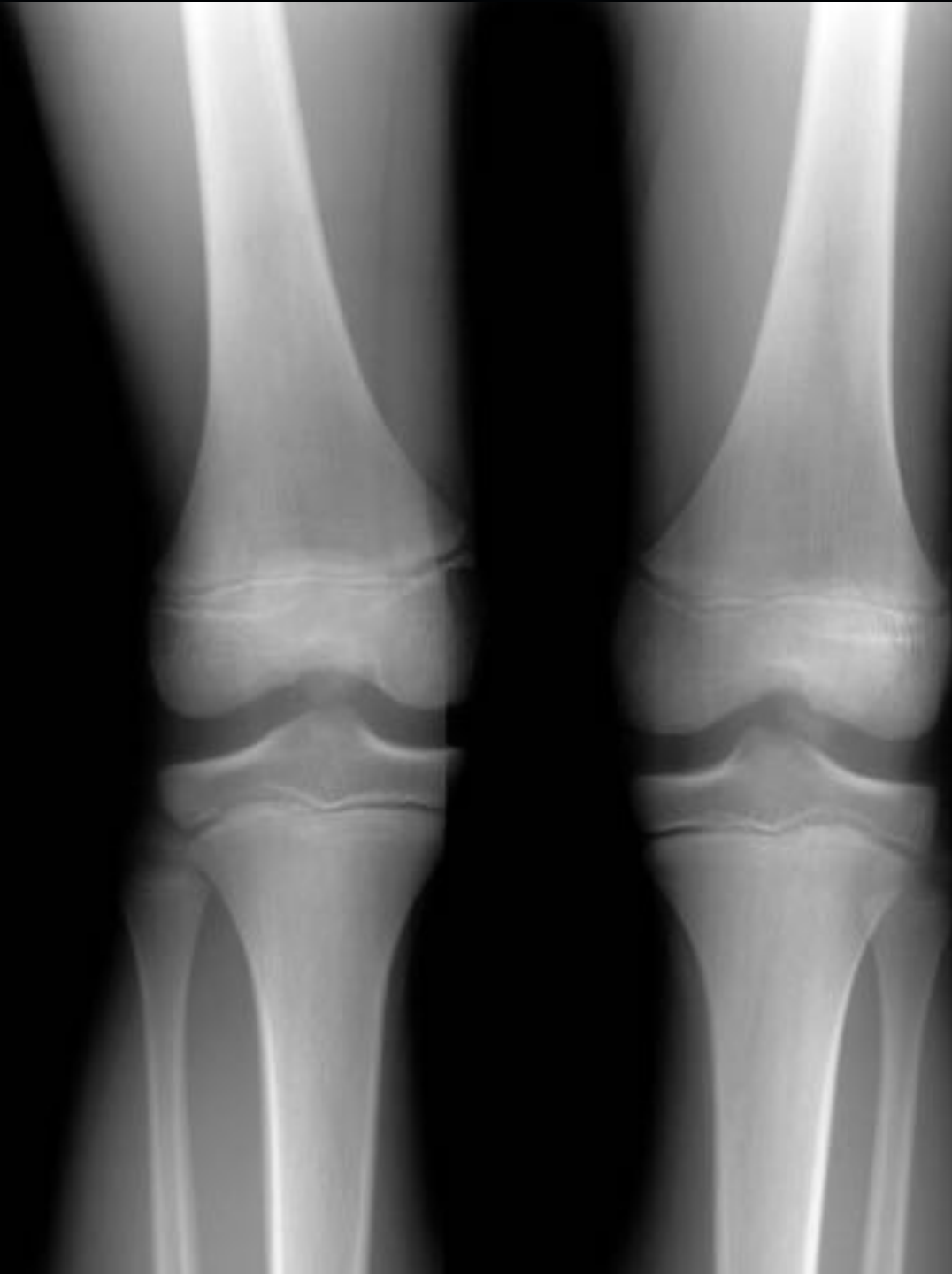


**10 YO Male**

**Injured Right knee doing kicks in martial arts**



**[Monkey had no name]**

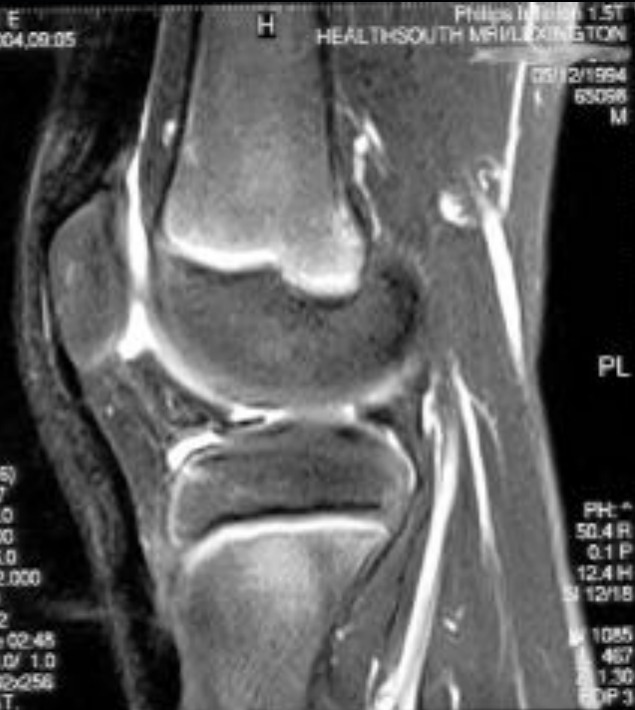



Sc 4083 E  
08/27/2004.09:05  
Right

Philips Infinix 1.5T  
HEALTHSOUTH MRI/LEXINGTON  
05/12/1994  
65098  
M

TSE, (16)  
TE 70.7  
BW 25.0  
TR 3500  
FOV 16.0  
RFOV 2.000  
Flip 90  
NSA 2  
ScTime 02:48  
THK 4.0/ 1.0  
RES 192x256  
FATSAT.

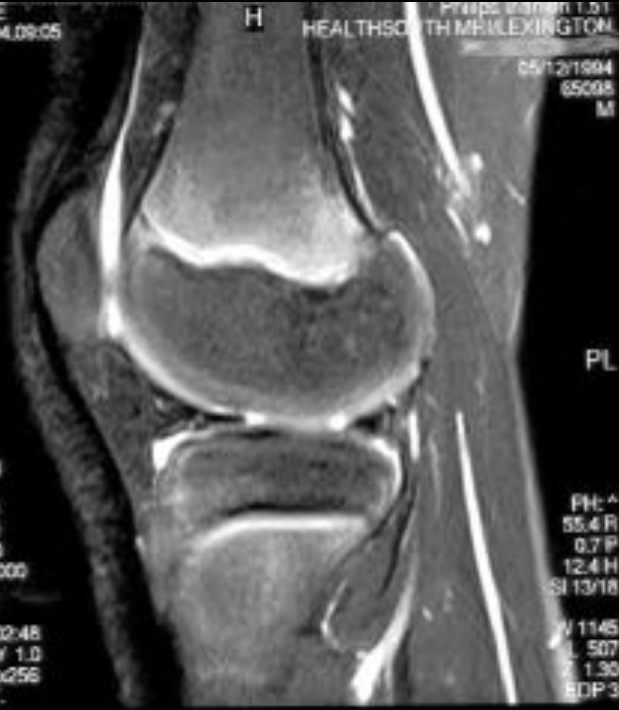

PL

TSE, (16)  
TE 70.7  
BW 25.0  
TR 3500  
FOV 16.0  
RFOV 2.000  
Flip 90  
NSA 2  
ScTime 02:48  
THK 4.0/ 1.0  
RES 192x256  
FATSAT.

Philips Infinix 1.5T  
HEALTHSOUTH MRI/LEXINGTON  
05/12/1994  
65098  
M

PH: 4  
55.4 R  
0.7 P  
12.4 H  
SI 13/18  
W 1145  
L 507  
Z 1.30  
EDP 3

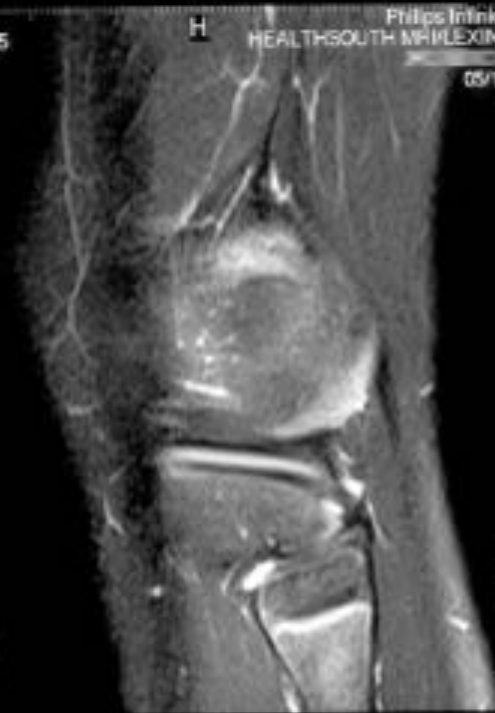

PL

Sc 4083 E  
08/27/2004.09:05  
Right

Philips Infinix 1.5T  
HEALTHSOUTH MRI/LEXINGTON  
05/12/1994  
65098  
M

TSE, (16)  
TE 70.7  
BW 25.0  
TR 3500  
FOV 16.0  
RFOV 2.000  
Flip 90  
NSA 2  
ScTime 02:48  
THK 4.0/ 1.0  
RES 192x256  
FATSAT.

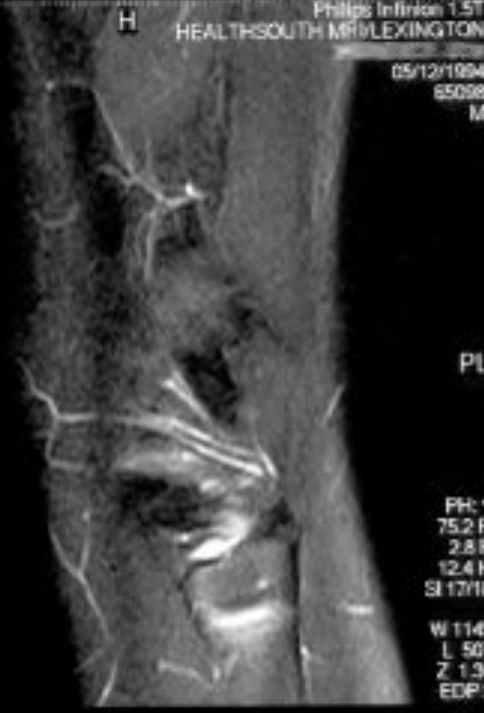

PL

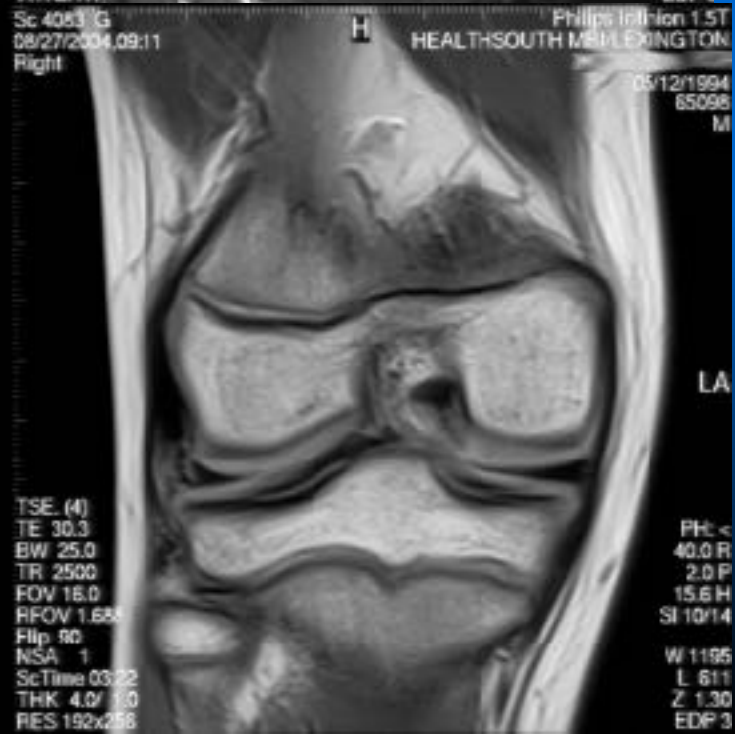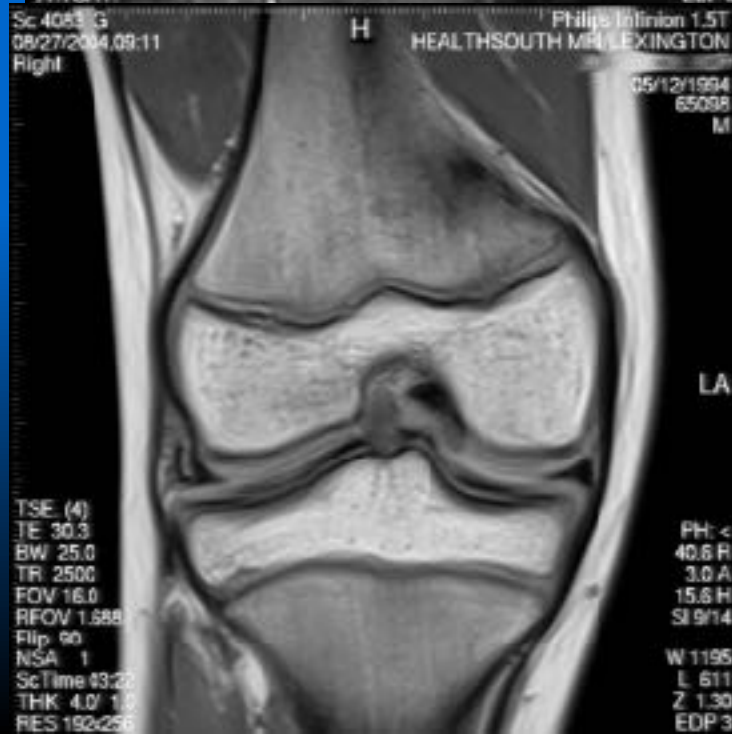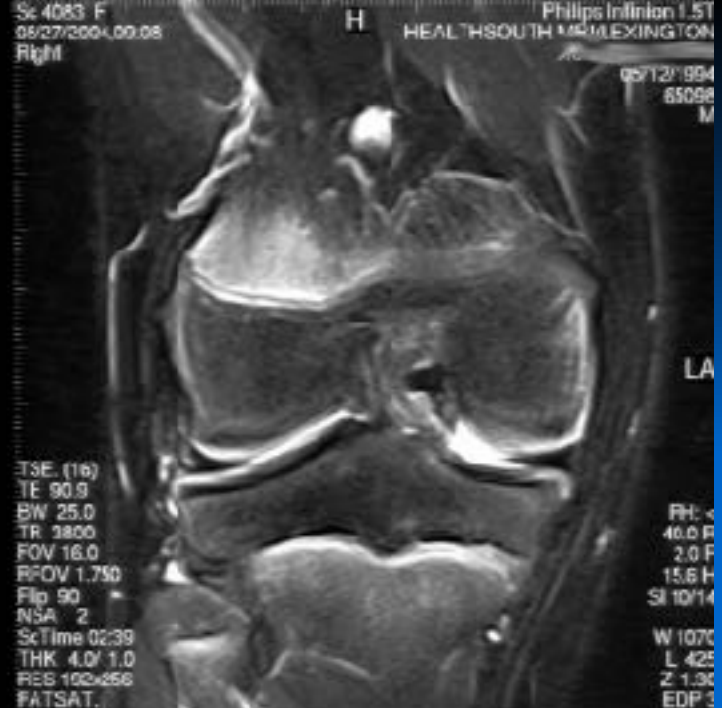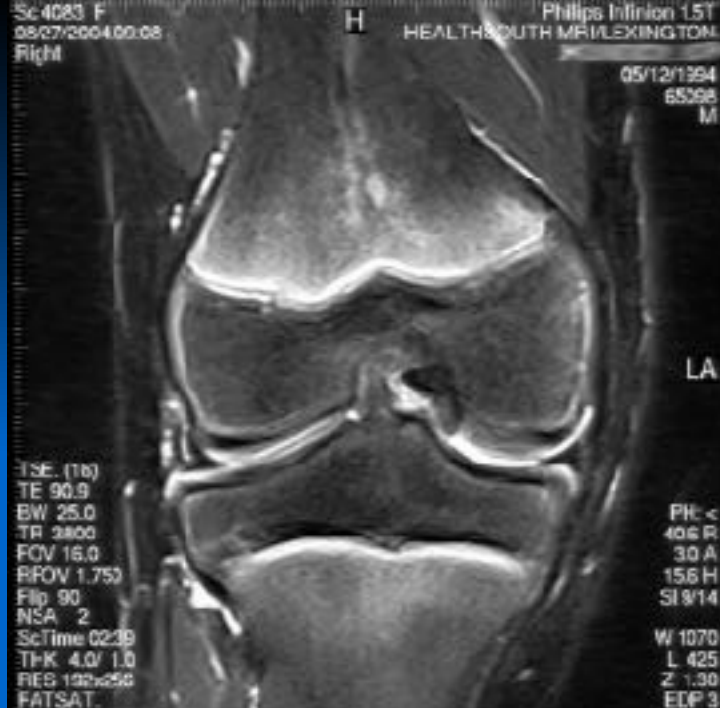TSE, (16)  
TE 70.7  
BW 25.0  
TR 3500  
FOV 16.0  
RFOV 2.000  
Flip 90  
NSA 2  
ScTime 02:48  
THK 4.0/ 1.0  
RES 192x256  
FATSAT.

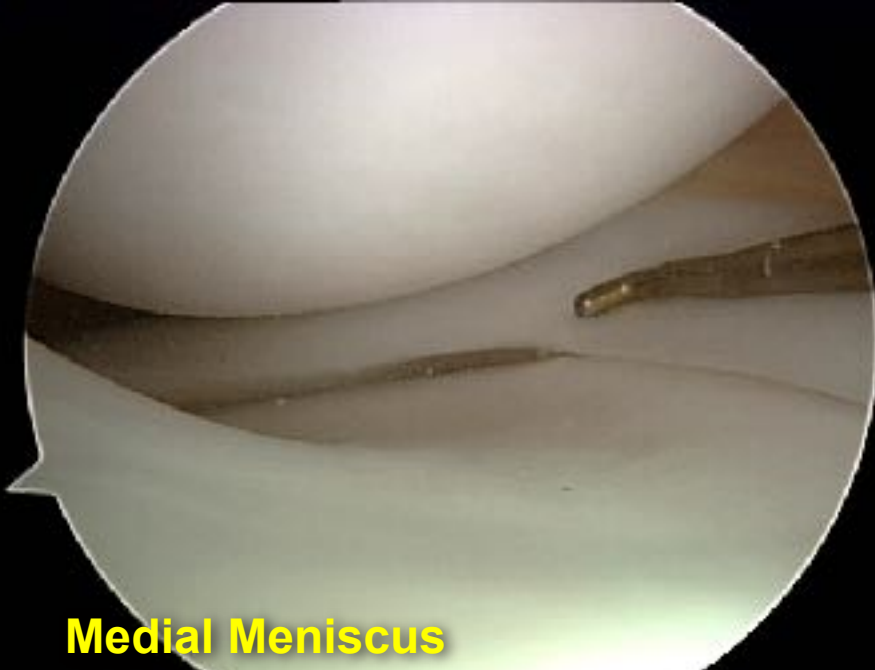
Philips Infinix 1.5T  
HEALTHSOUTH MRI/LEXINGTON  
05/12/1994  
65098  
M

PH: 4  
75.2 F  
2.8 F  
12.4 H  
SI 17/18  
W 1145  
L 507  
Z 1.30  
EDP 3

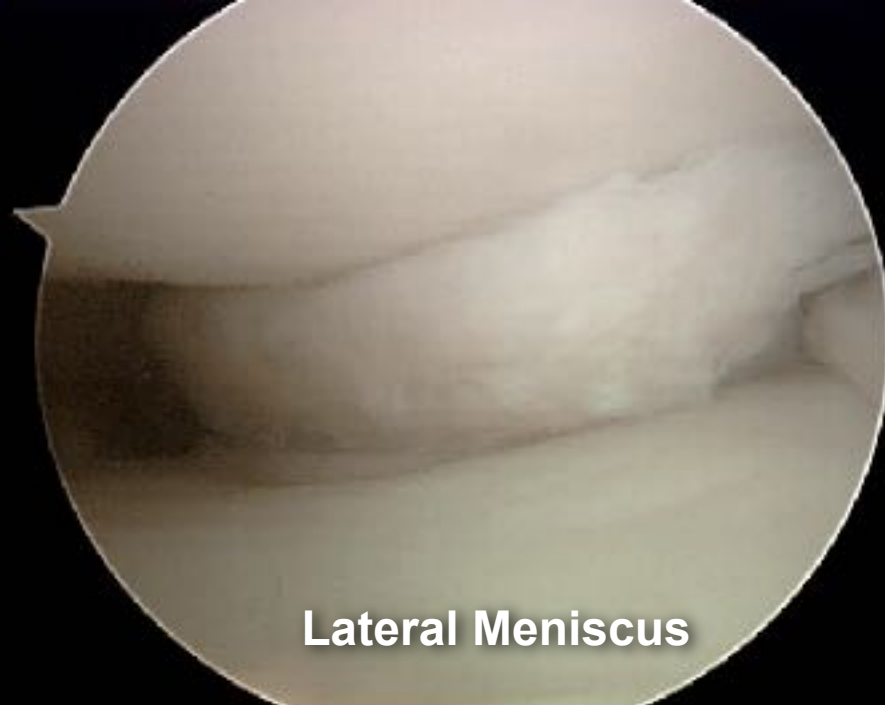


PL

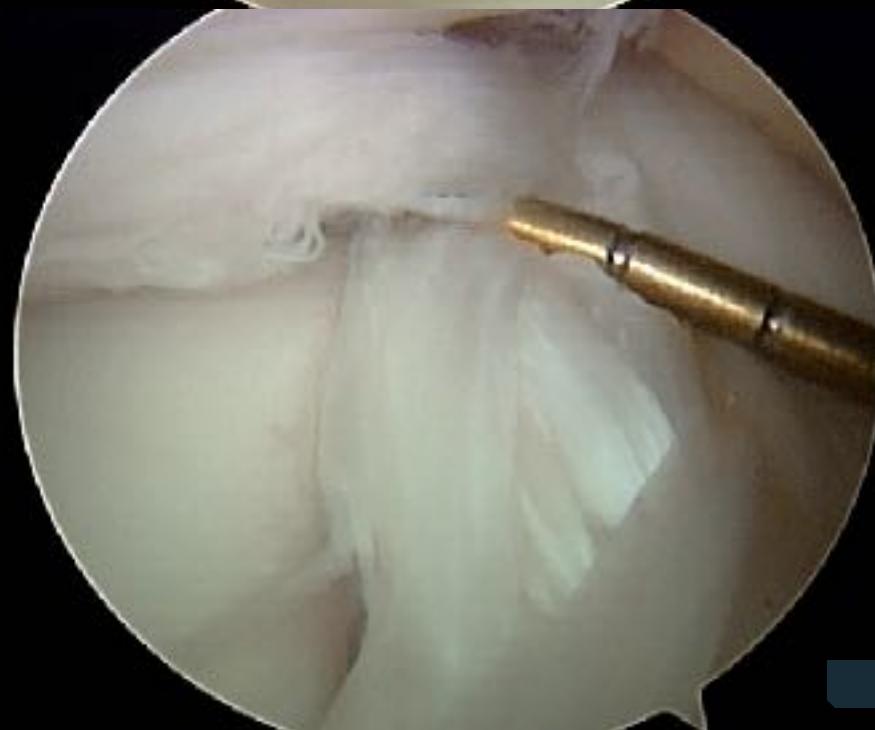
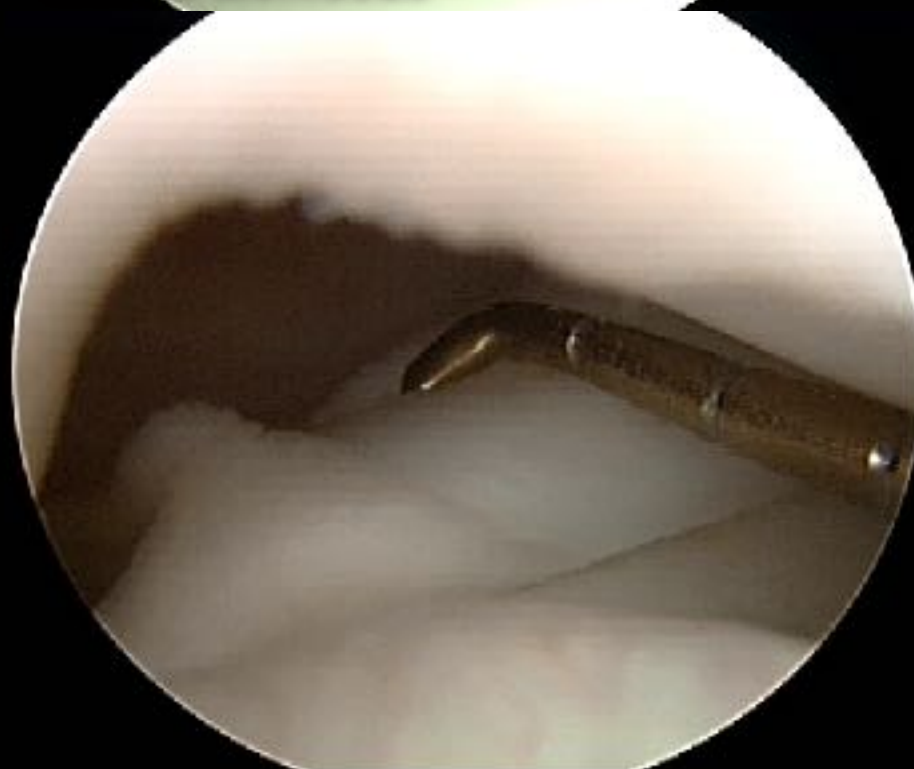



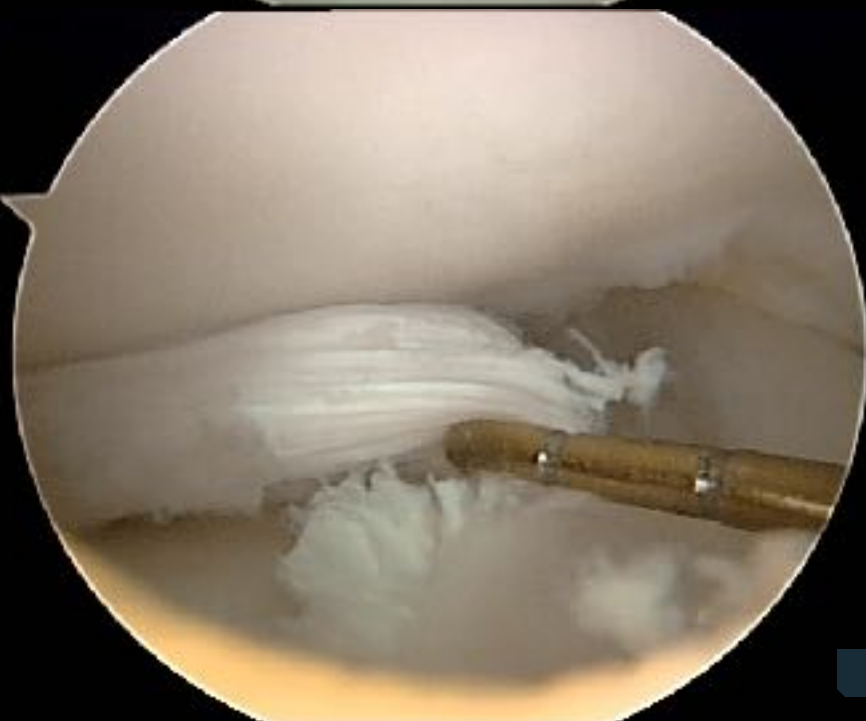
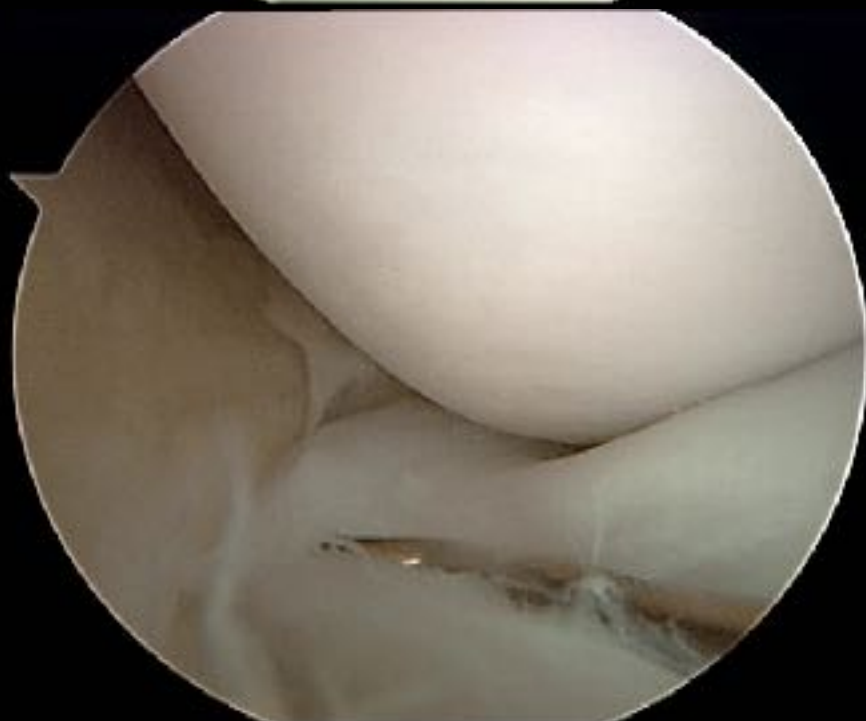
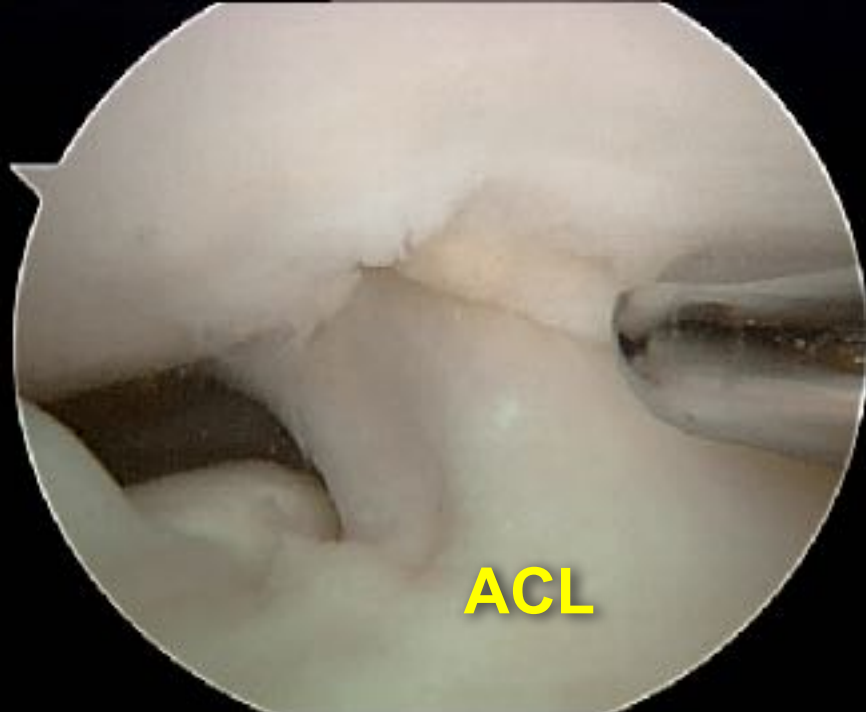
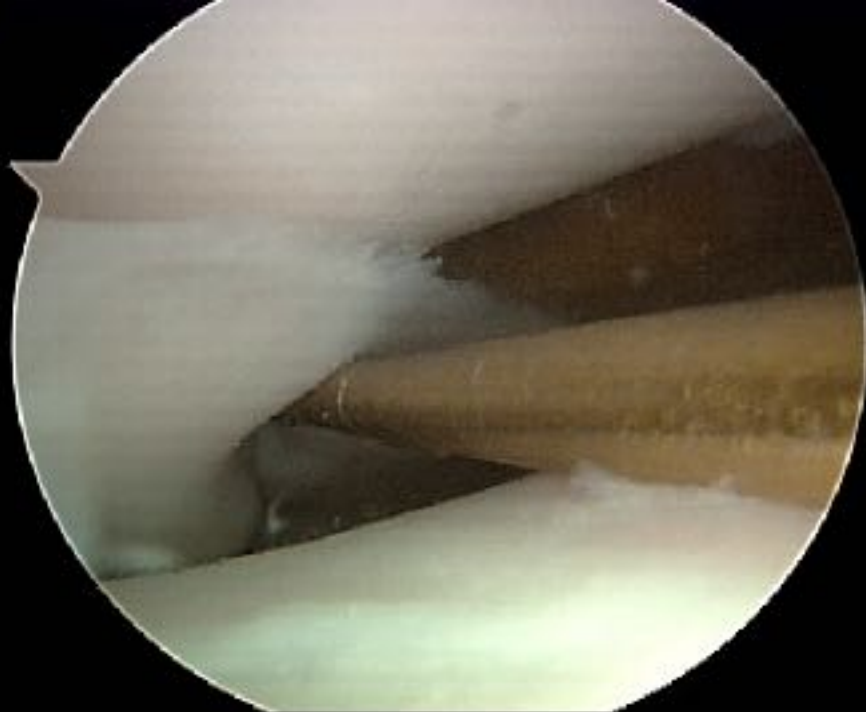
**Medial Meniscus**



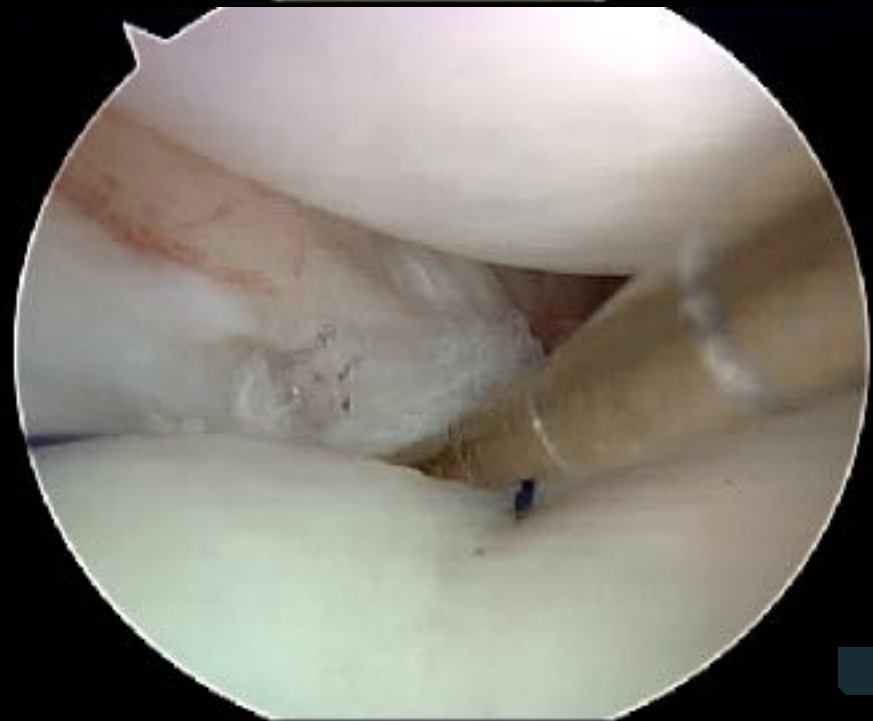
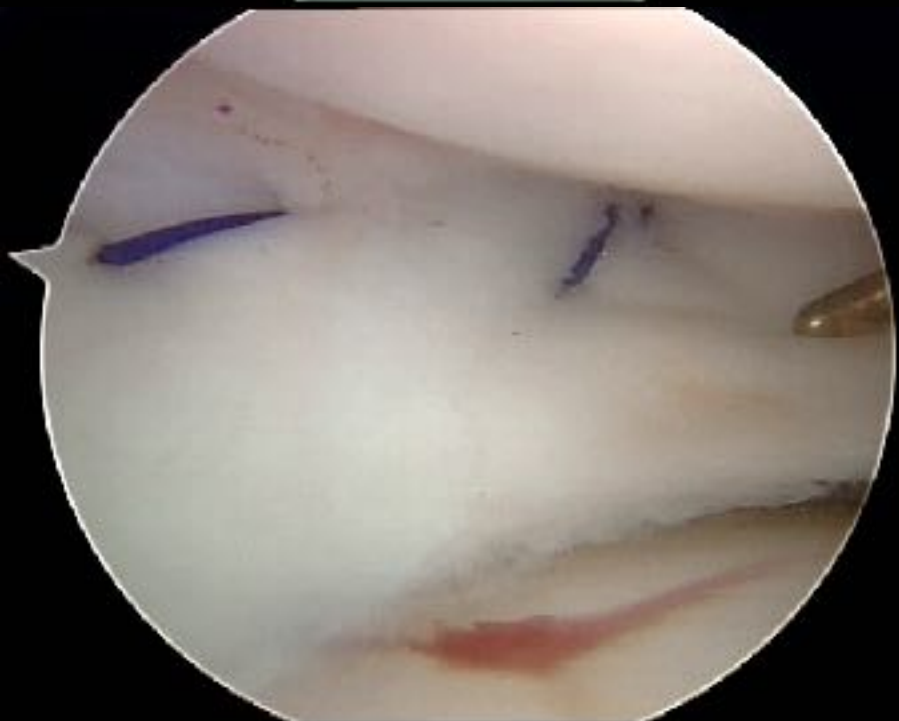
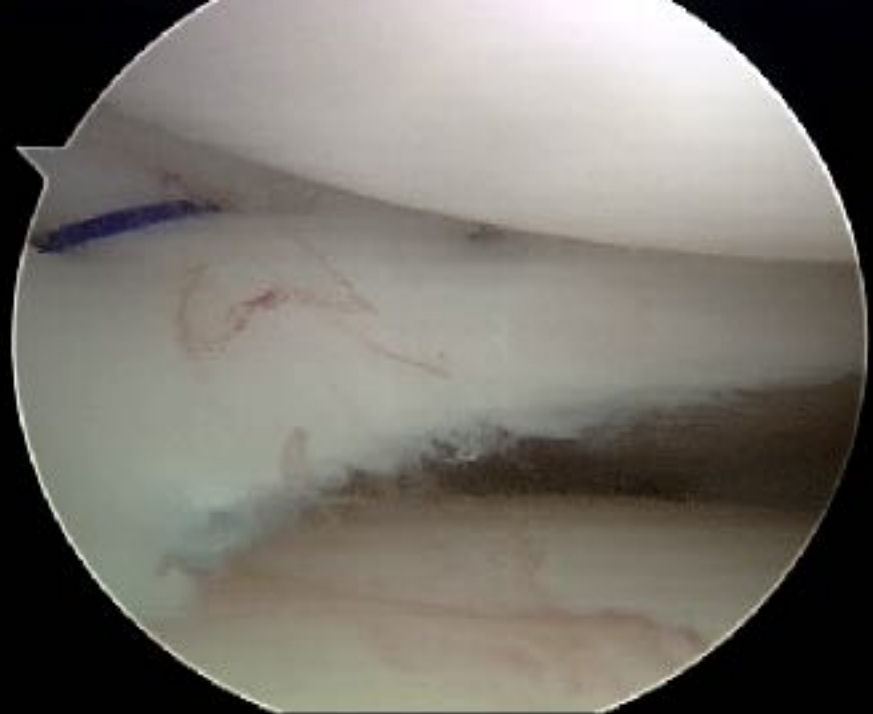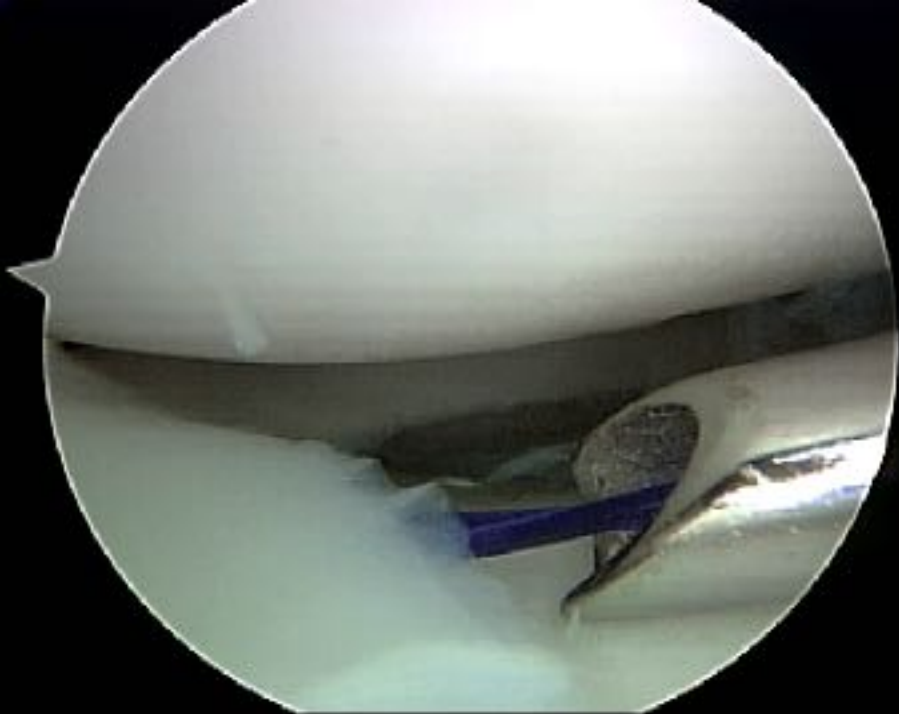
**Lateral Meniscus**



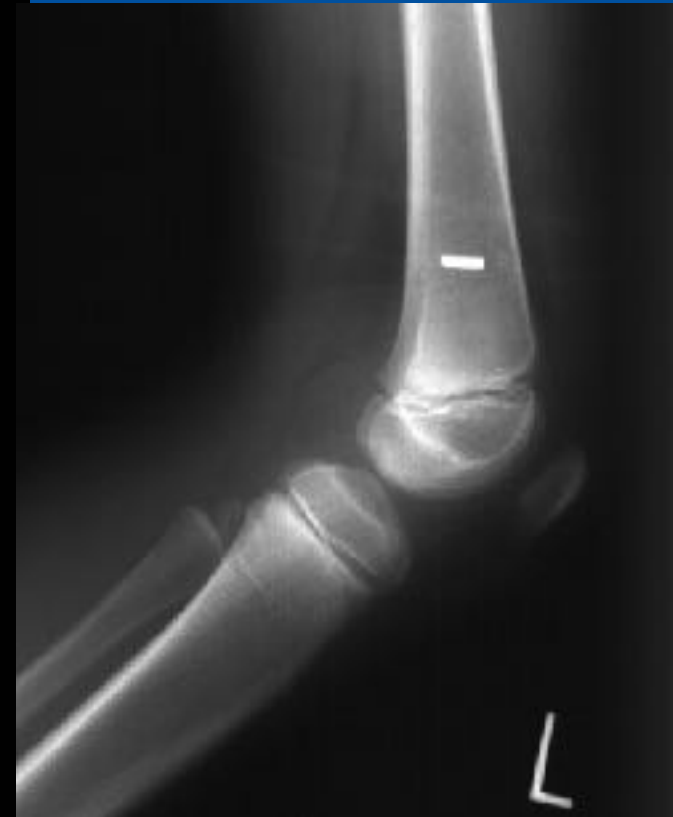
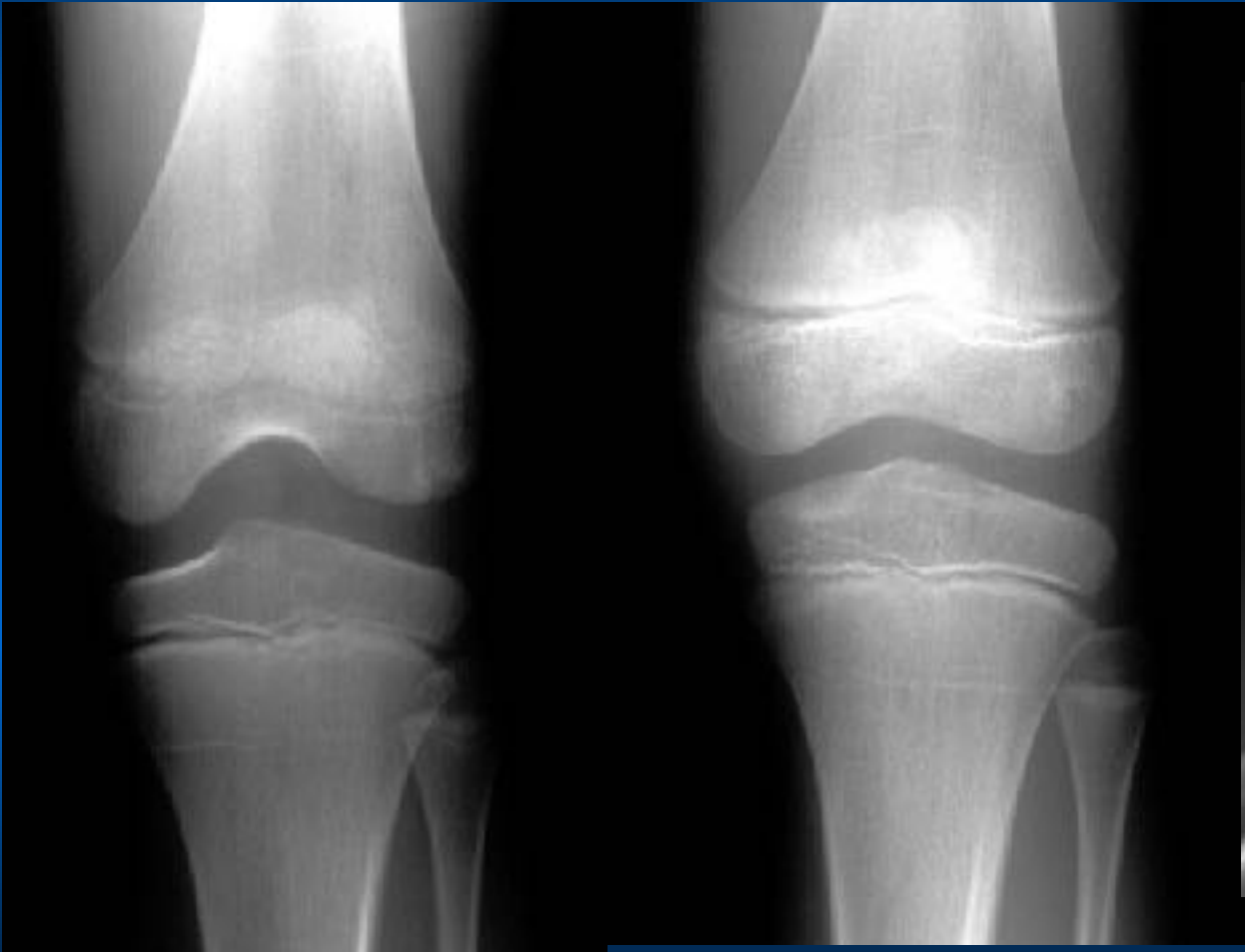


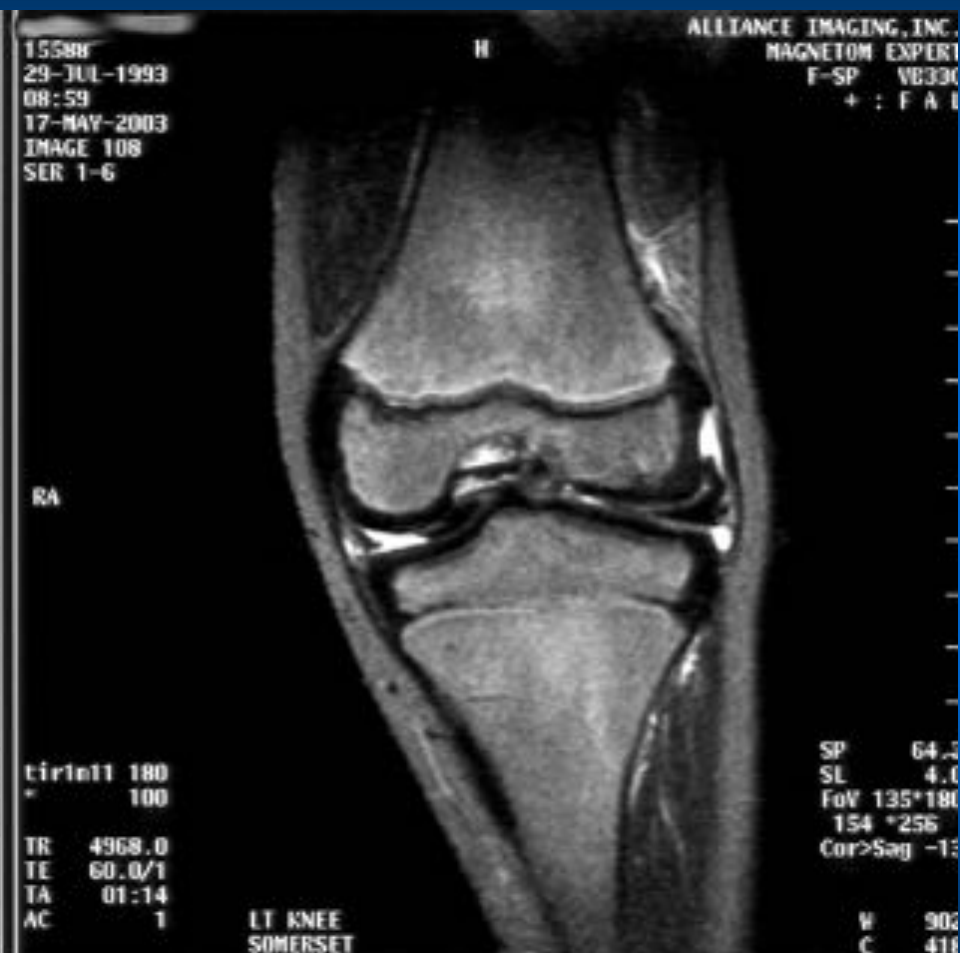
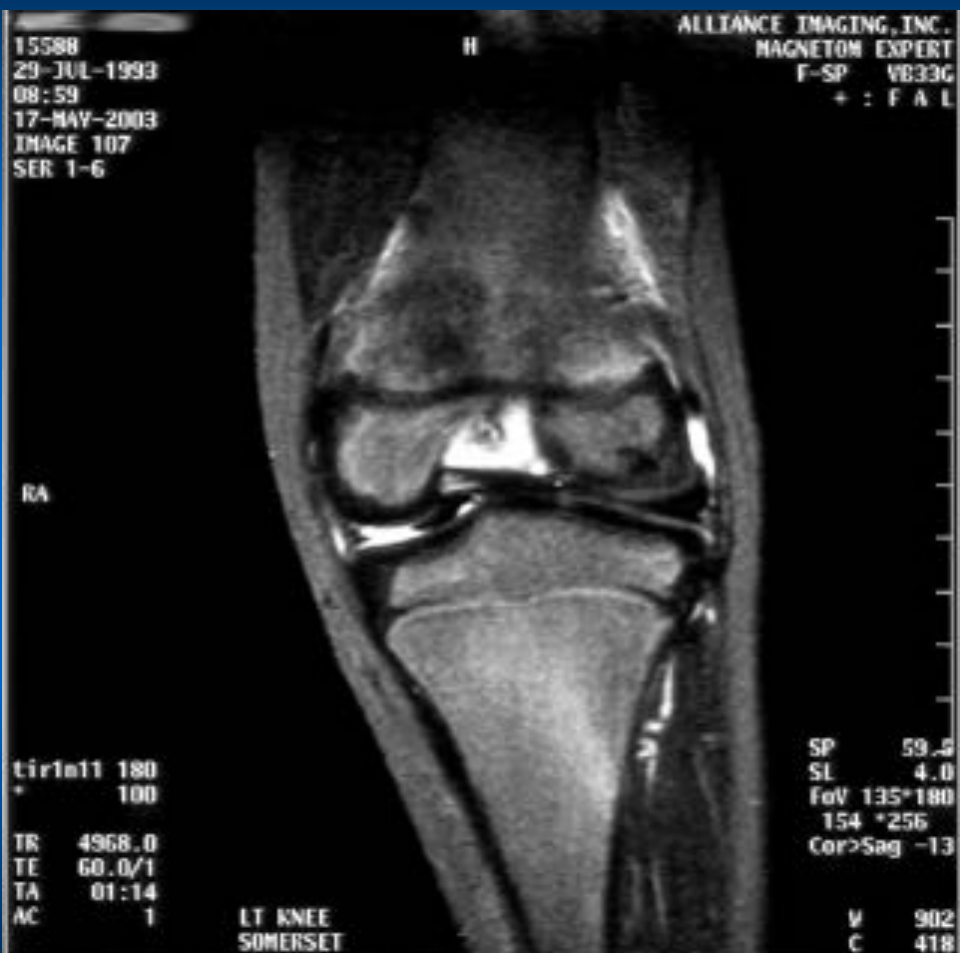


## 9.9 YO Male injured left knee playing soccer





09:00  
17-MAY-2003  
IMAGE 125  
SER 1-7

RA

FI2d 30  
\*R  
TR 576.0  
TE 18.8/1  
TA 01:24  
AC 1

LT KNEE  
SOMERSET

ALLIANCE IMAGING, INC.  
MAGNETOM EXPERT  
F-SF V6336  
+ : F A L

SP 59.4  
SL 4.0  
FOV 135\*180  
142 \*2560  
Cor>Sag 13

M 858  
C 341

17-MAY-2003  
IMAGE 126  
SER 1-7

RA

FI2d 30  
\*R  
TR 576.0  
TE 18.8/1  
TA 01:24  
AC 1

LT KNEE  
SOMERSET

ALLIANCE IMAGING, INC.  
MAGNETOM EXPERT  
F-SF V6336  
+ : F A L

SP 64.4  
SL 4.0  
FOV 135\*180  
142 \*2560  
Cor>Sag -13

M 858  
C 341

15:00  
23-JUL-1993  
09:00  
17-MAY-2003  
IMAGE 127  
SER 1-7

RA

FI2d 30  
\*R  
TR 576.0  
TE 18.8/1  
TA 01:24  
AC 1

LT KNEE  
SOMERSET

ALLIANCE IMAGING, INC.  
MAGNETOM EXPERT  
F-SF V6336  
+ : F A L

SP 65.4  
SL 4.0  
FOV 135\*180  
142 \*2560  
Cor>Sag -13

M 858  
C 341

15:00  
23-JUL-1993  
09:00  
17-MAY-2003  
IMAGE 128  
SER 1-7

RA

FI2d 30  
\*R  
TR 576.0  
TE 18.8/1  
TA 01:24  
AC 1

LT KNEE  
SOMERSET

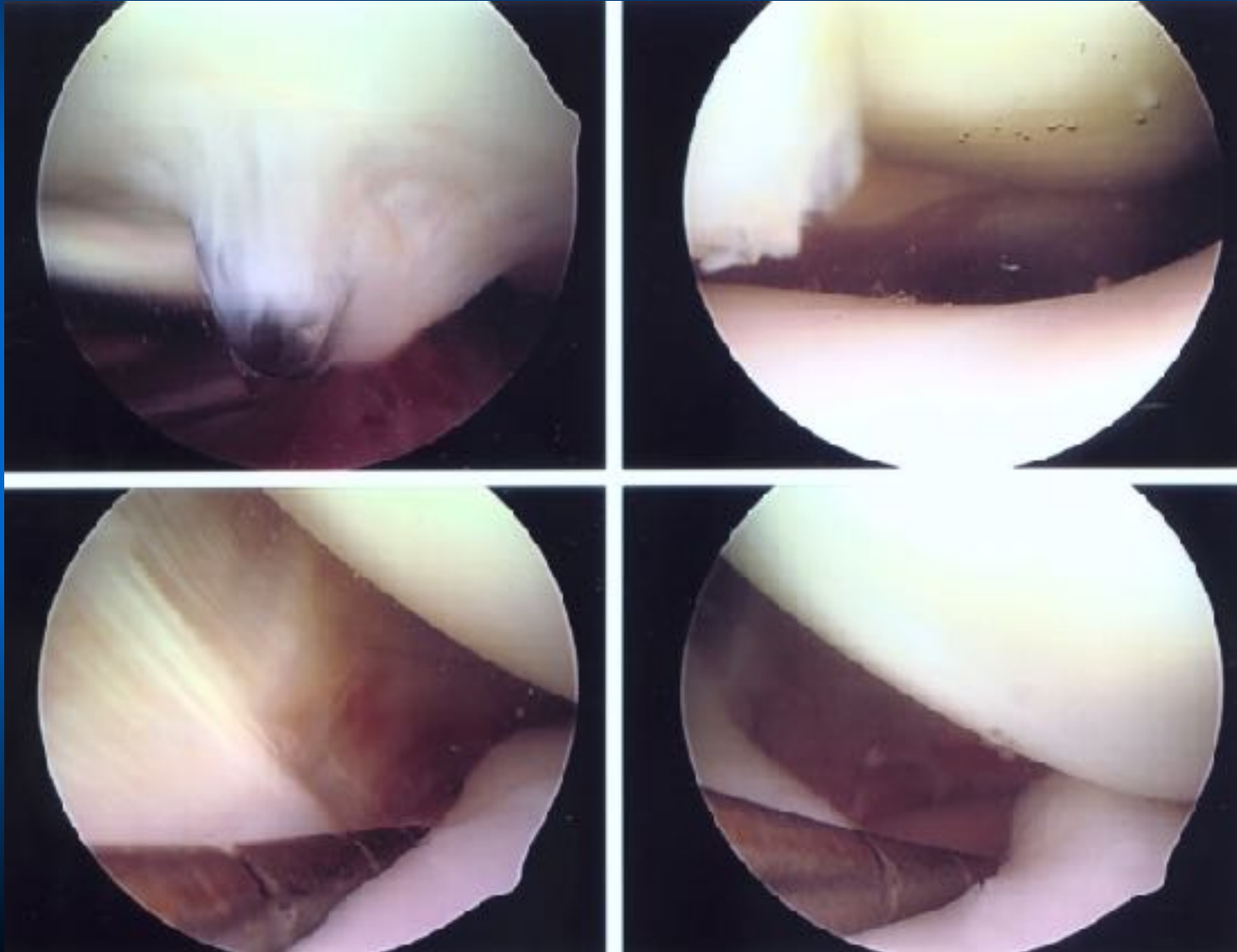
ALLIANCE IMAGING, INC.  
MAGNETOM EXPERT  
F-SF V6336  
+ : F A L

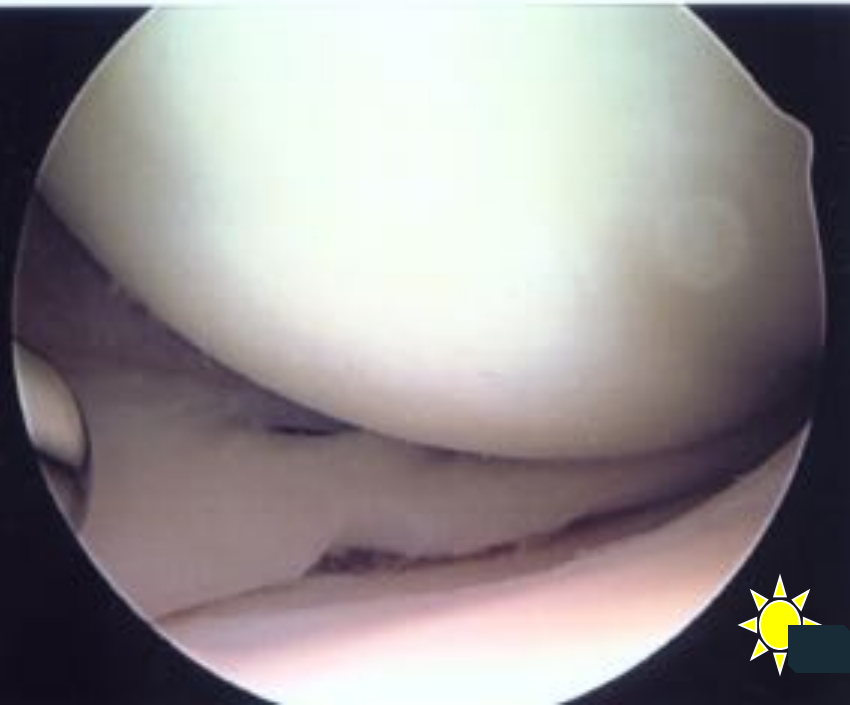
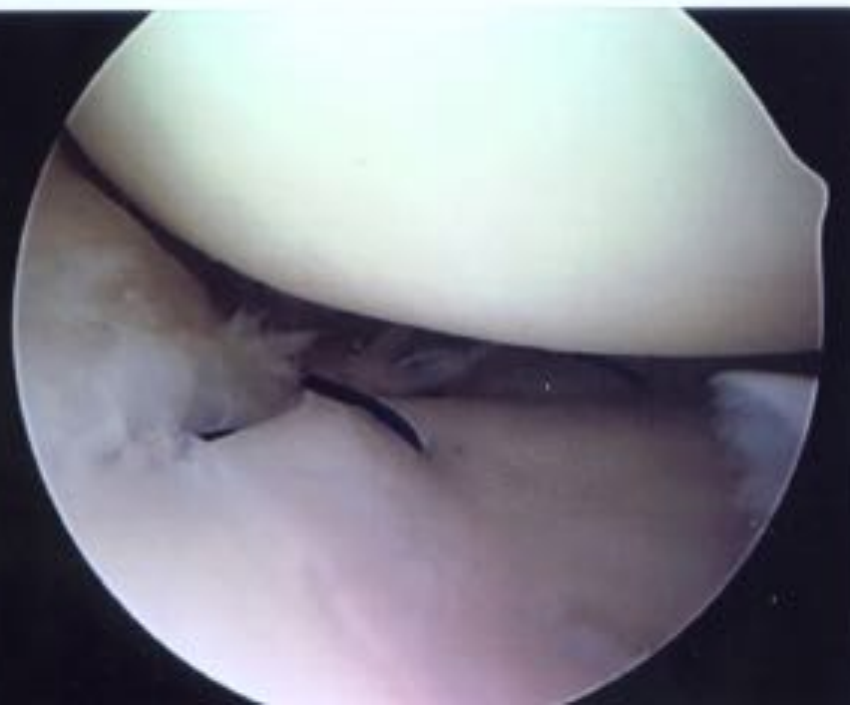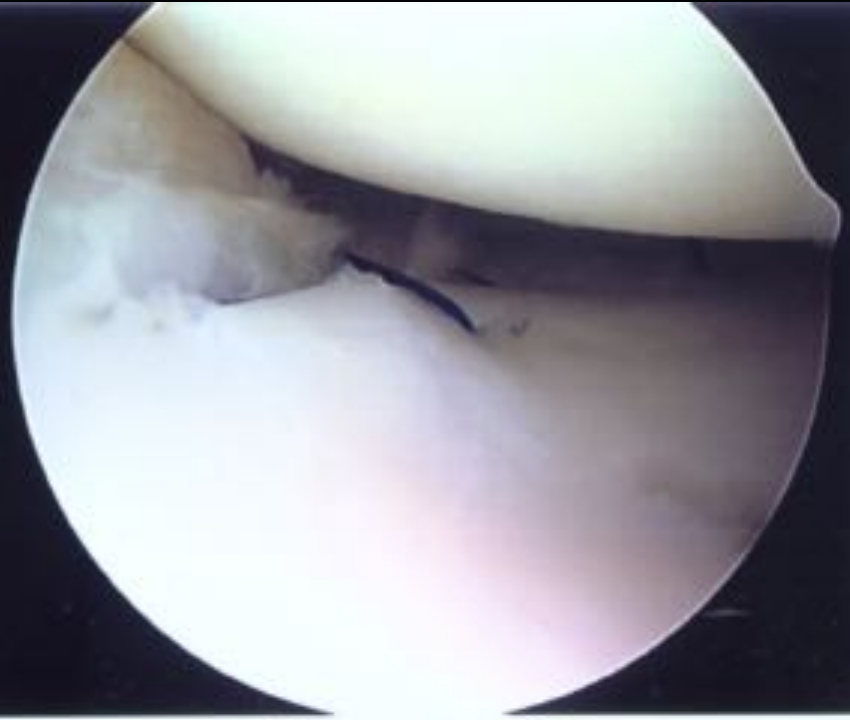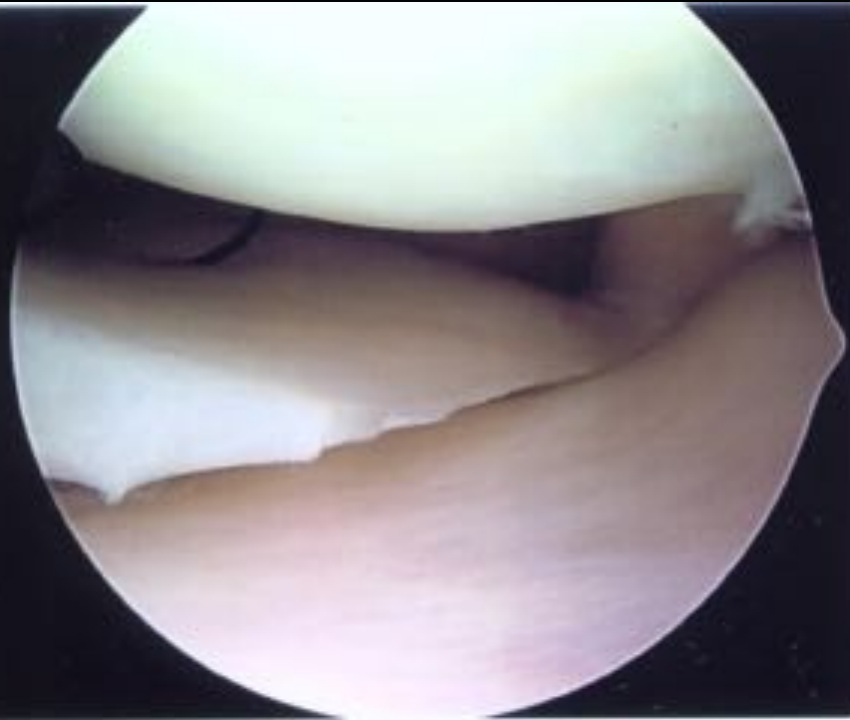SP 73.4  
SL 4.0  
FOV 135\*180  
142 \*2560  
Cor>Sag -13

M 858  
C 341

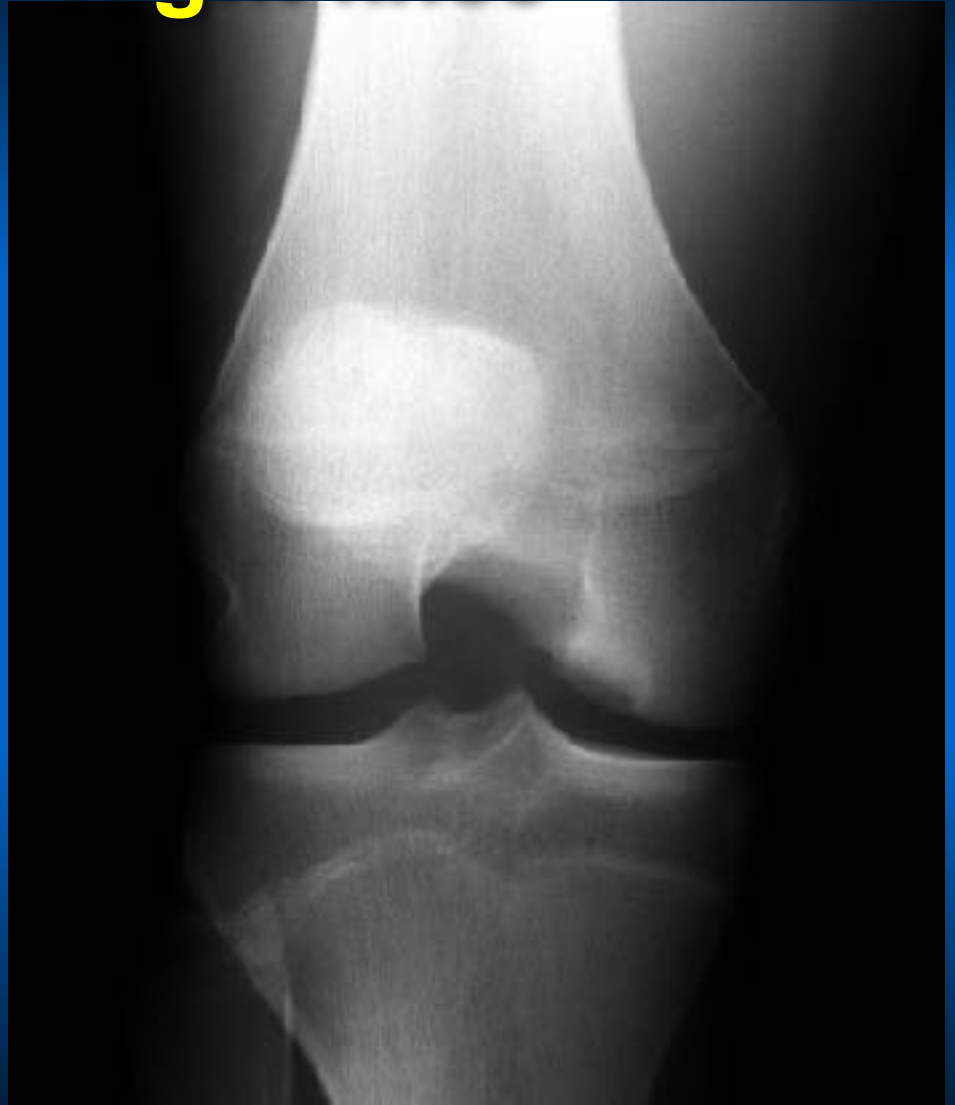
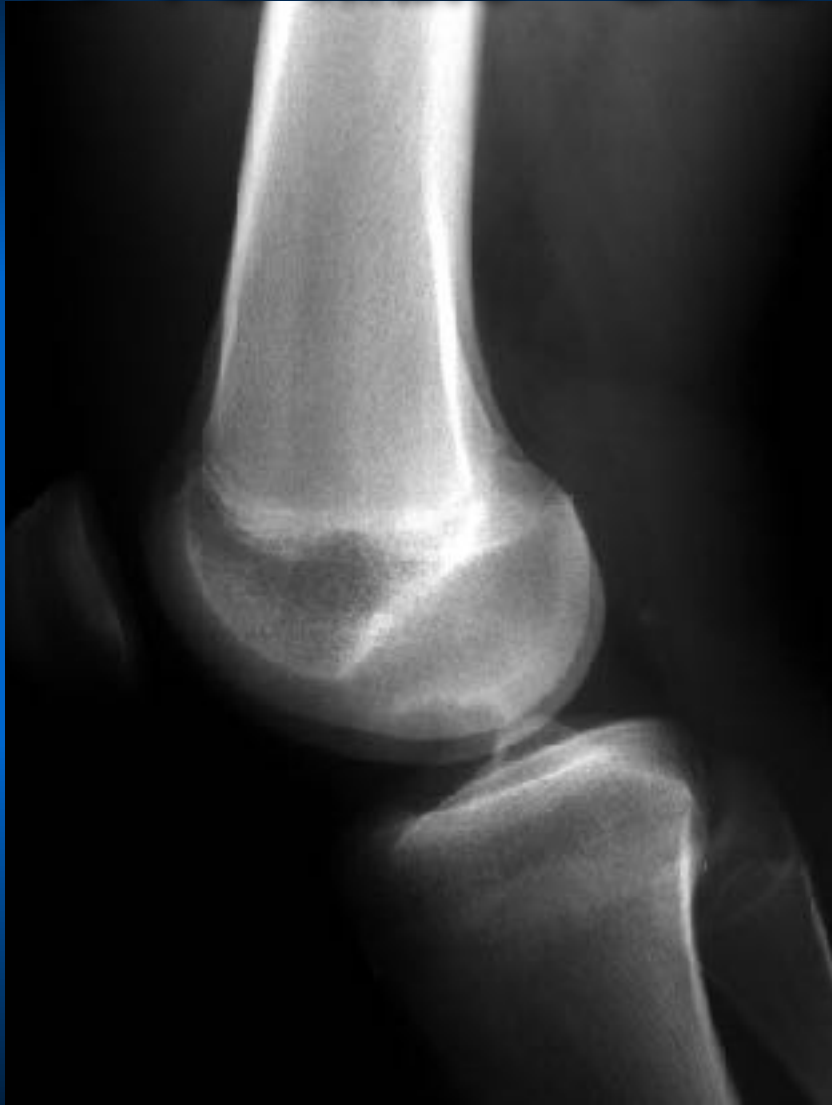
**Medial meniscus repair, left knee (acute posterior horn MMT), w/ PDS x7**





# 16 YO Male - OCD - Right knee



1.5T SYS\*LCR00MR

S 56

Lake Cumberland Regional

0116 280579

Nov 02 2004

12:20:12 PM

Mag = 1.0

FL:

ROT:

3.9

15.0kHz

E

16

1.0sp

14

2/2 HDI

P

T 102

R - 2364 L - 1175

Signa 1.5T SYS\*LCR00MR

S 56

Lake Cumberland Regional

0116 280579

Nov 02 2004

12:20:12 PM

Mag = 1.0

FL:

ROT:

L  
R

RT  
↓

SE

TR:600

TE:14

EC:1/1 15.0kHz

QUADRICE

FUV:16x16

4.0mm/1.0sp

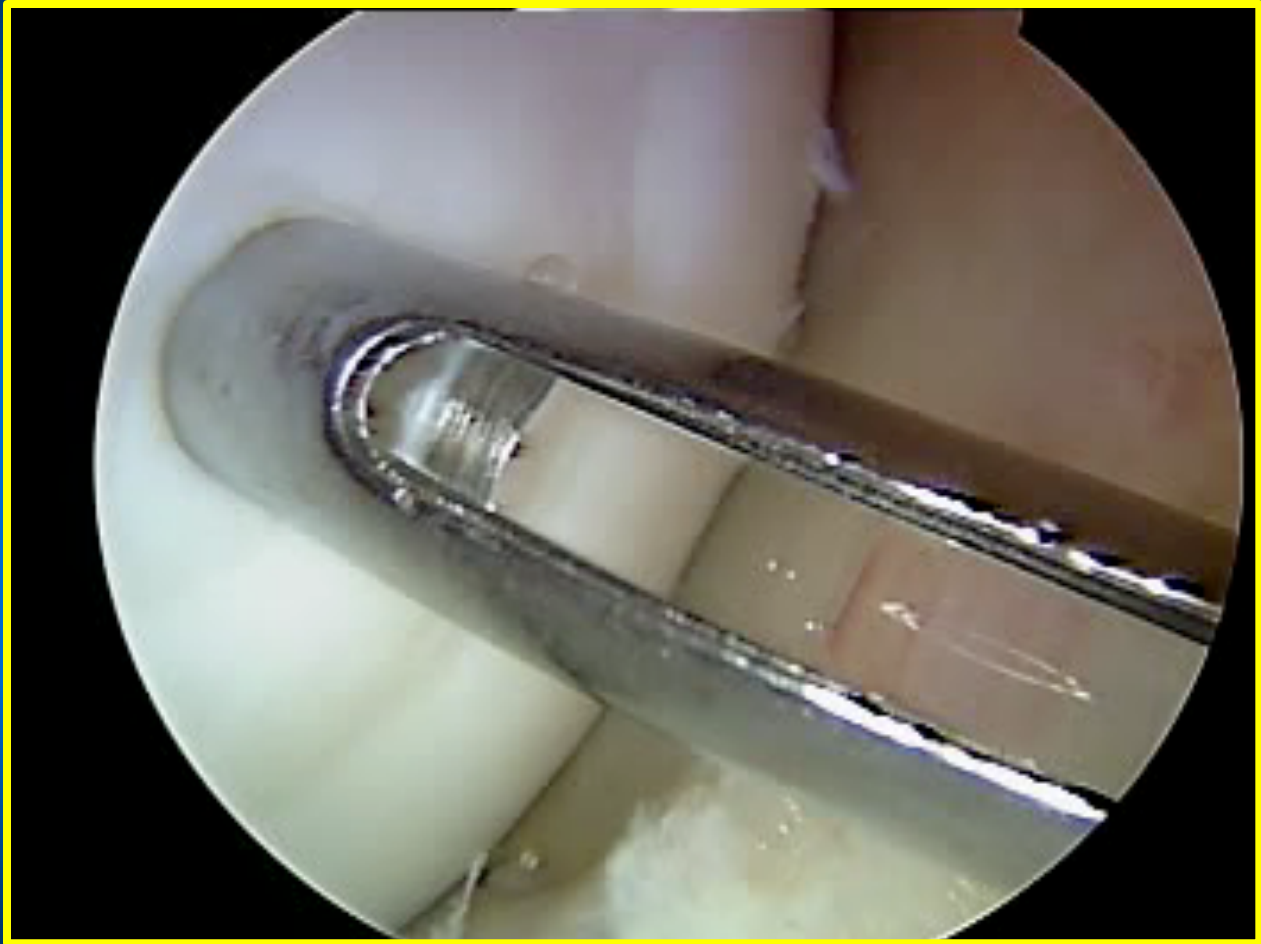20/03:54

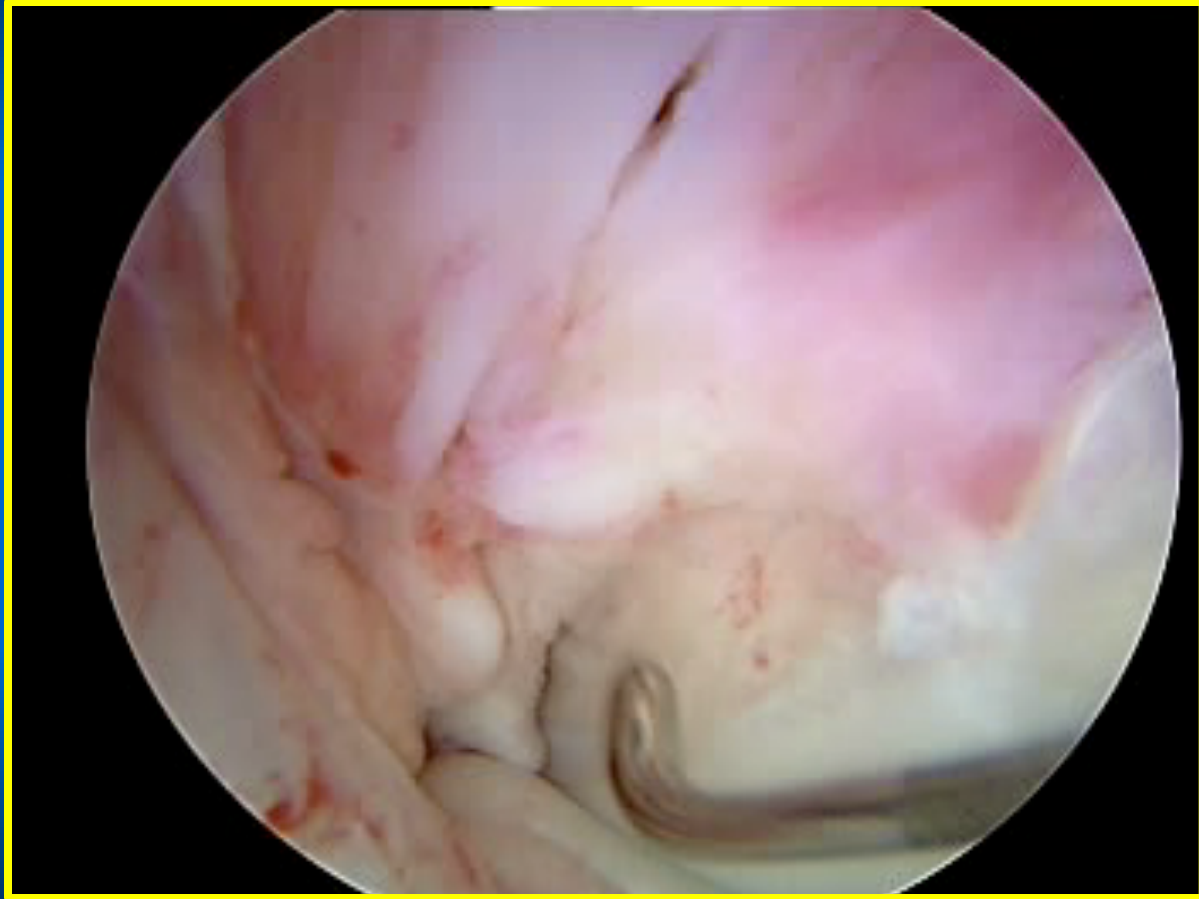
256x192/2 HFX

5+CT:00

T 102

R - 2364 L - 1175

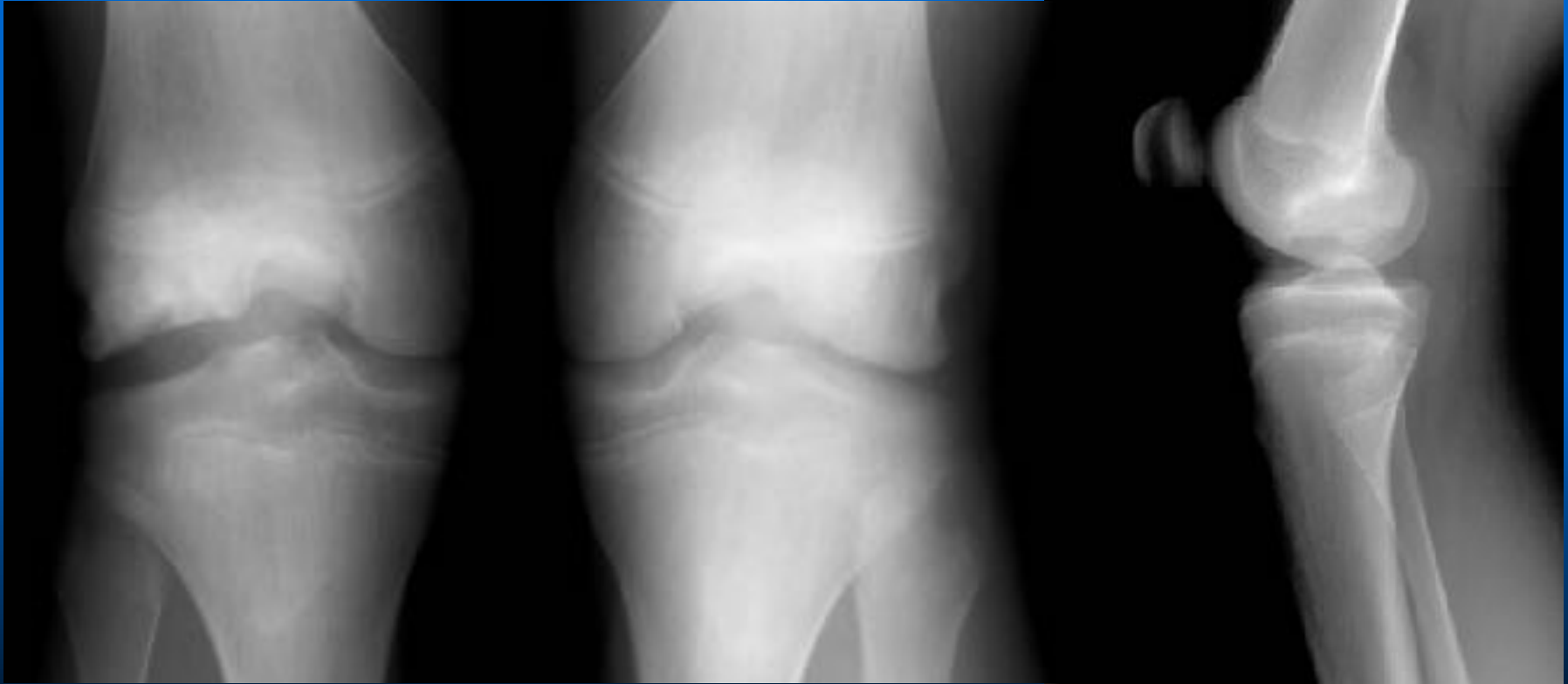


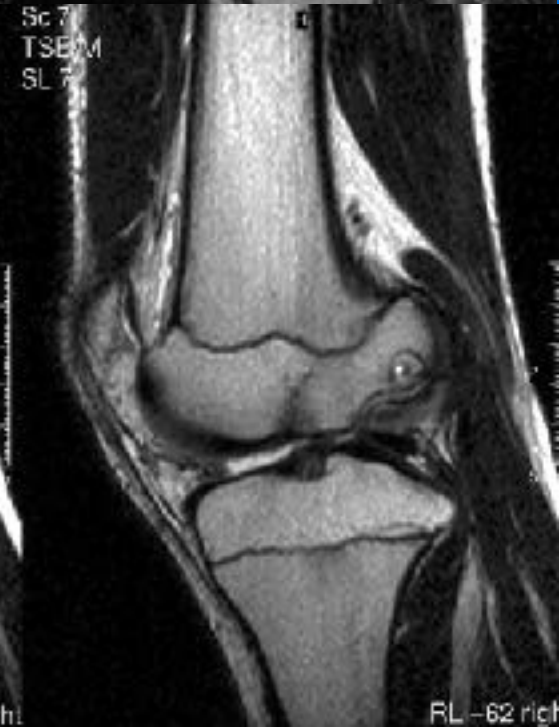
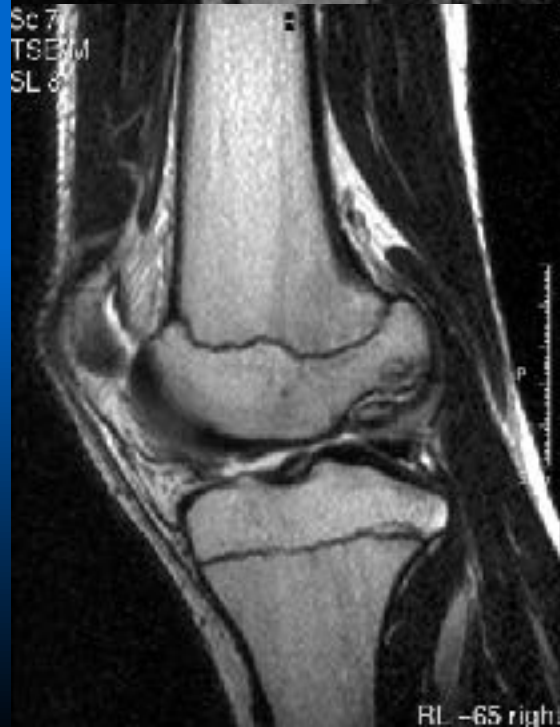
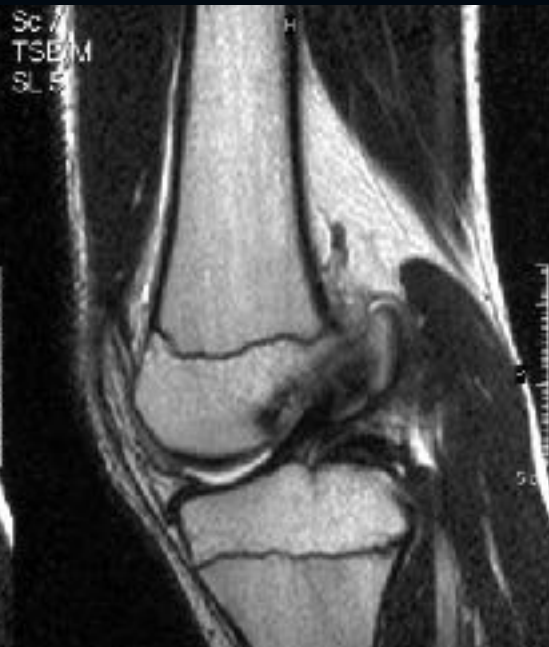
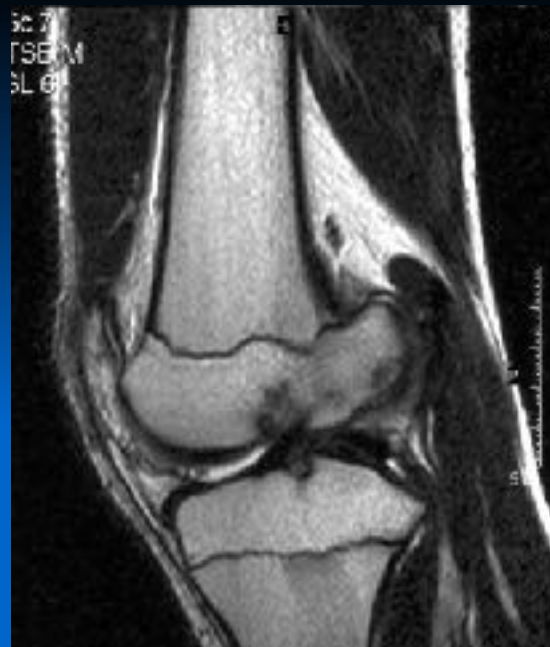
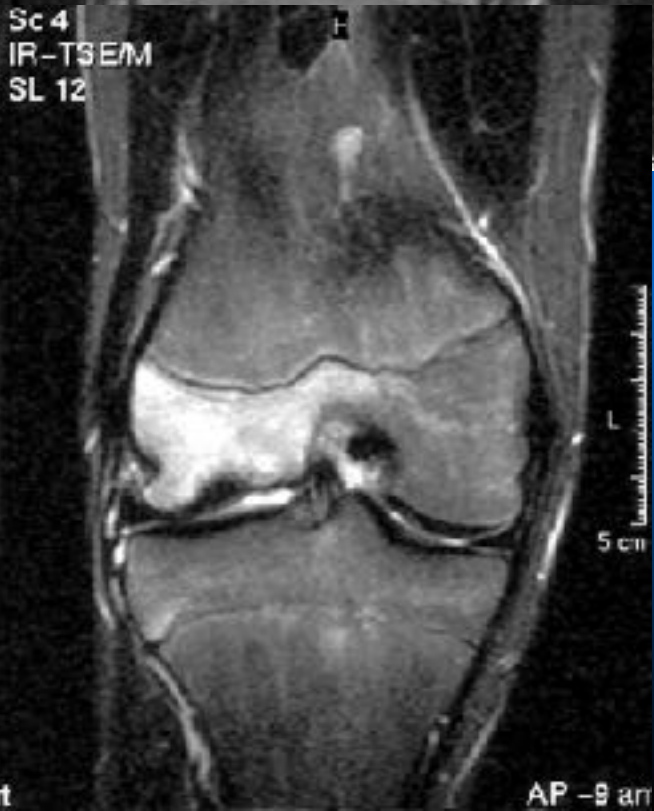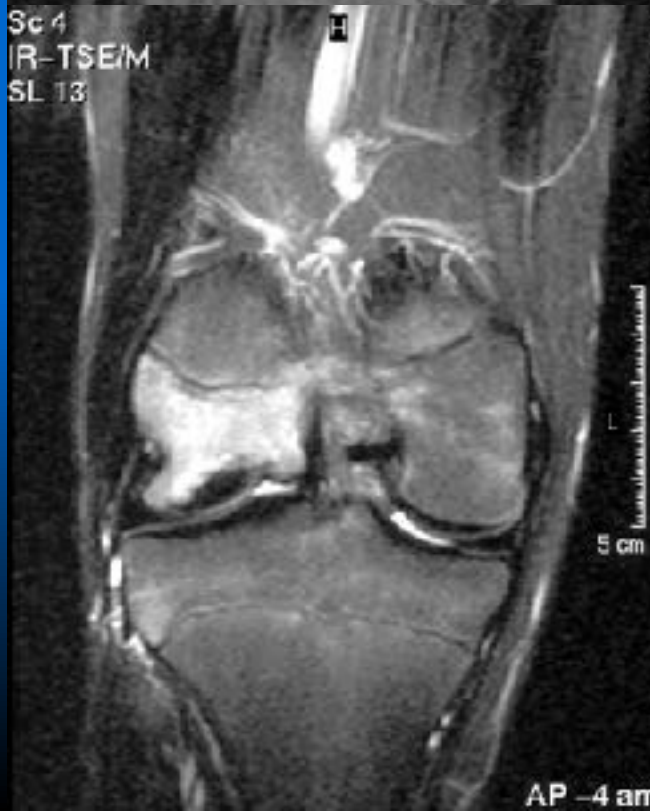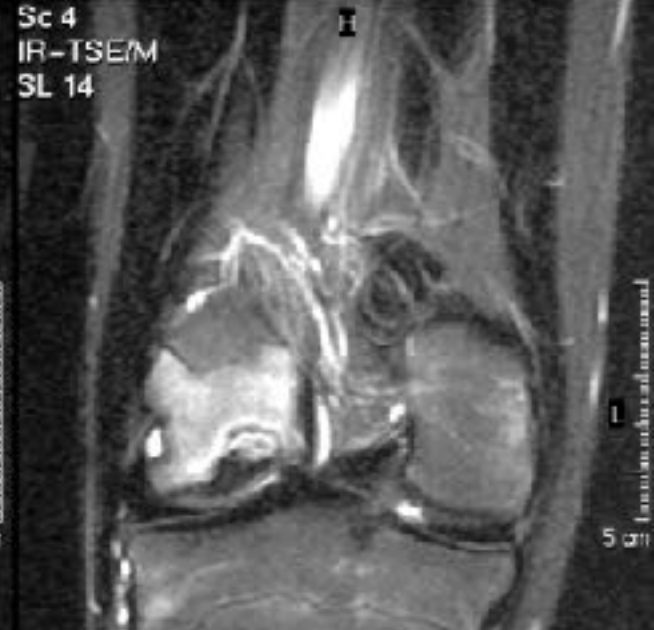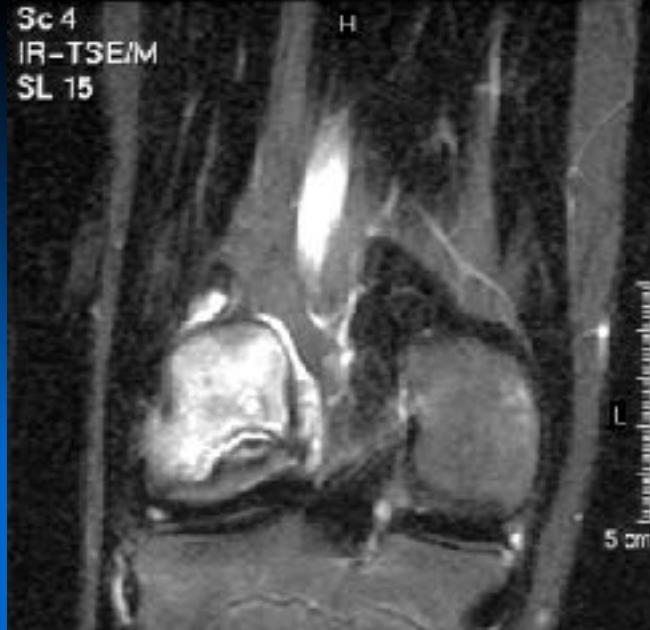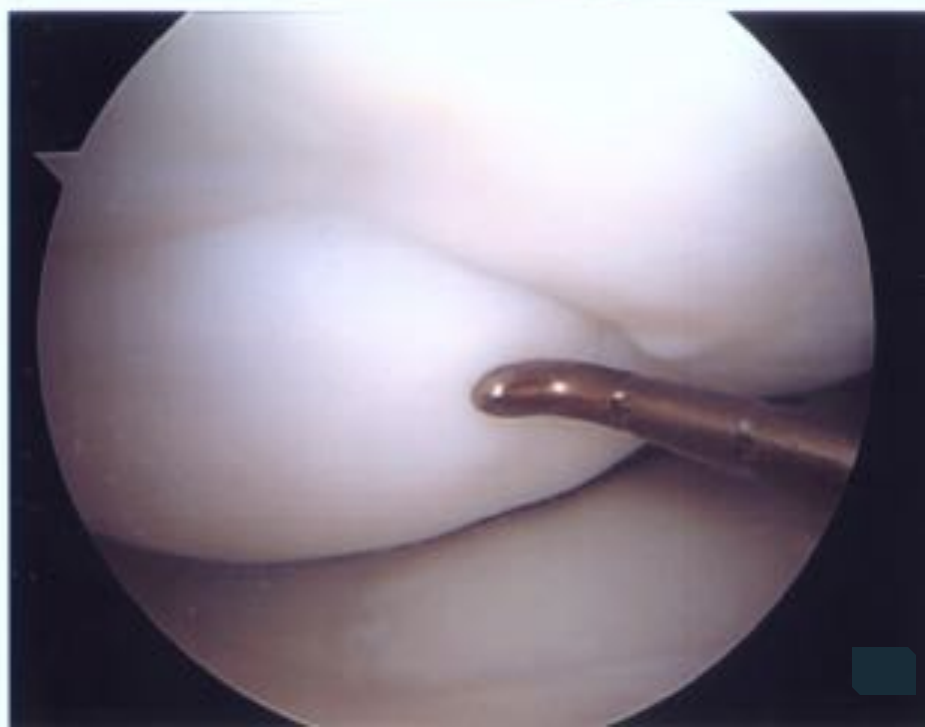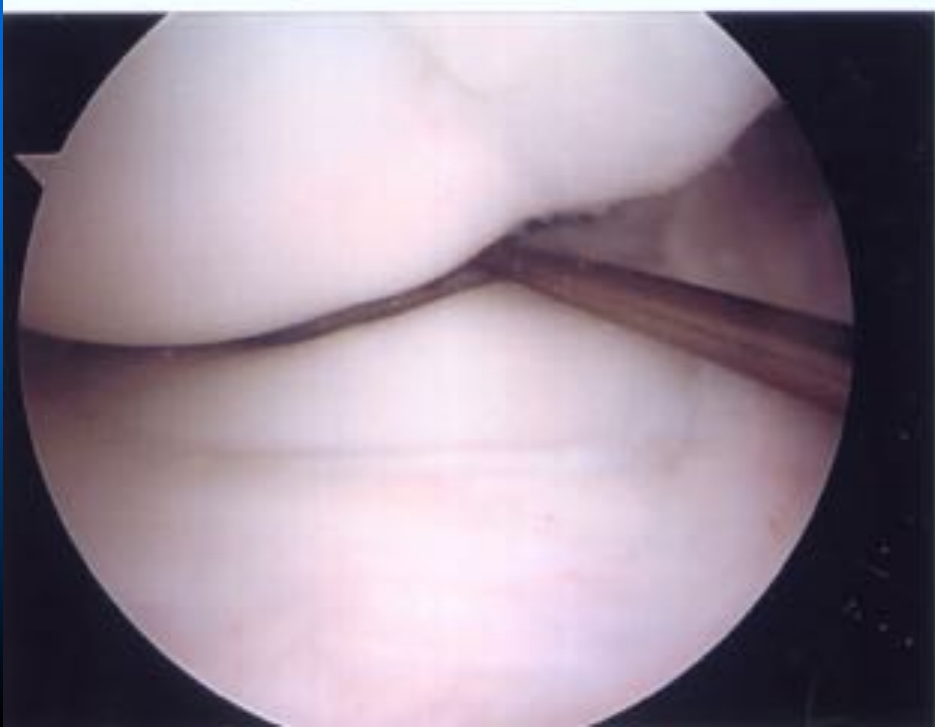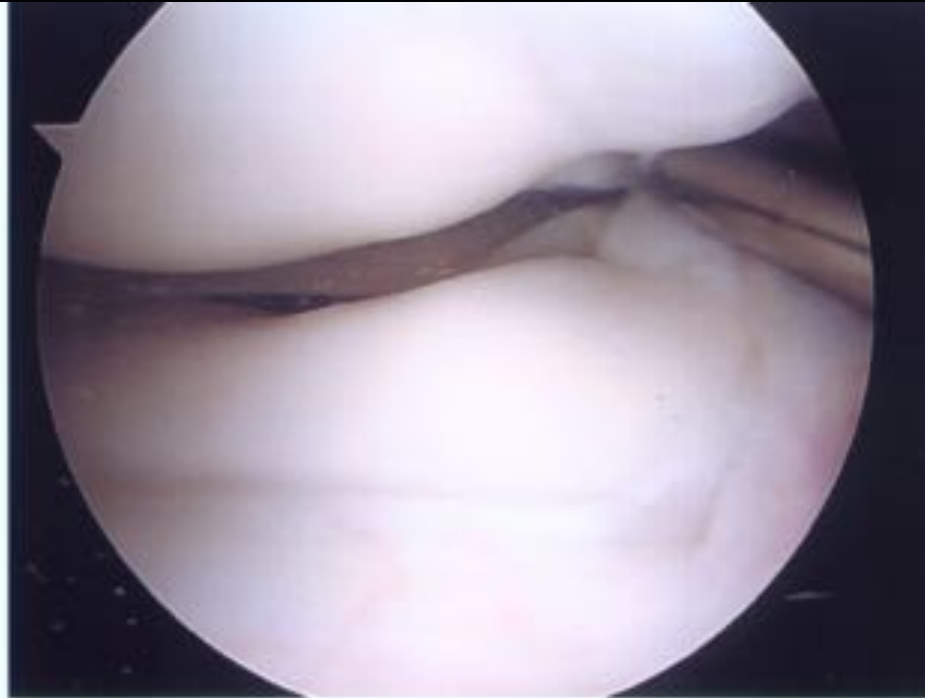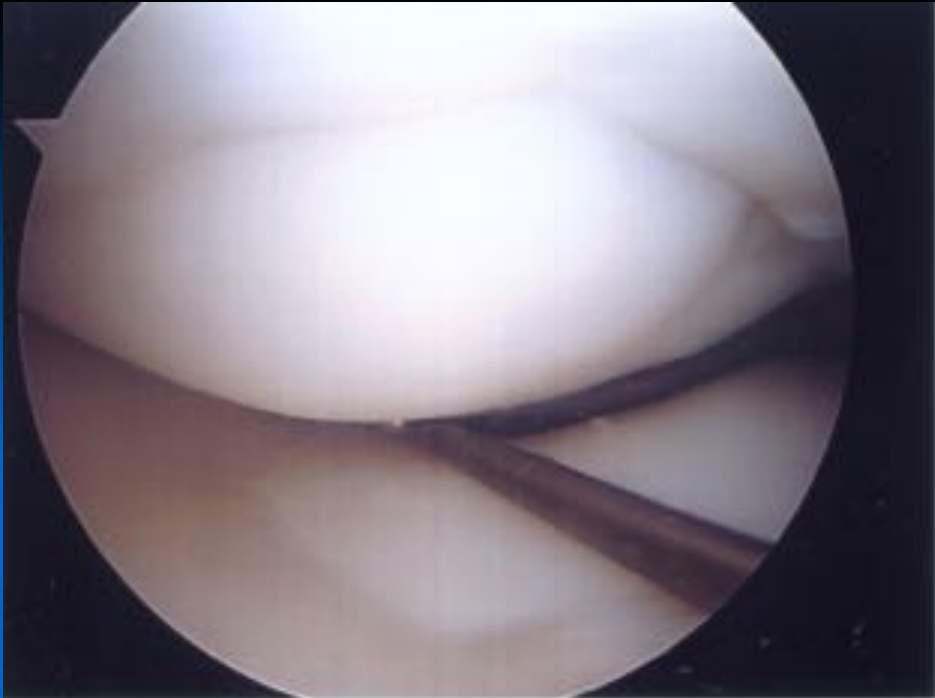
# 16 YO Male

- Basketball athlete
- No specific MOI
- Right knee

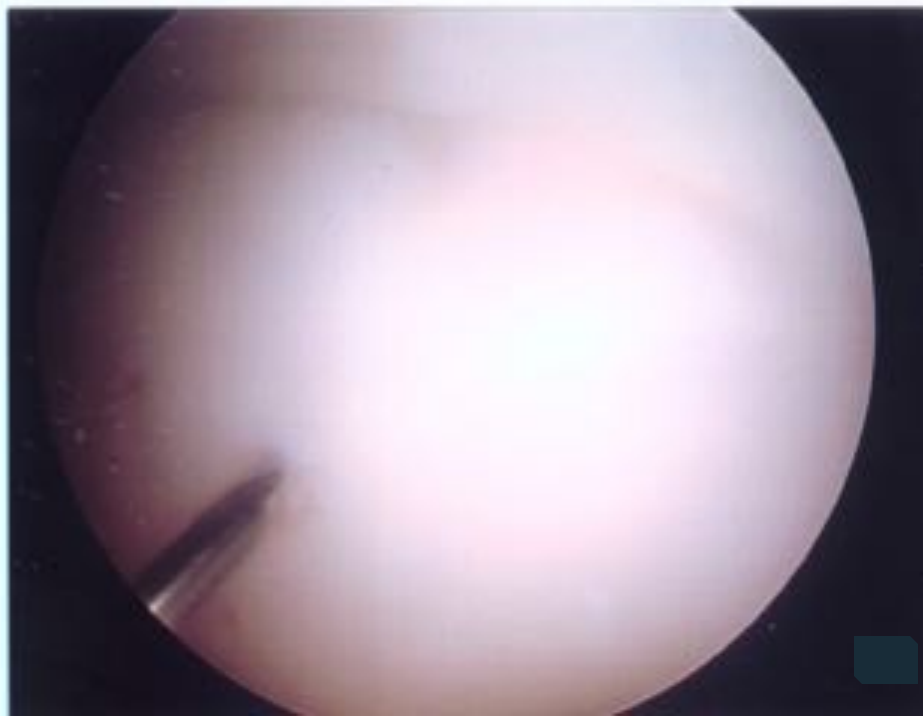
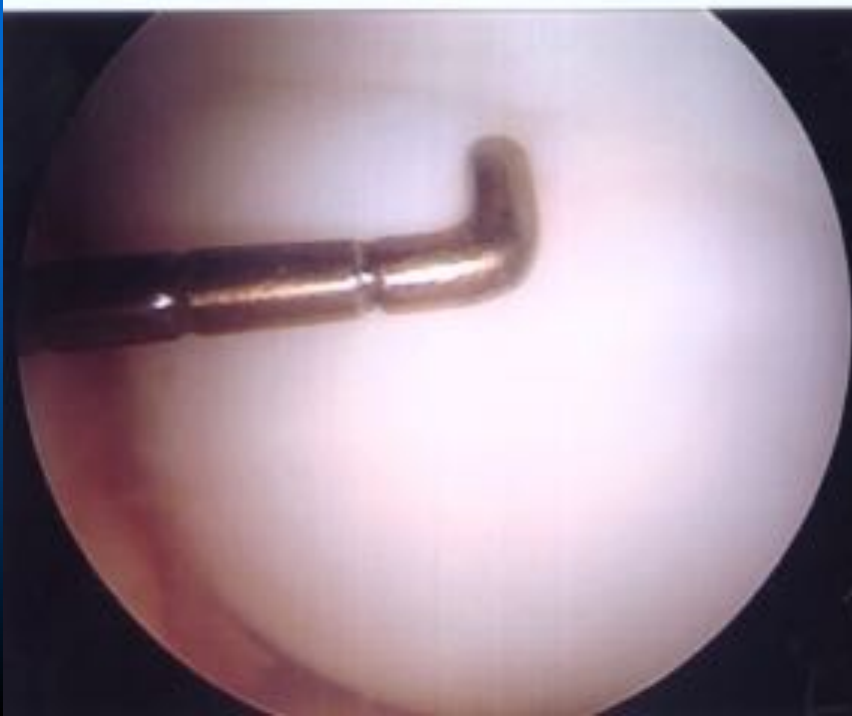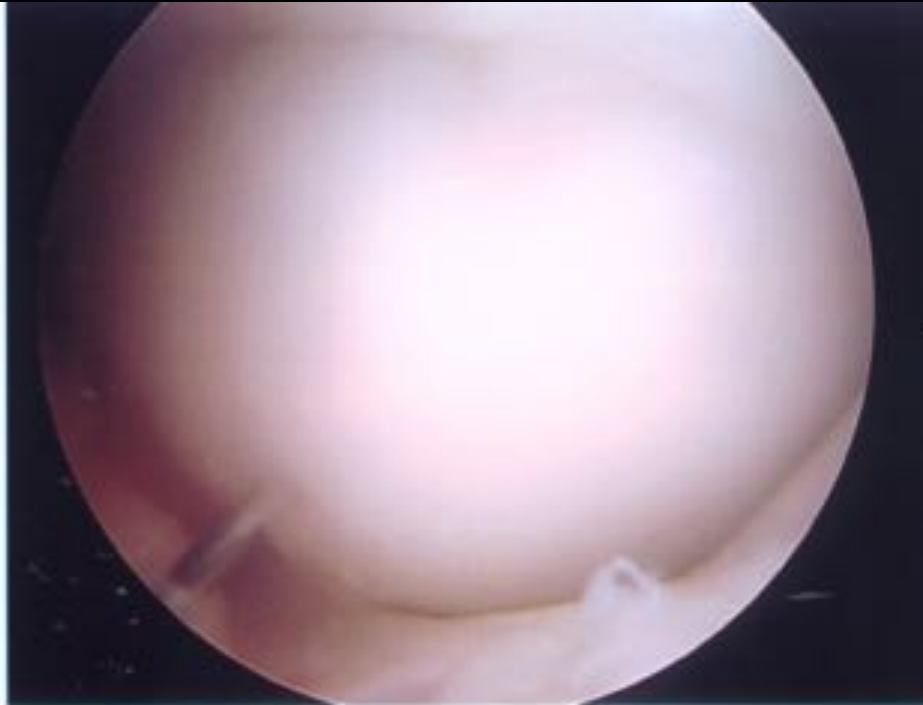

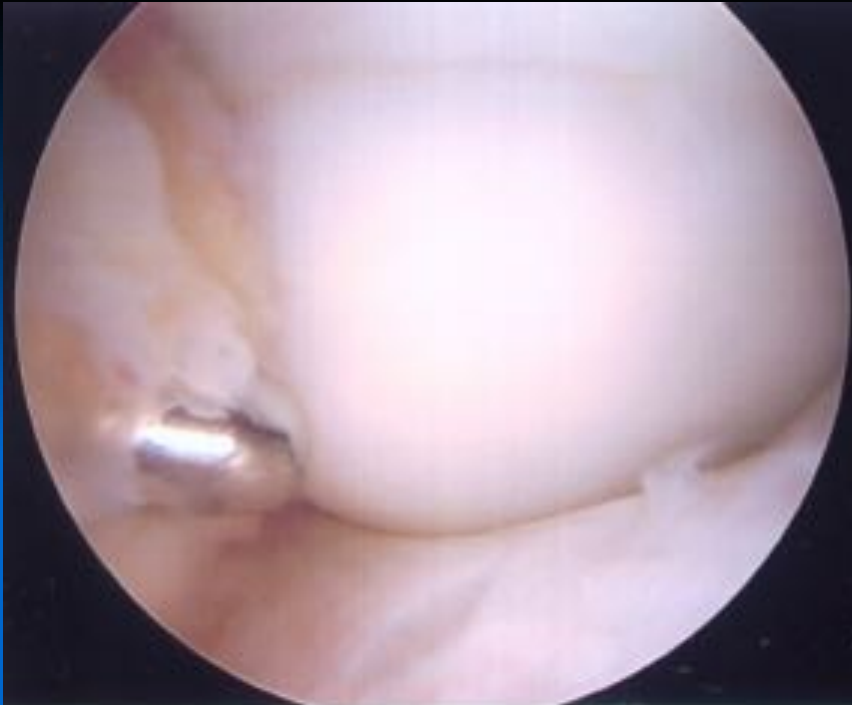








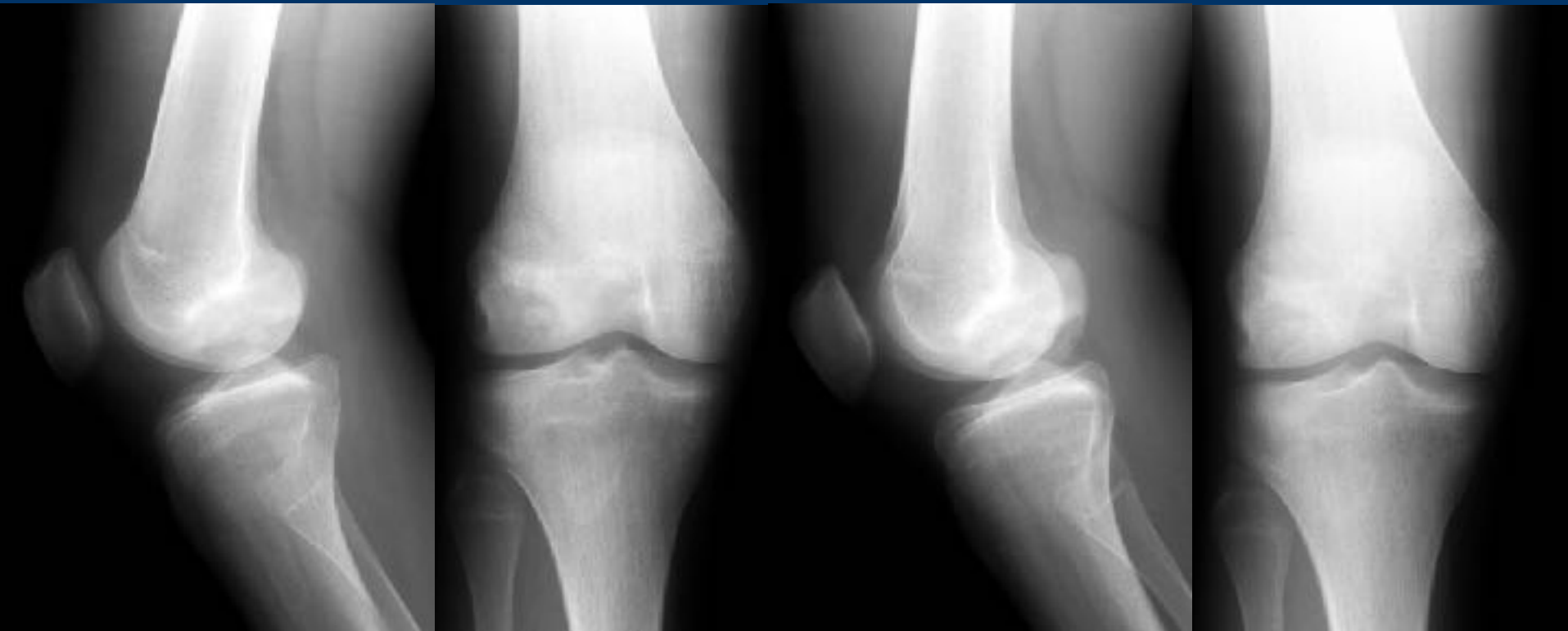



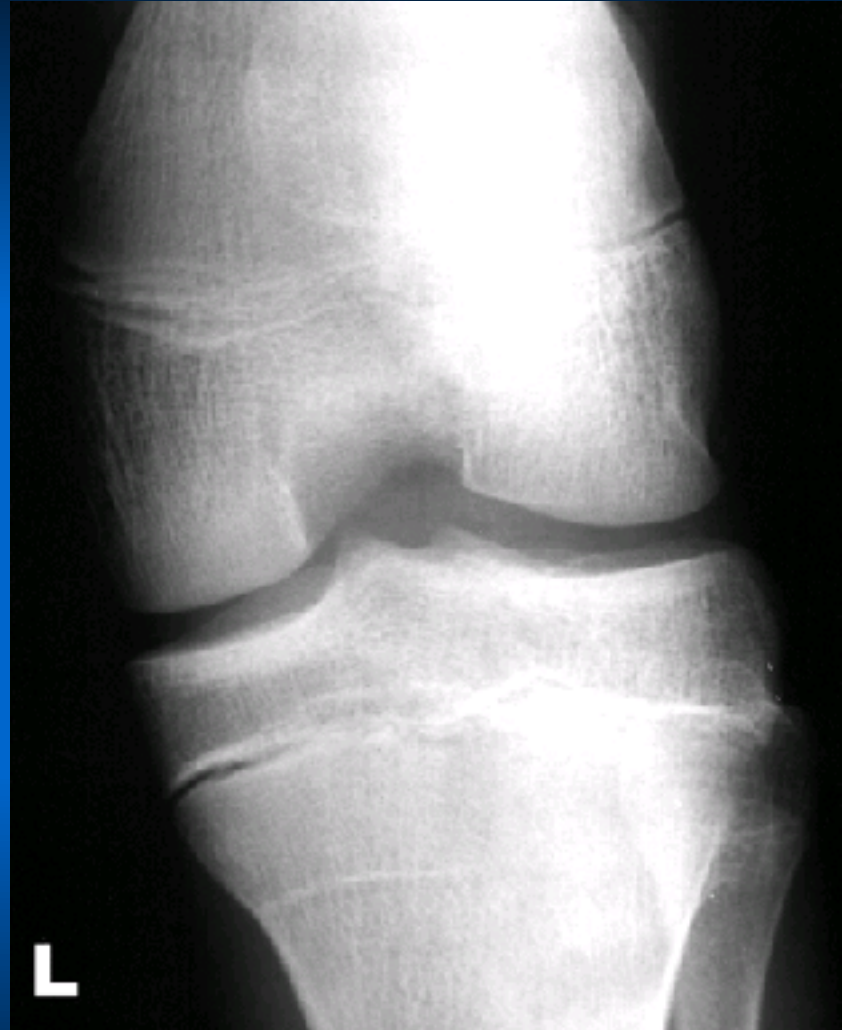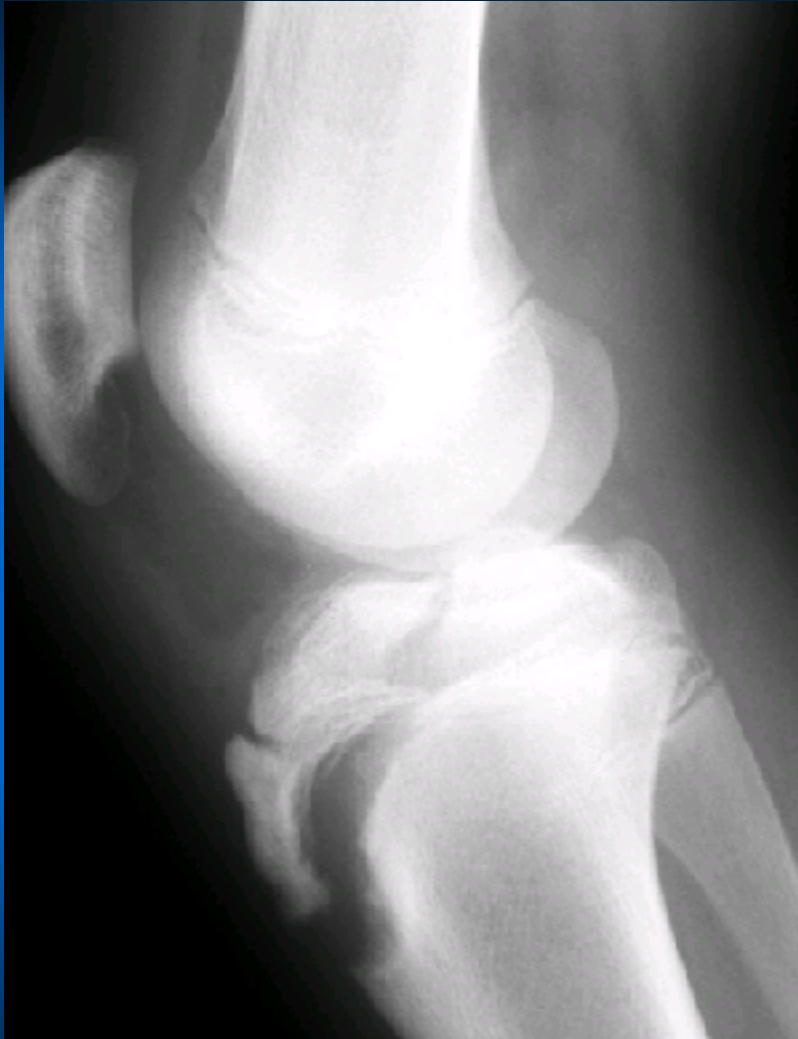**4.5 mo. Post op**

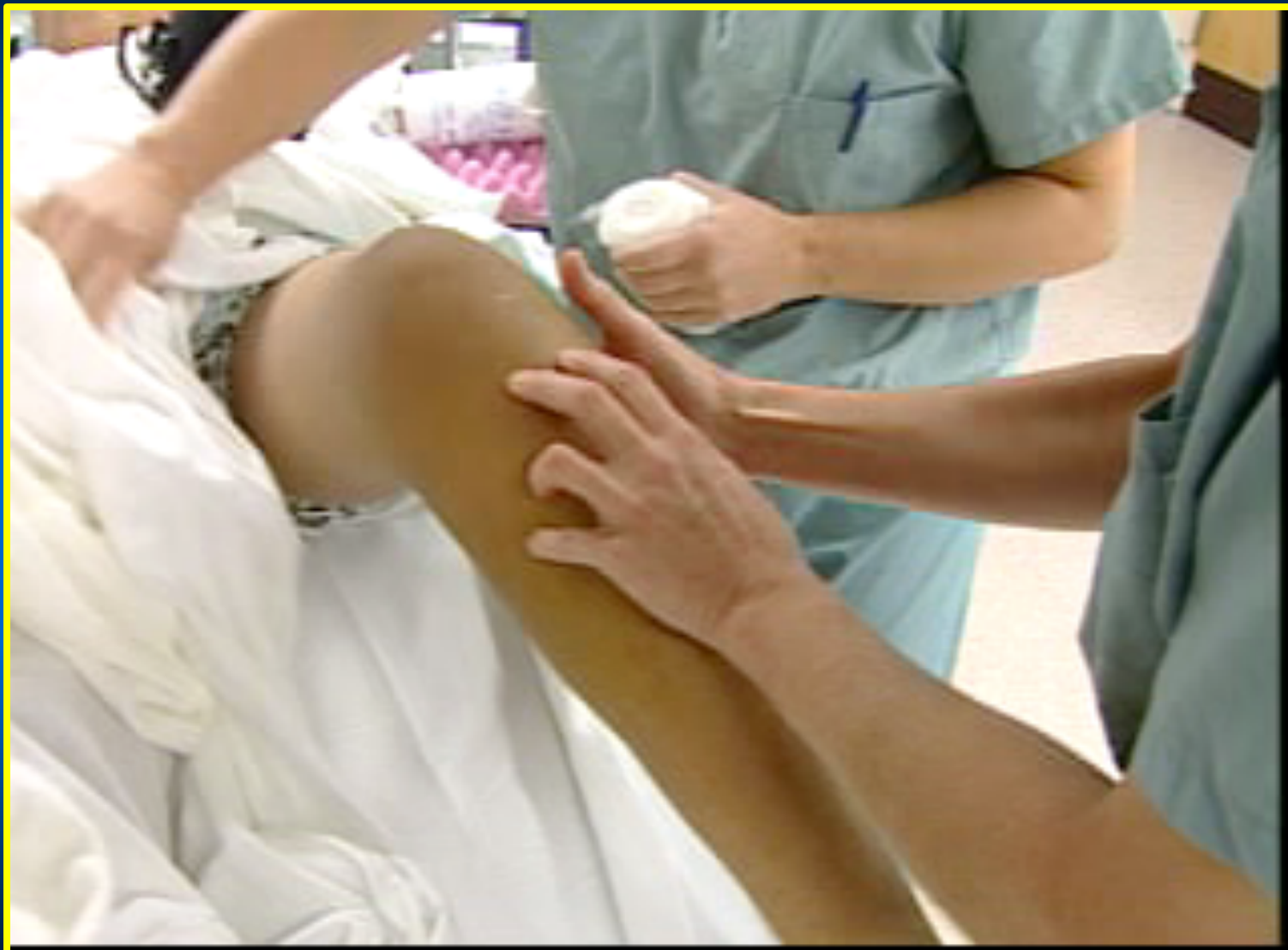**7 mo. Post op**



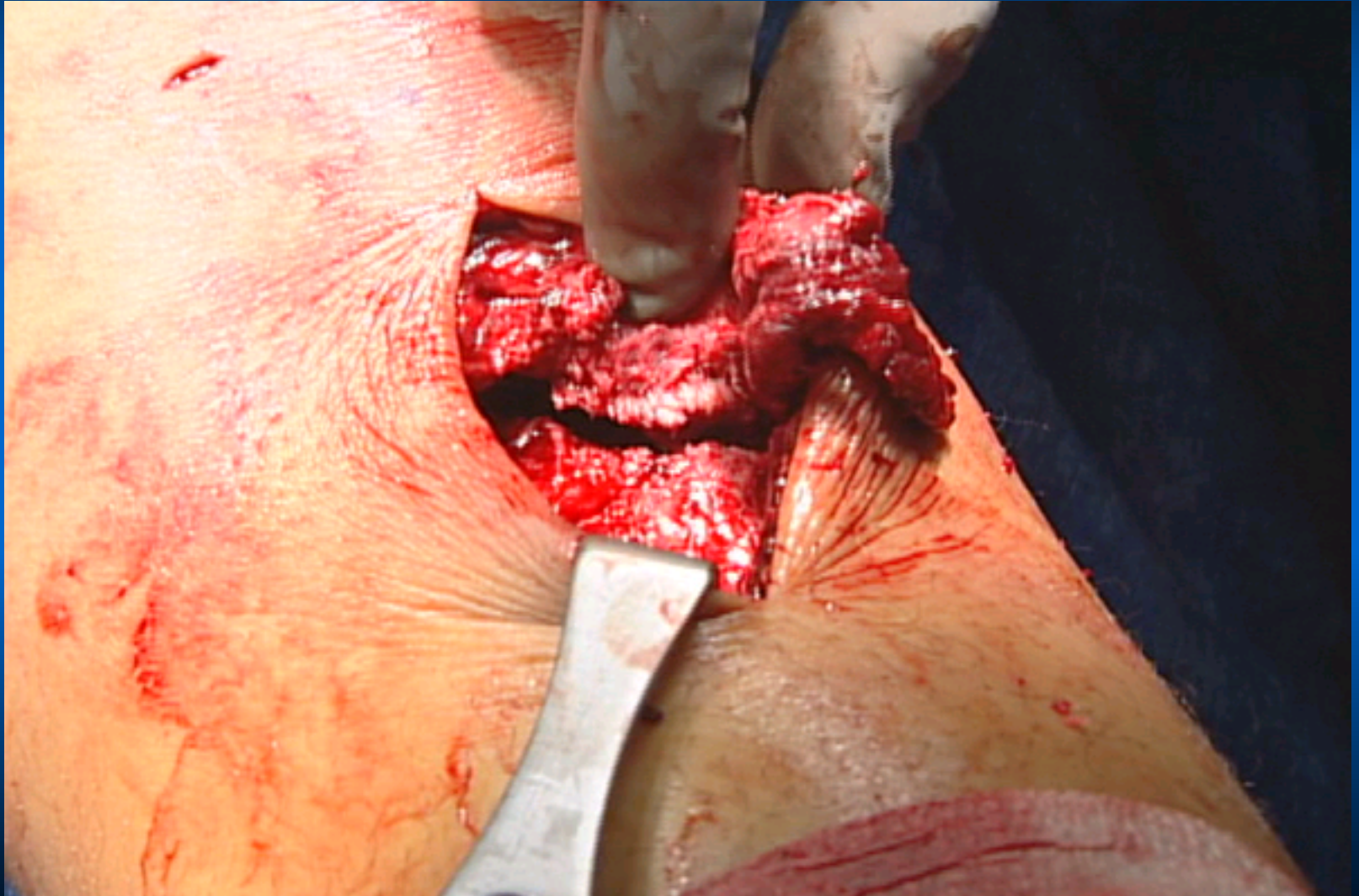
# 16 YO Pickup Game Basketball



**Left Tibia Fracture  
Salter IV Ogden IIIB**

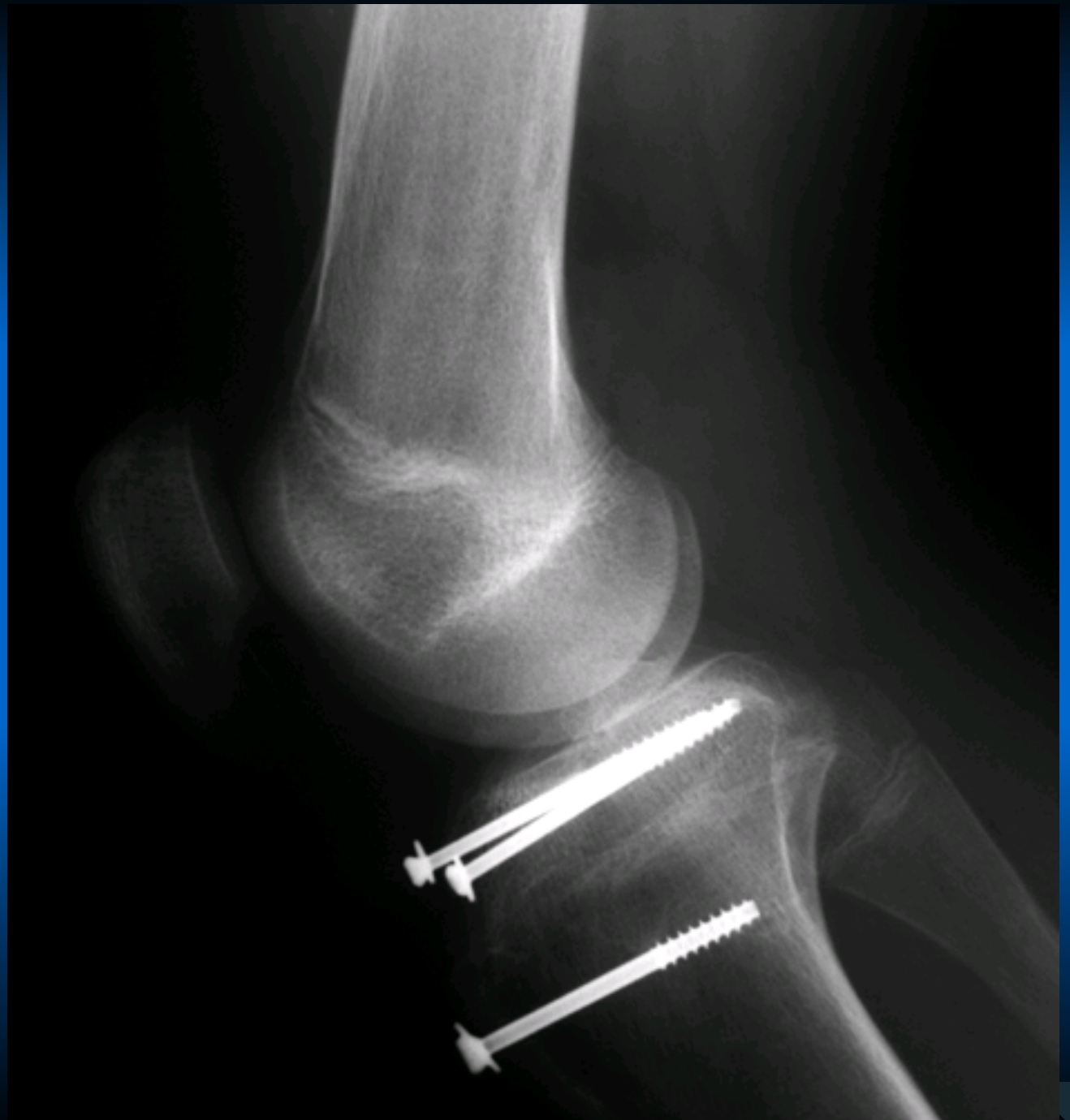

## Surgery: 5 days post injury





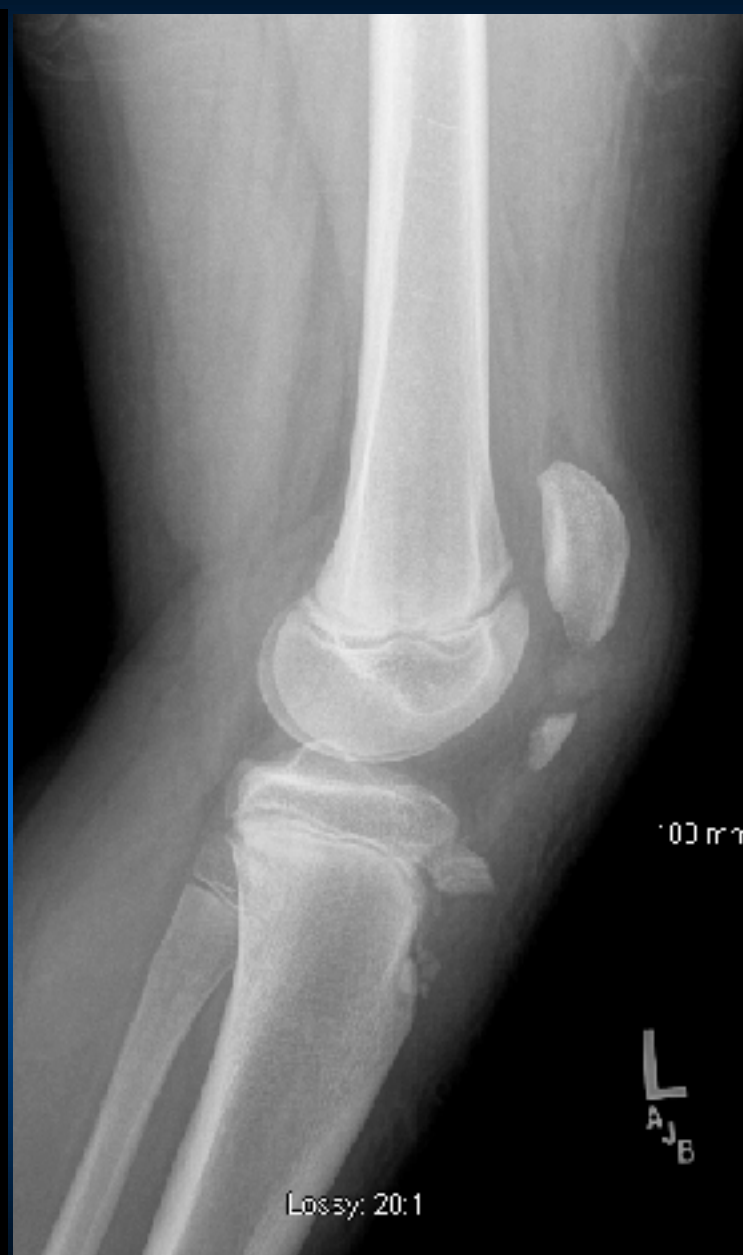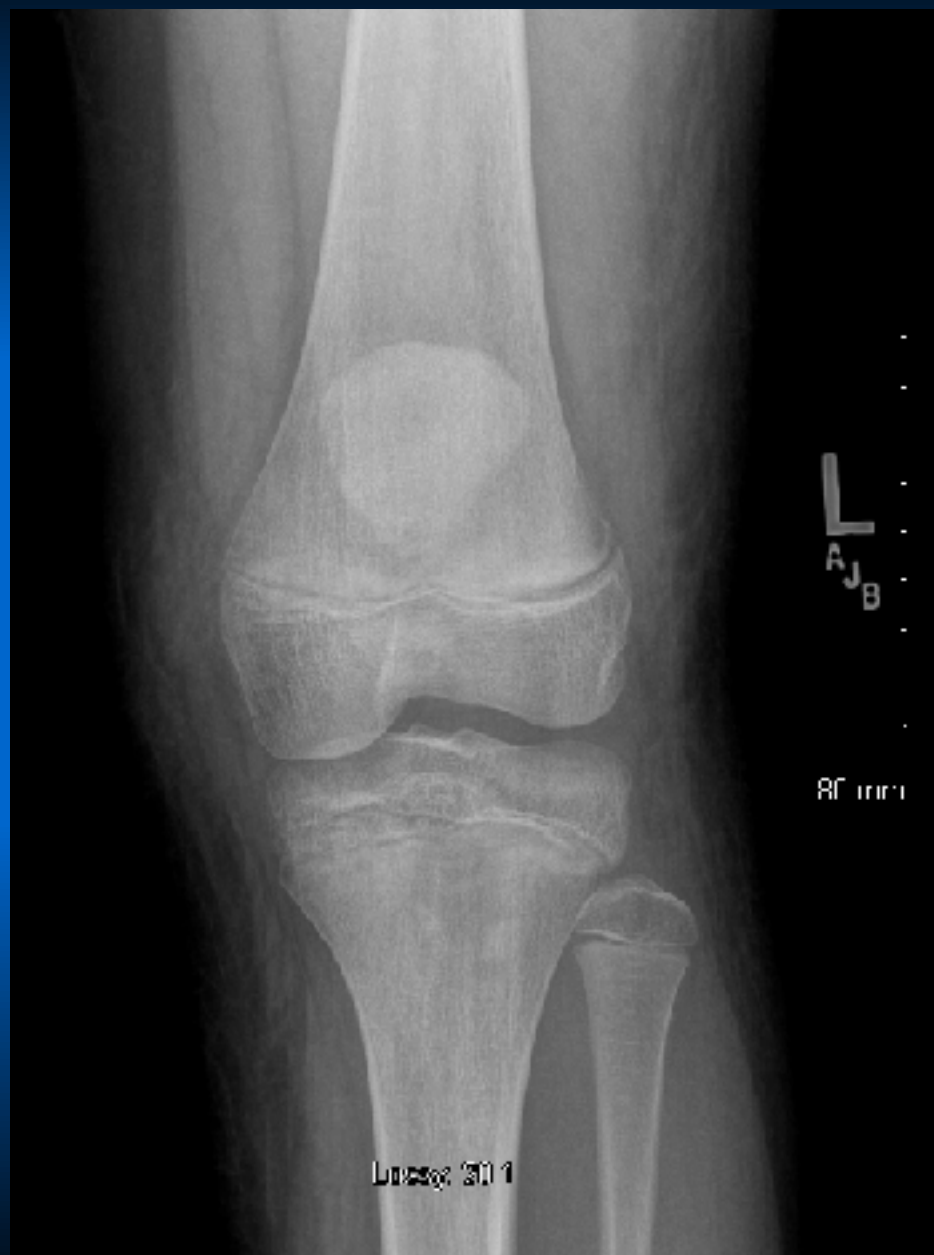**Post  
reduction**

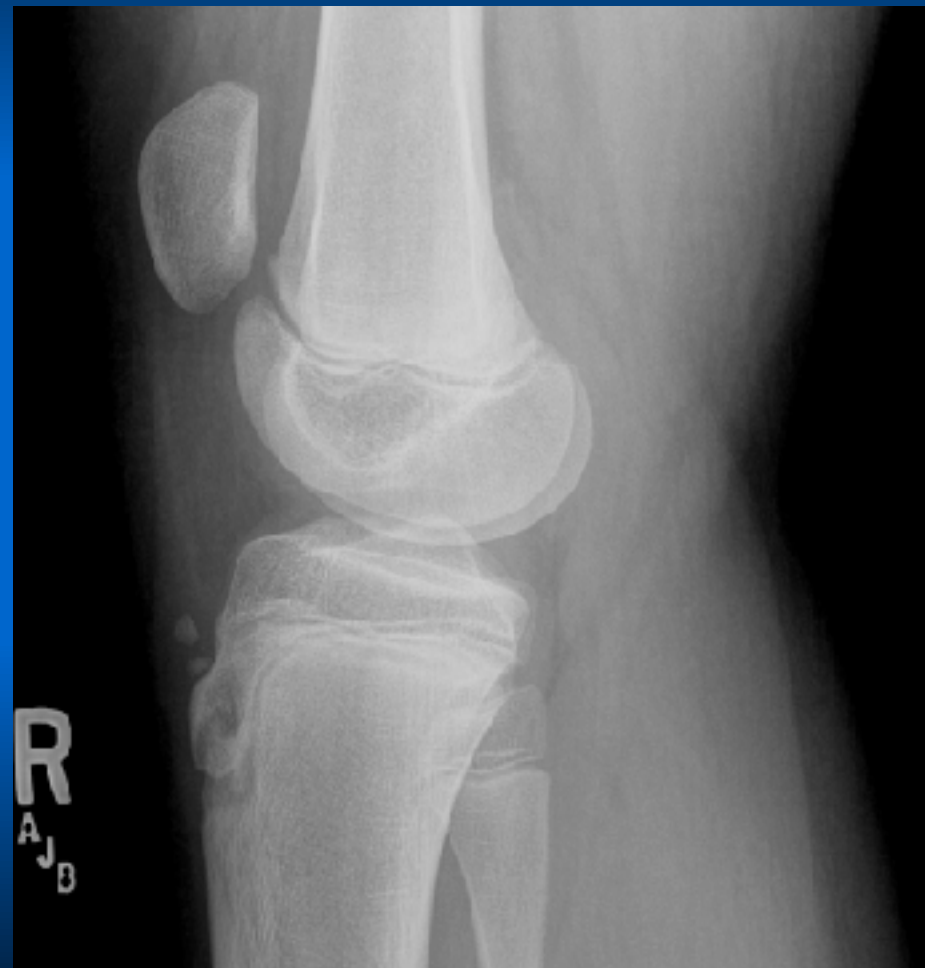
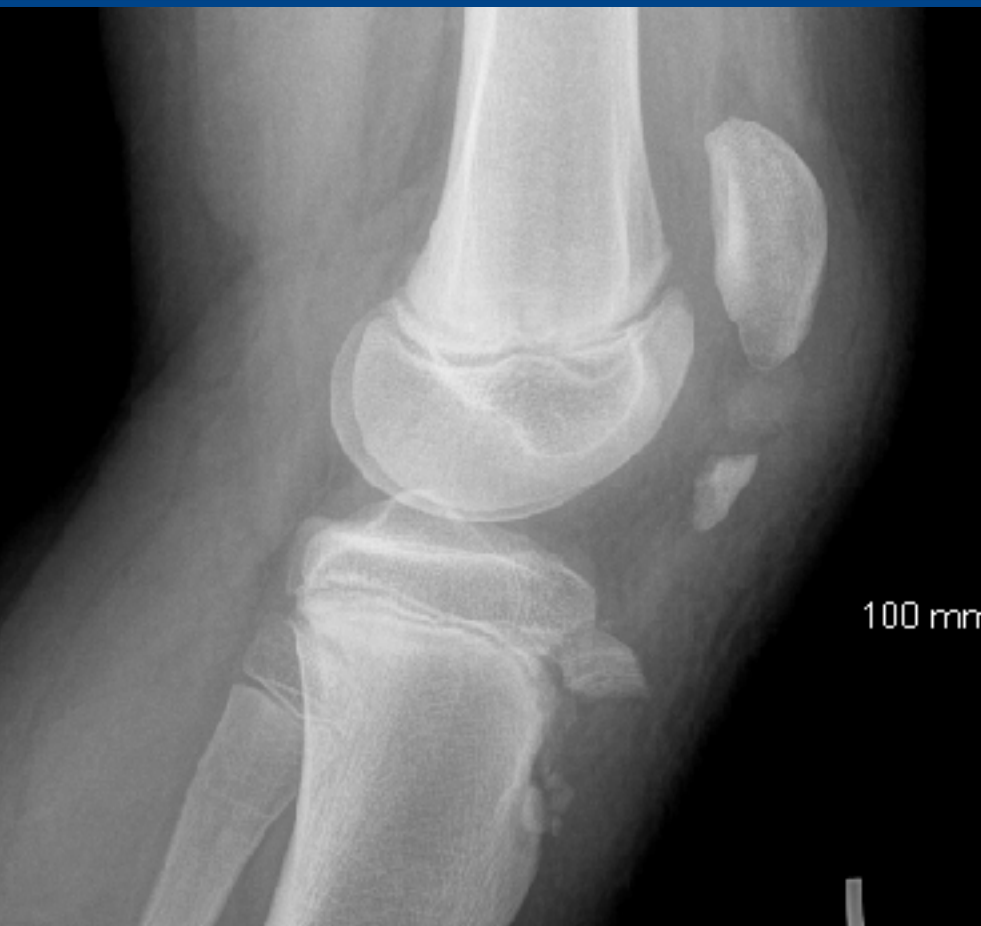


## **History and Physical**

- **12M kicked soccer ball with left leg, felt pain and pop in left knee. Unable to walk**
- **History of Osgood-Schlatter's both knees**
- **Exam:**
  - **Unable to perform straight leg raise**
  - **Palp defect along patellar tendon**



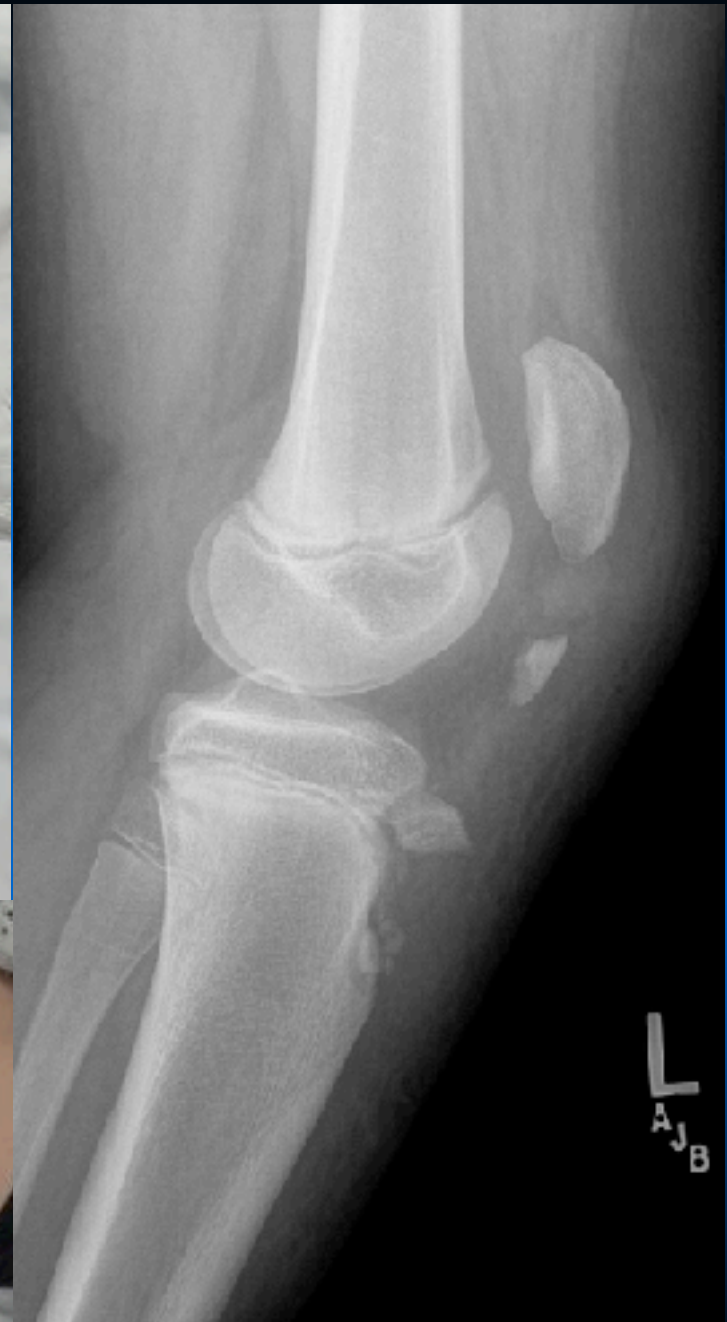
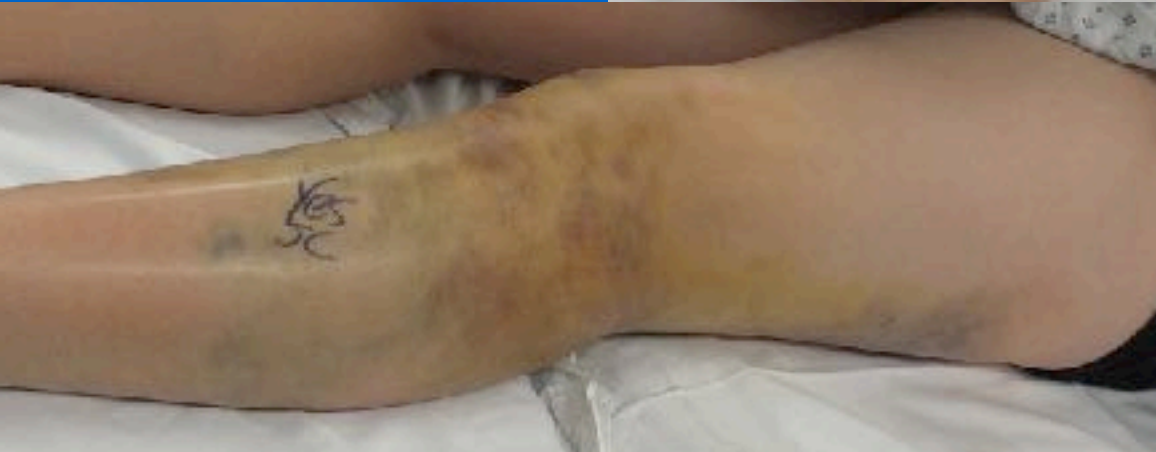
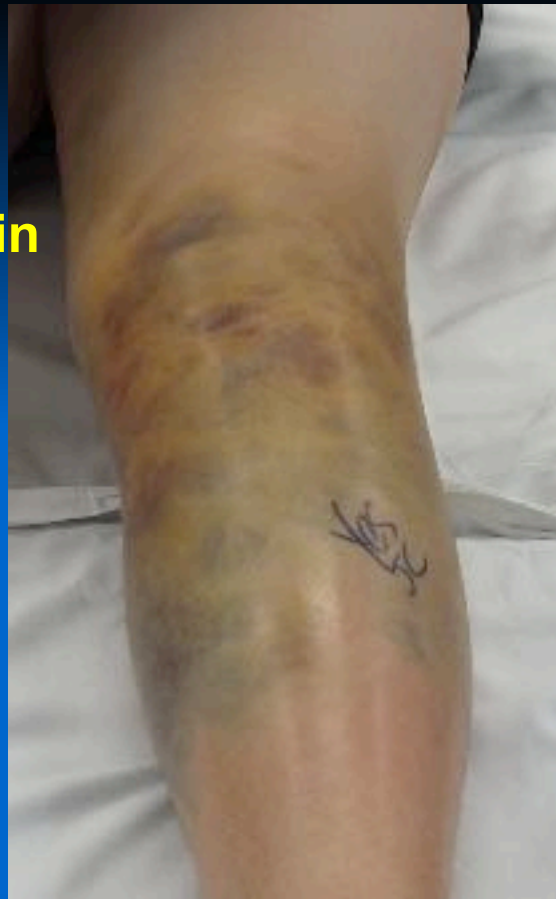**13 year old  
Soccer Athlete  
Acute Left Knee Pain**

- Kicked a Ball
- Planted
- Felt a Pop

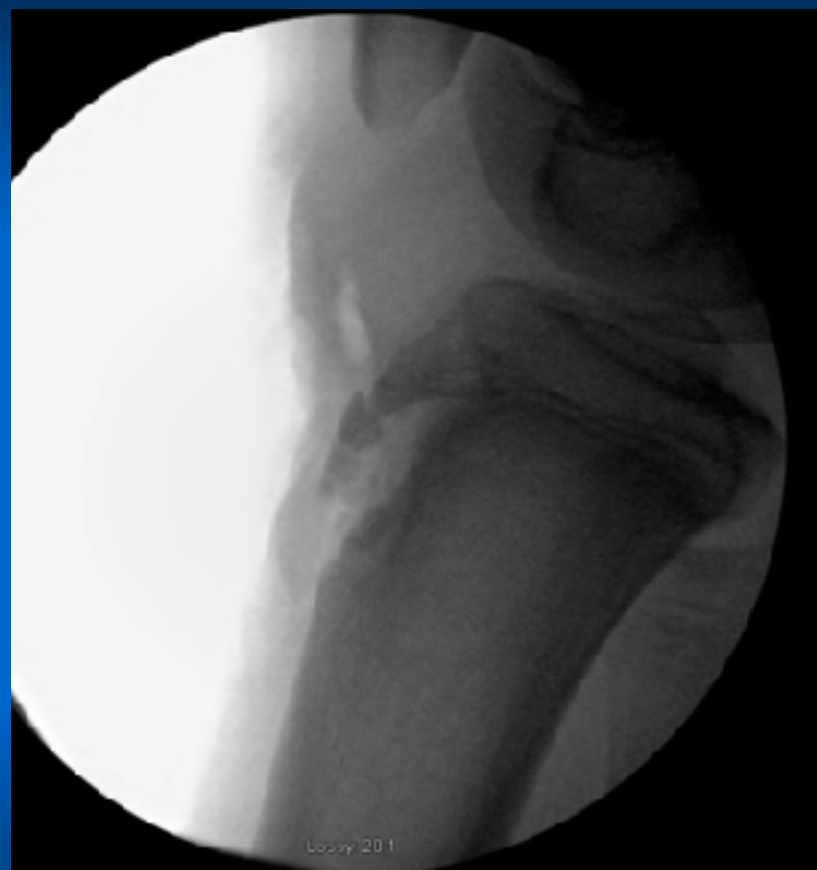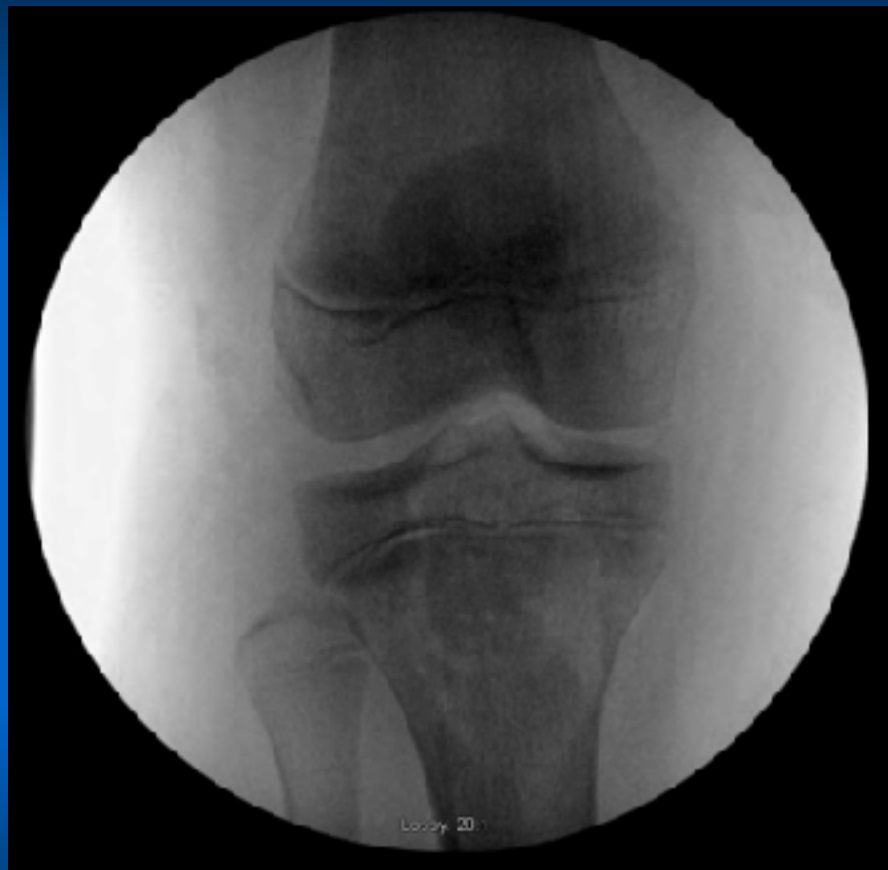**Diagnosis:**

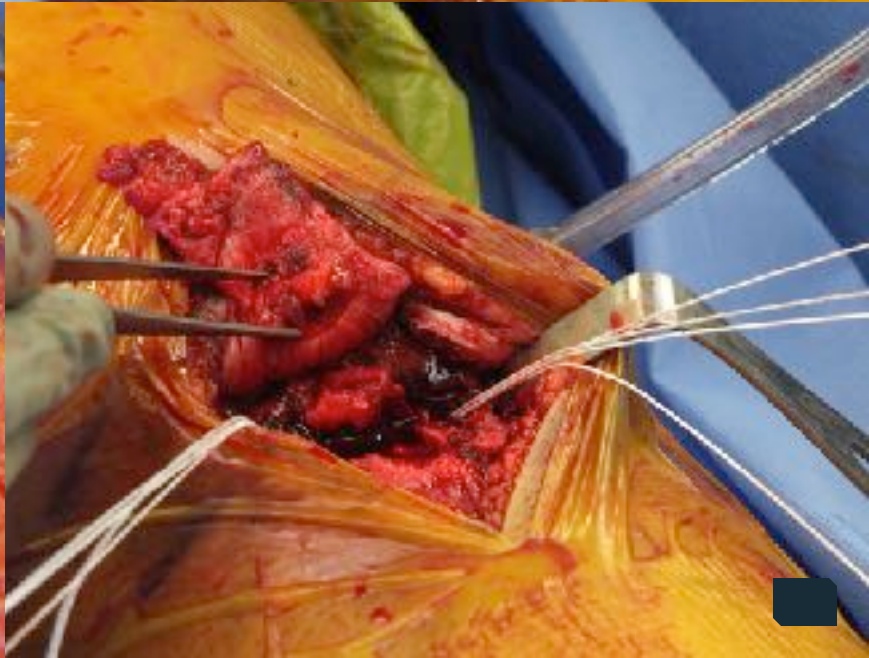
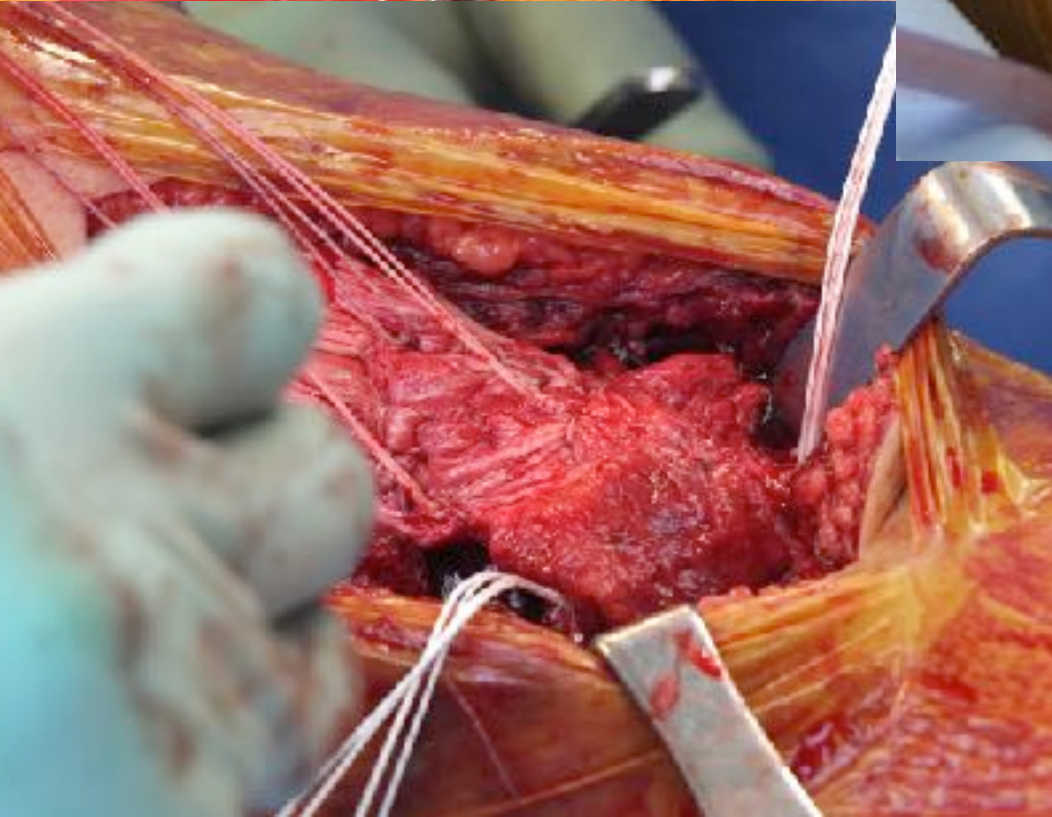
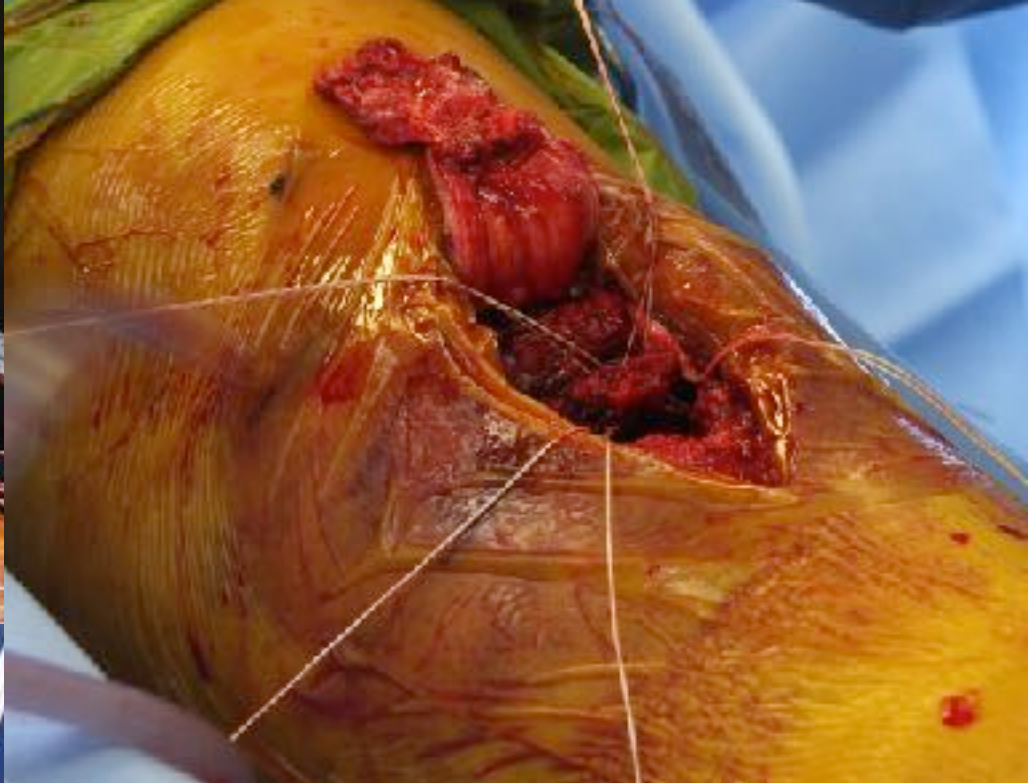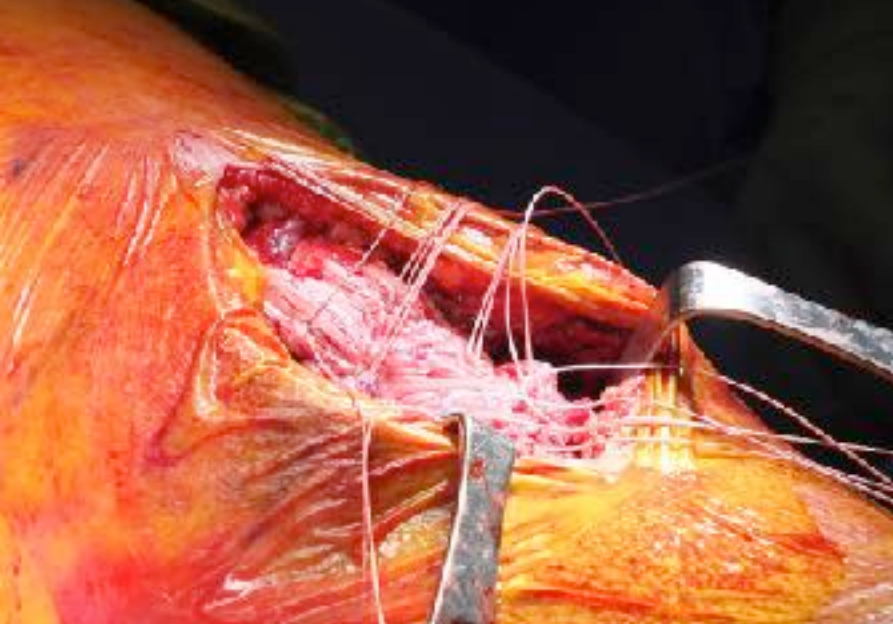
- Displaced,
- Comminuted
- Tibial Tubercle
- Fracture



EUA



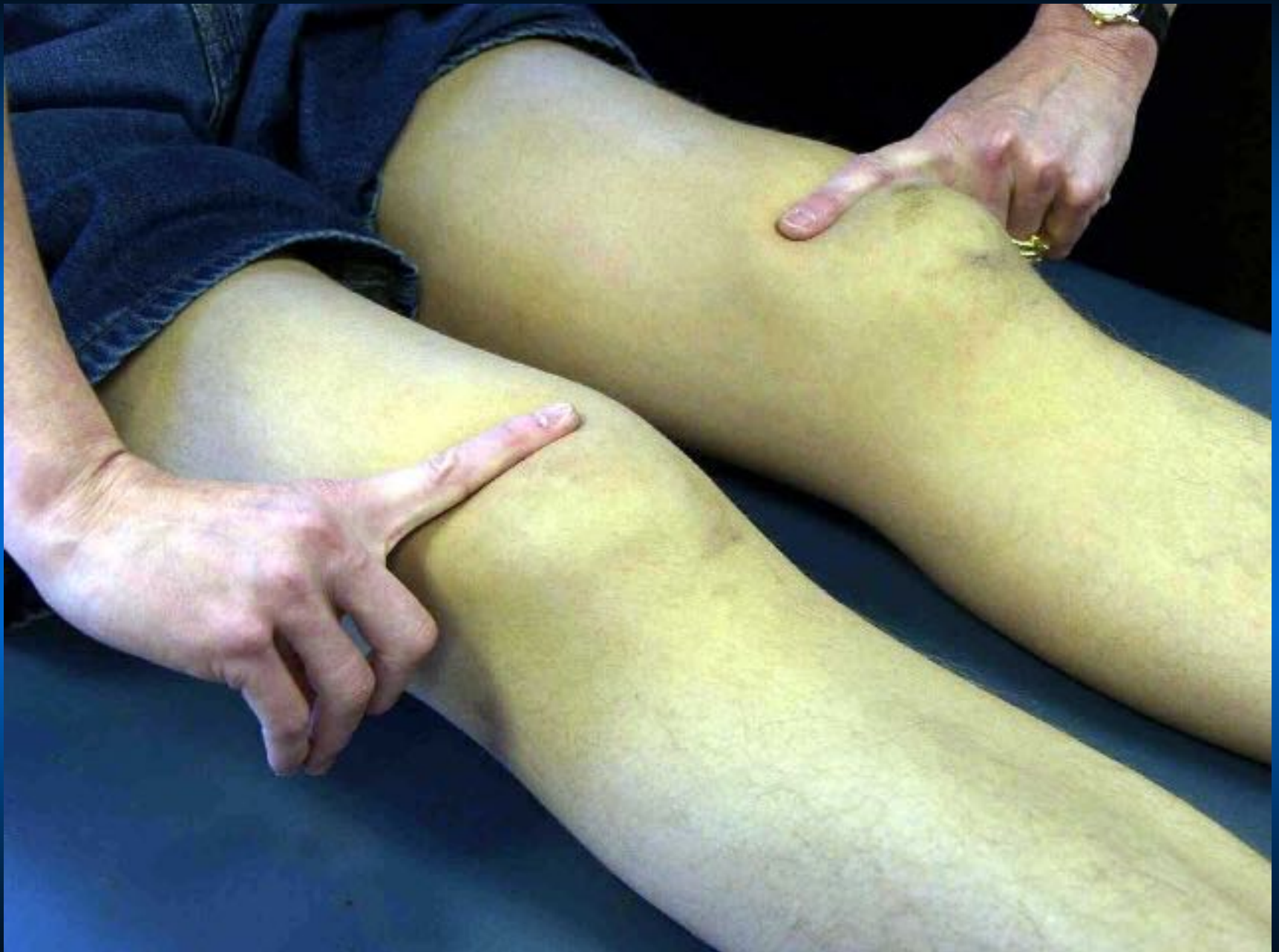


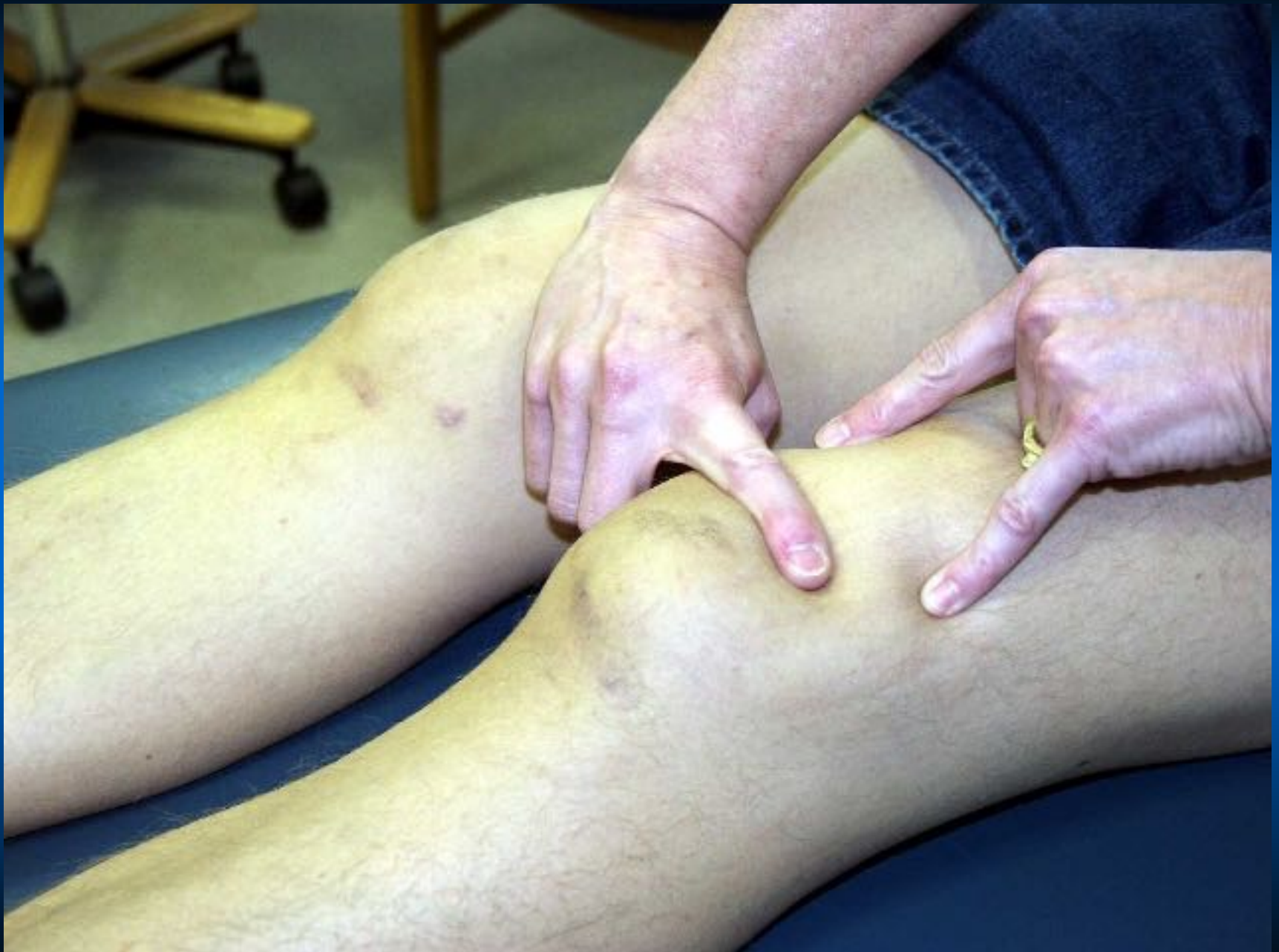
## 21 YO Male

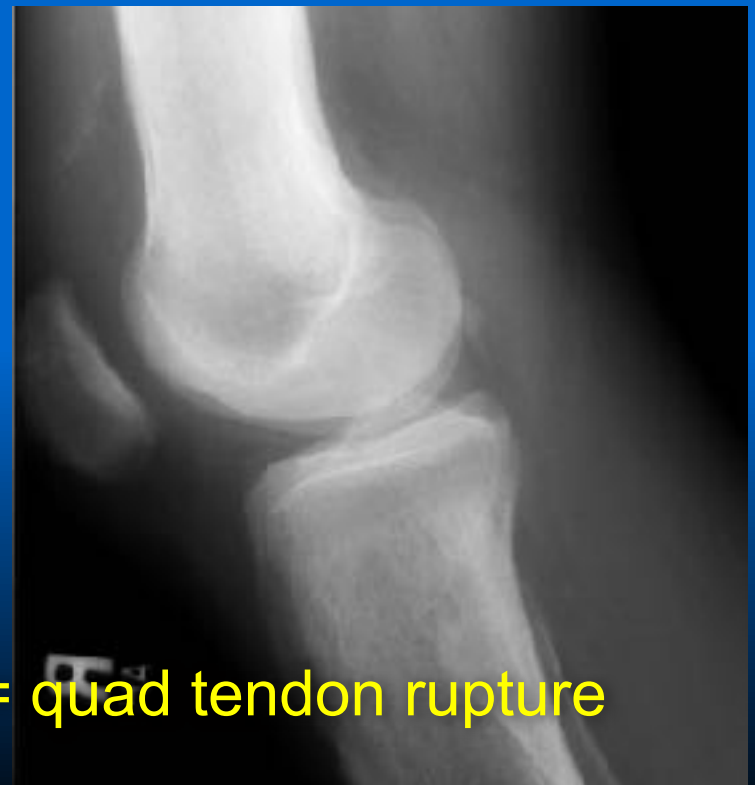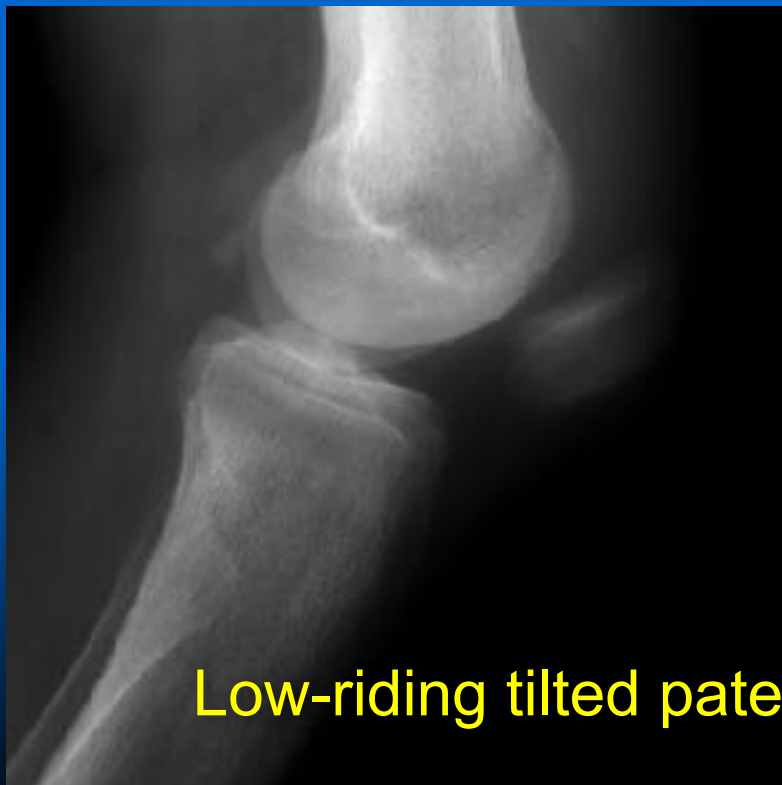
- Playing basketball
- C/O Left Knee pain
- 3 days later, playing basketball, left knee collapsed and right knee hurt
- Renal dialysis patient on peritoneal dialysis, awaiting 2nd kidney transplant



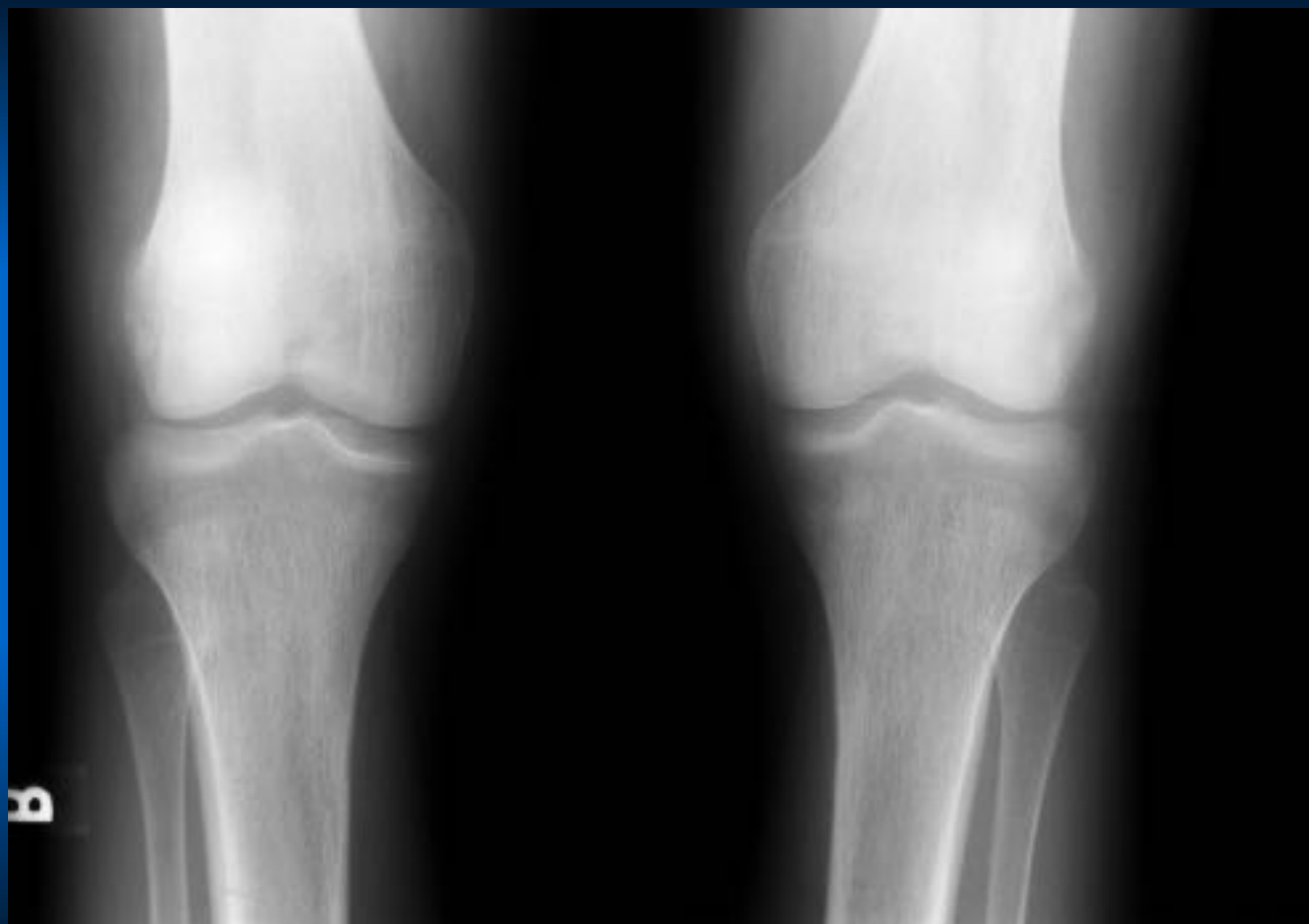



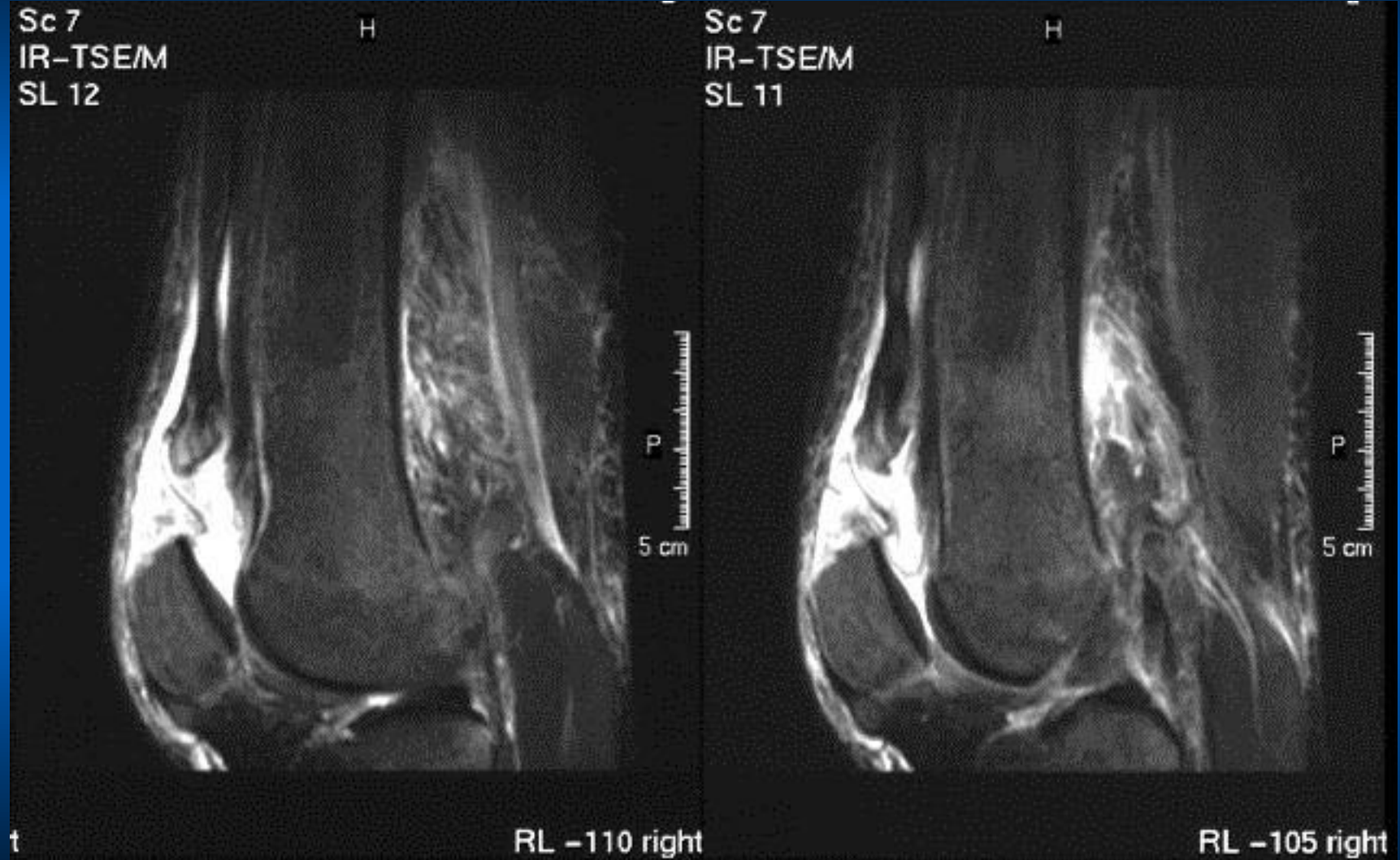




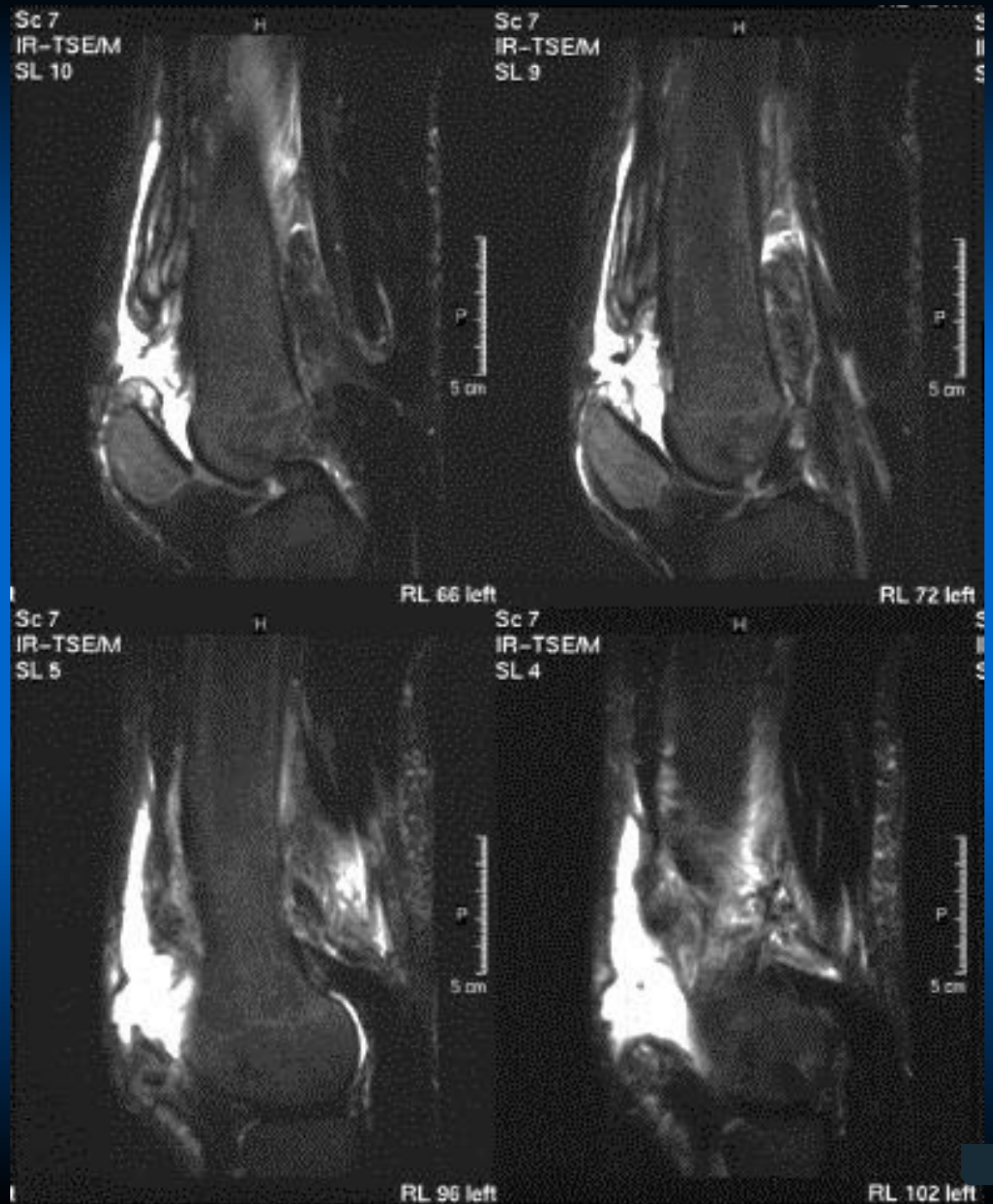
Low-riding tilted patella = quad tendon rupture

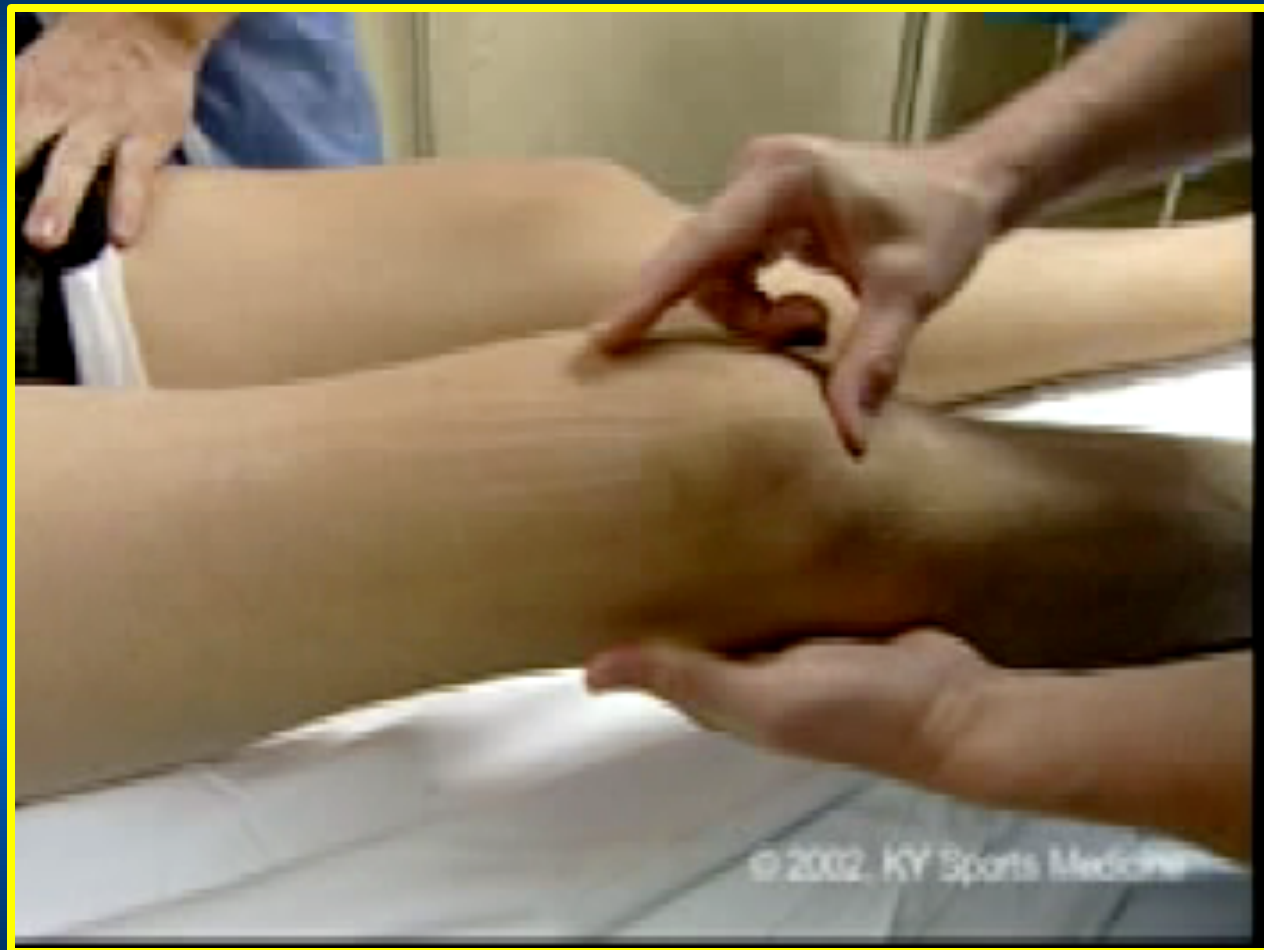

# MRI: Right Knee



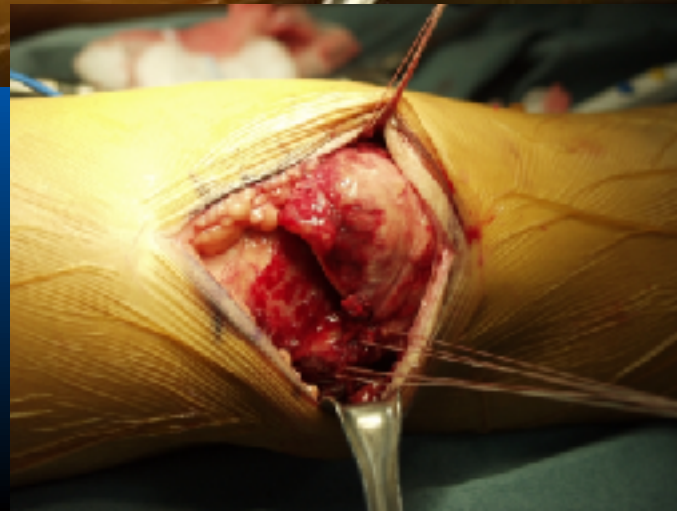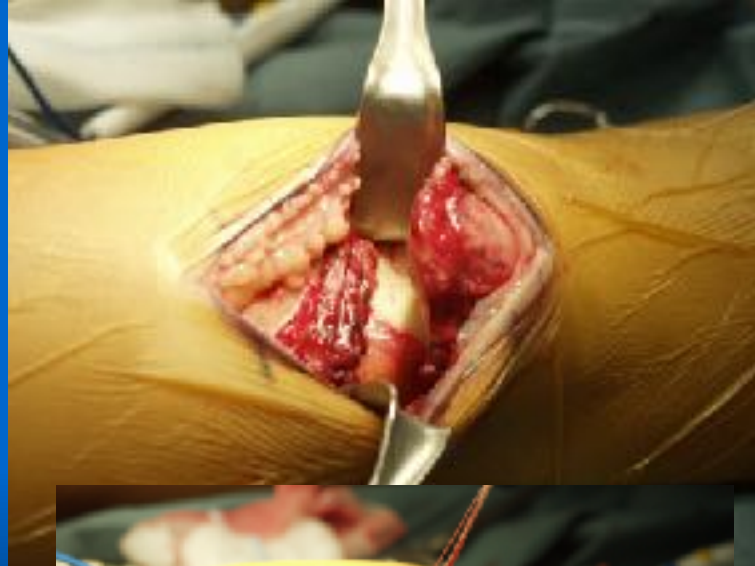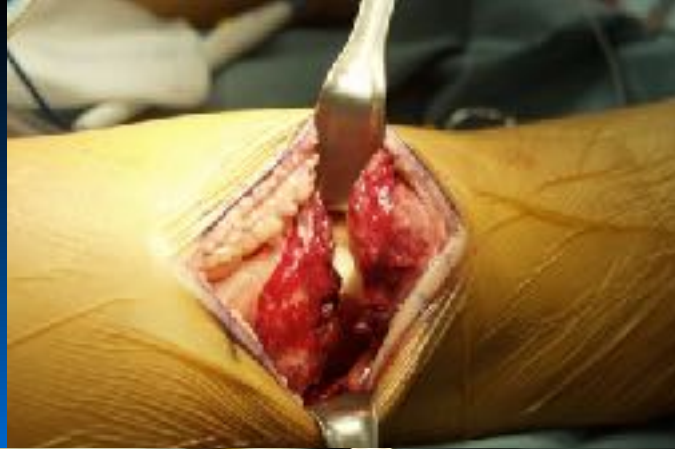# MRI: Left knee

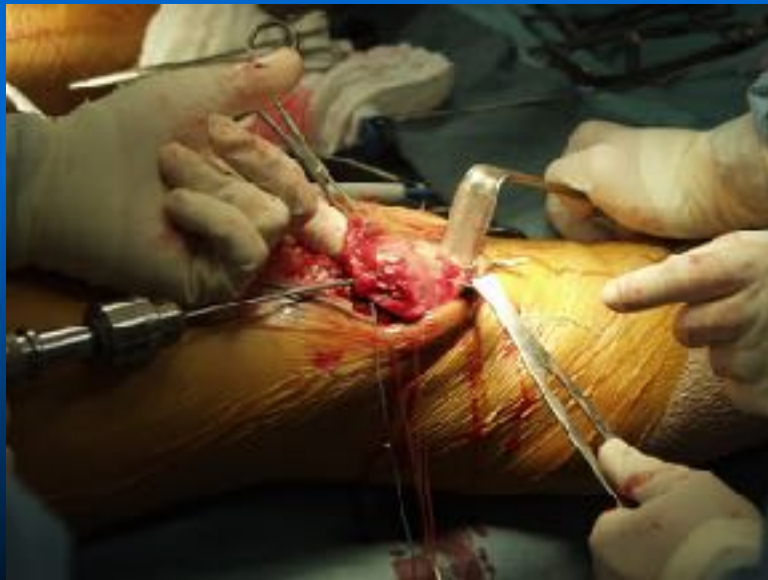
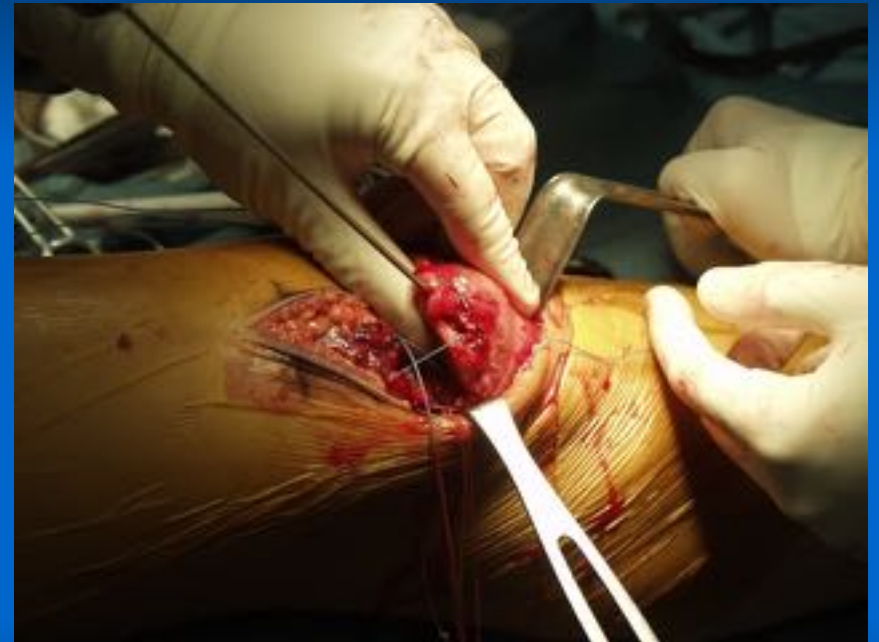
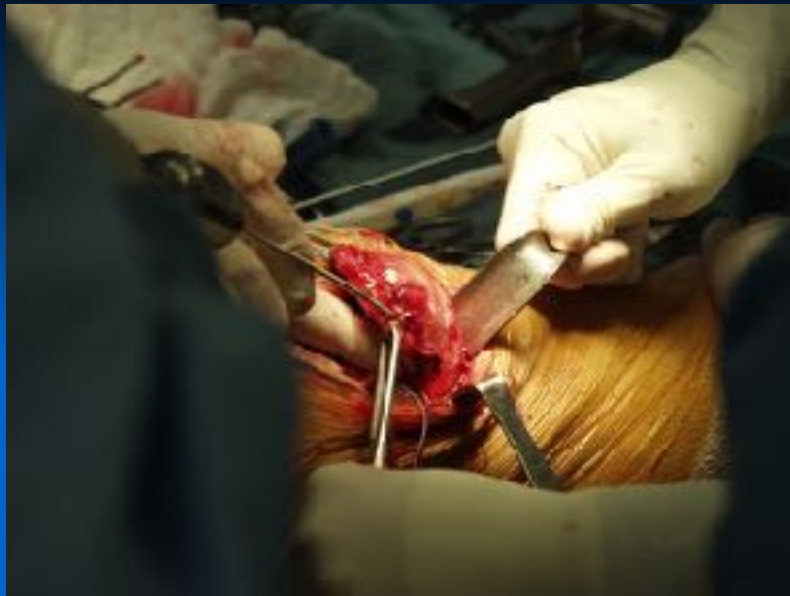

© 2002, KY Sports Medicine







# Antibiotics Linked To Tendon Ruptures, Anticholesterol Lowering Meds

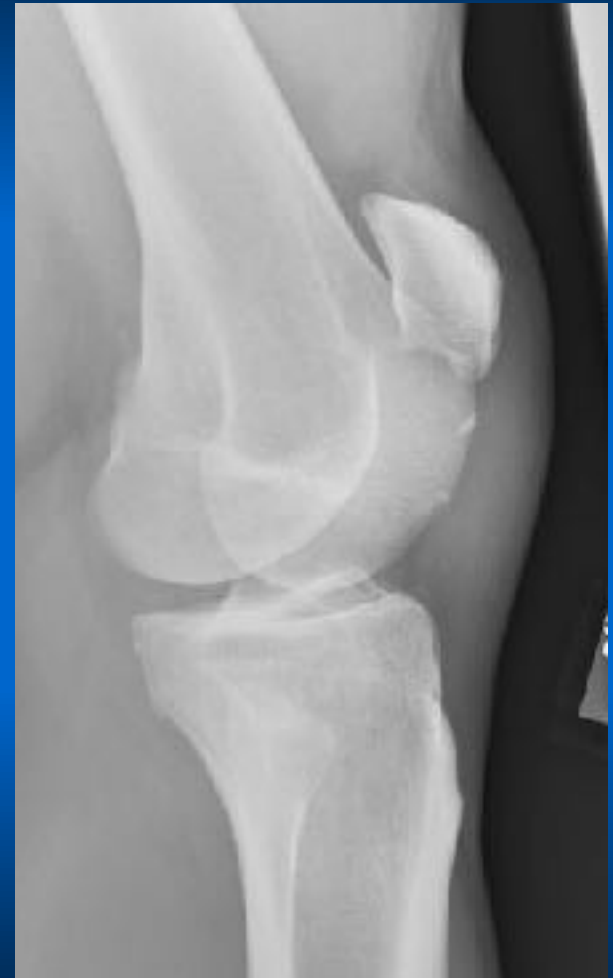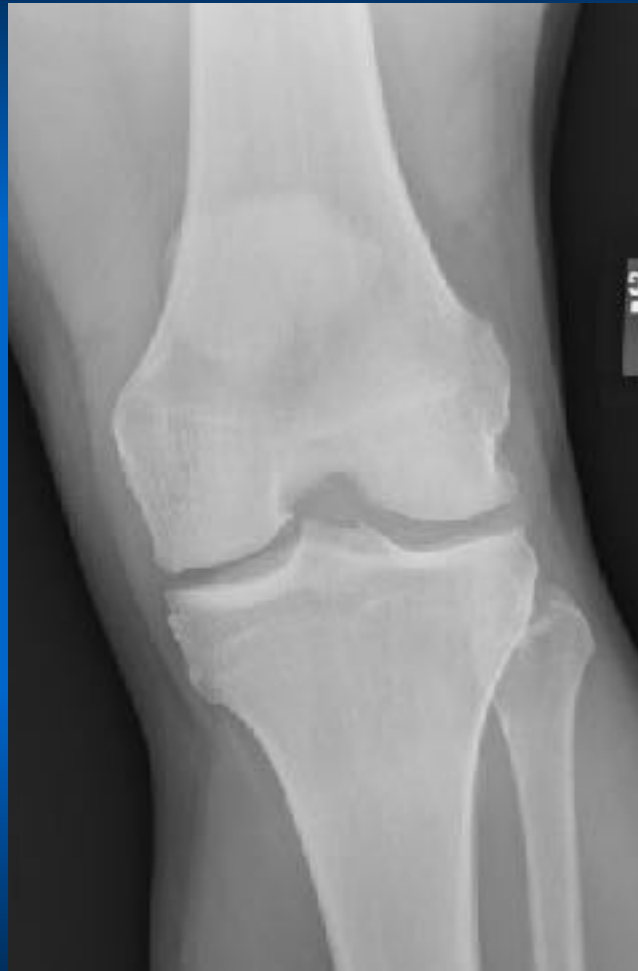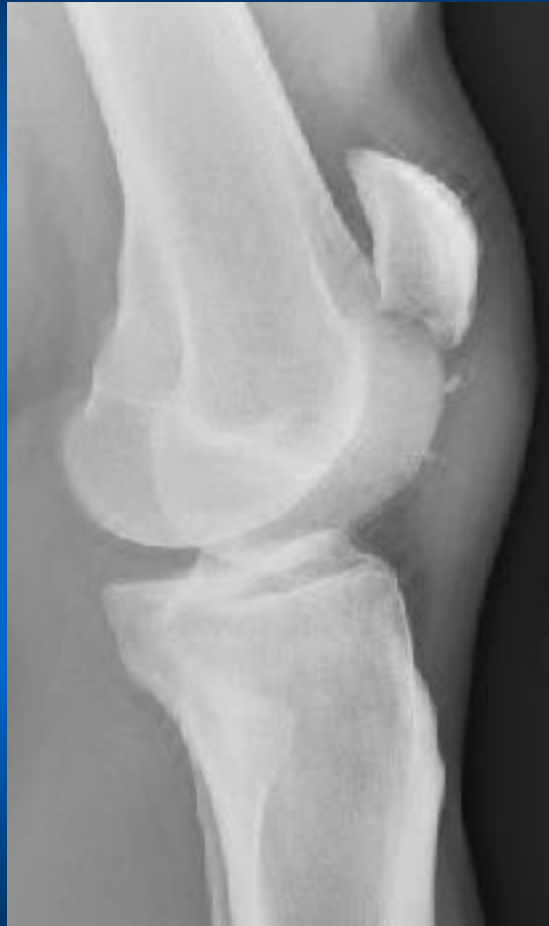- Fluoroquinolones
  - Cipro (ciprofloxacin)
  - Floxin (ofloxacin)
  - Avelox (moxifloxacin HCL)
  - Noroxin (norfloxacin)
  - Factive (gemifloxacin mesylate)
  - Levaquin (levofloxacin)
  - Cipro XR and Proquin XR
- Statins for lowering cholesterol
  - Lipitor
  - Zocor
  - Crestor

PubMed Search (11/17/2009): 58 references to Drug-Induced Tendon Ruptures

## **42 YO Former NFL Offensive Center**

**Injured left knee playing basketball:**

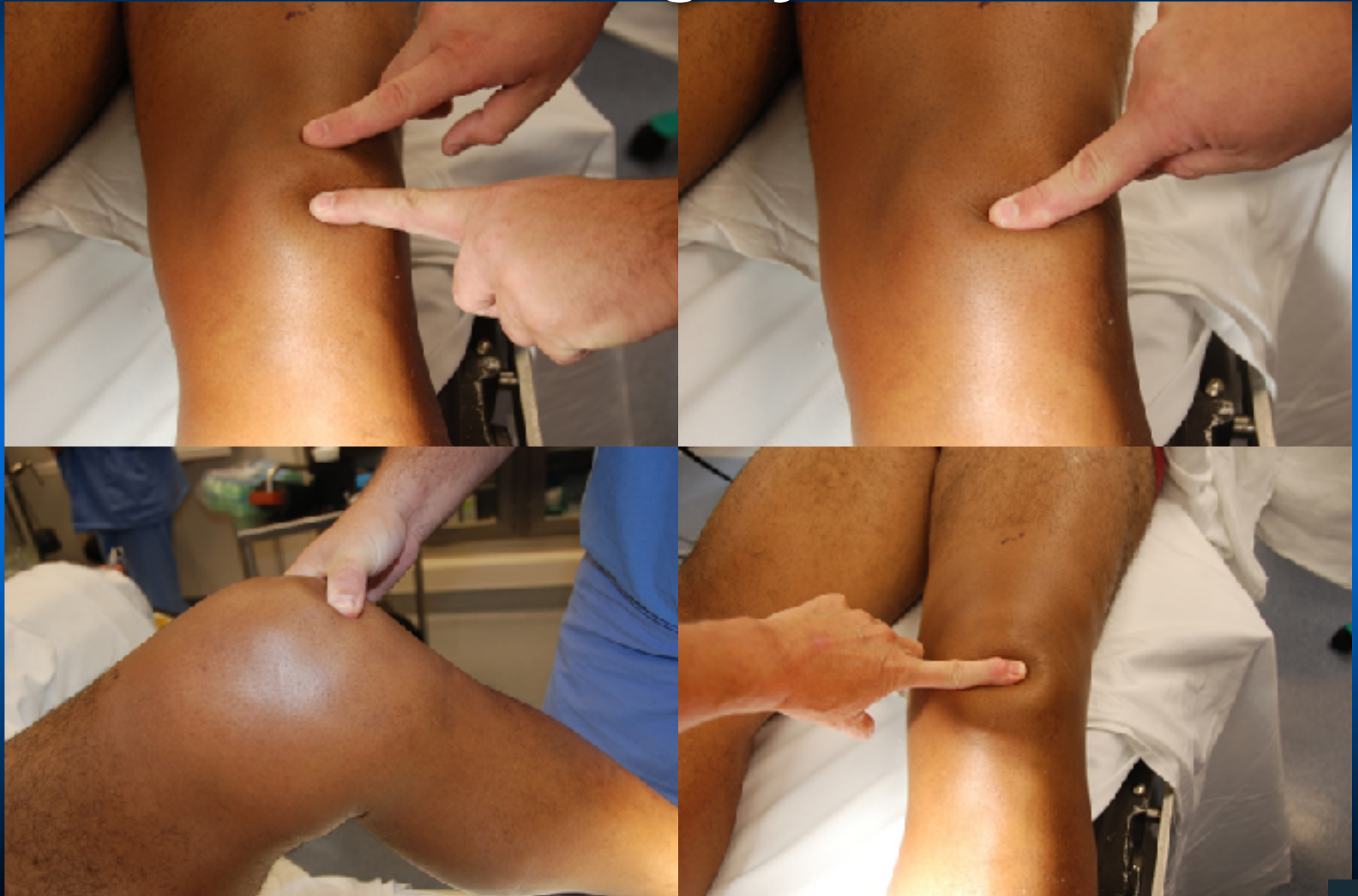- **Acute pain**
- **Inability to extend knee**
- **PE**
- **Consistent with complete patellar tendon rupture:**
  - **Radiographs show high position of the patella**
  - **Palpable defect in patellar tendon**
- **Patient opted for surgical patella repair**



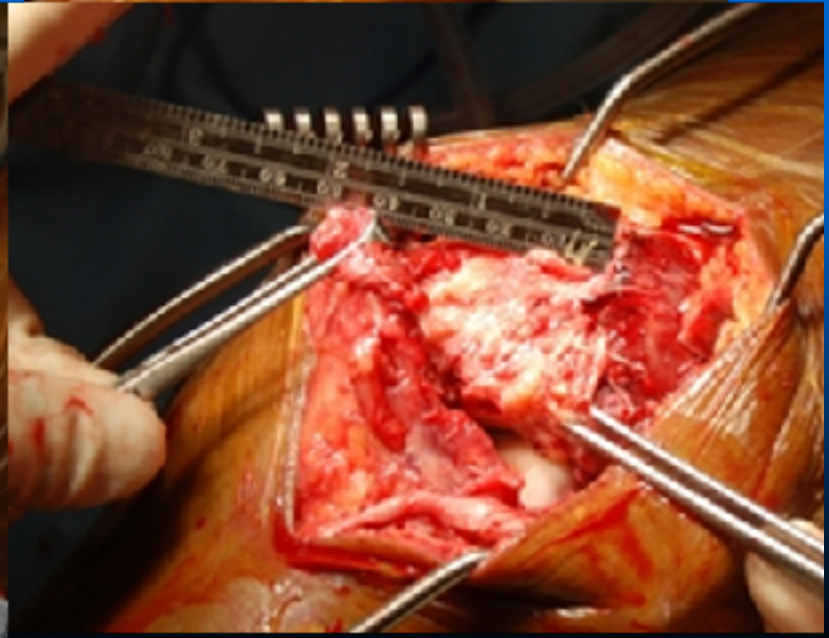
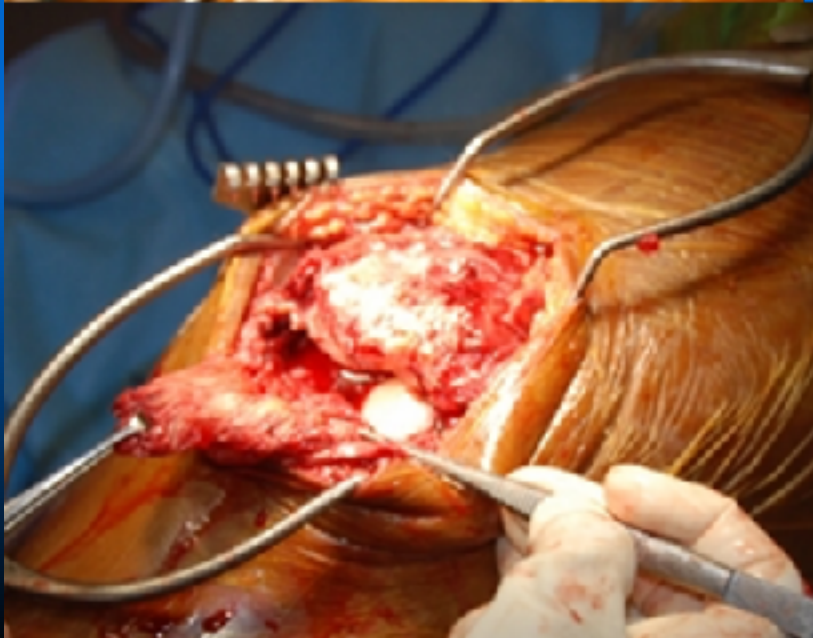
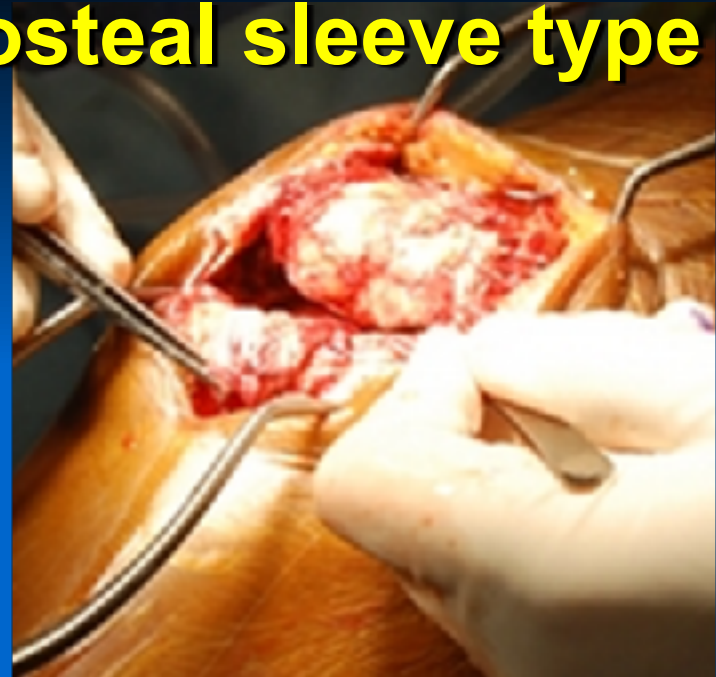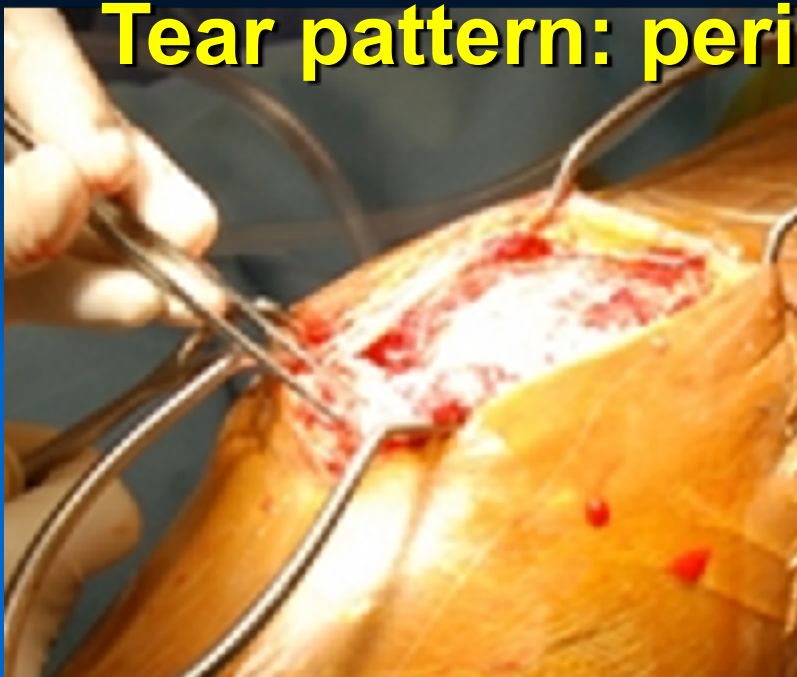**High-riding patella = patella tendon rupture**



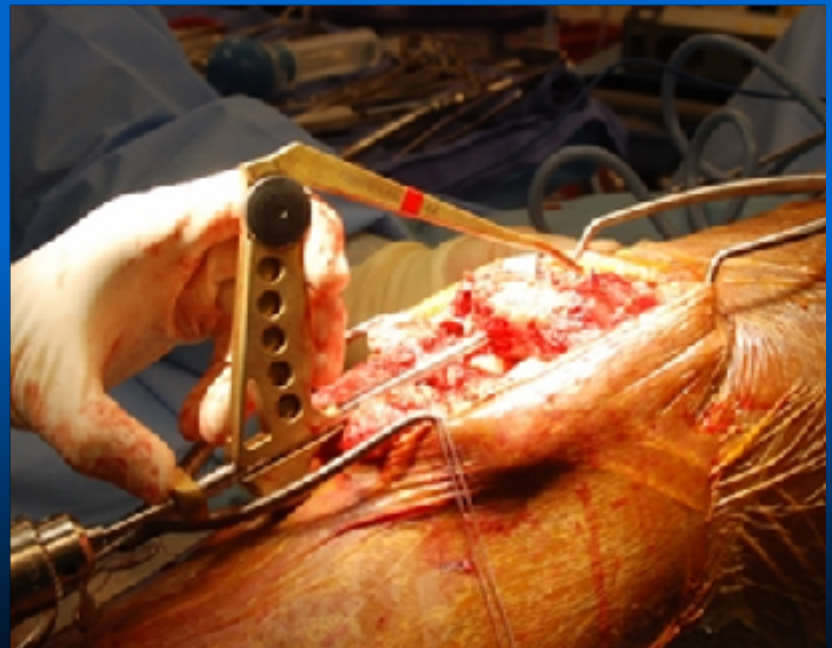
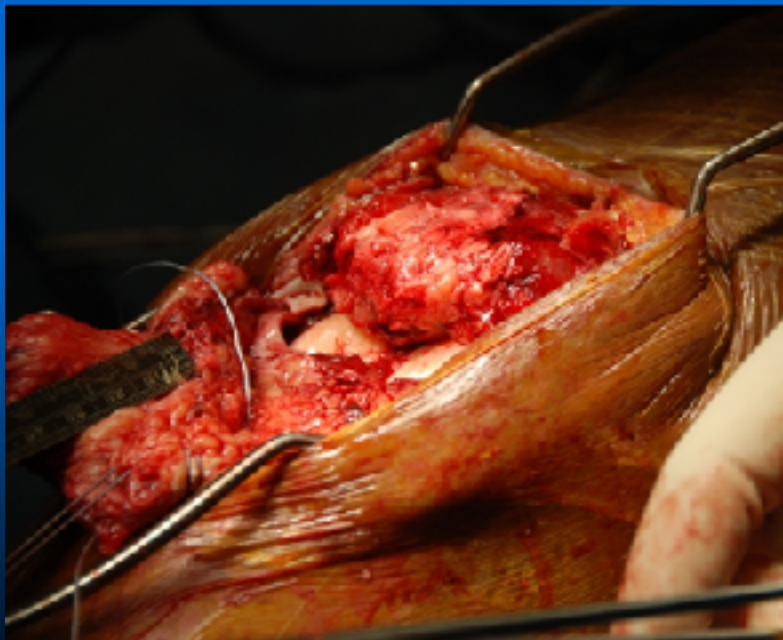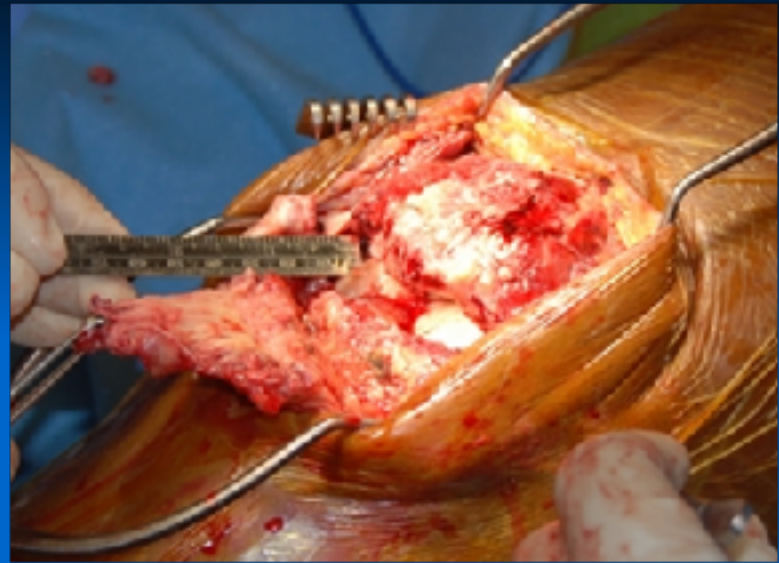
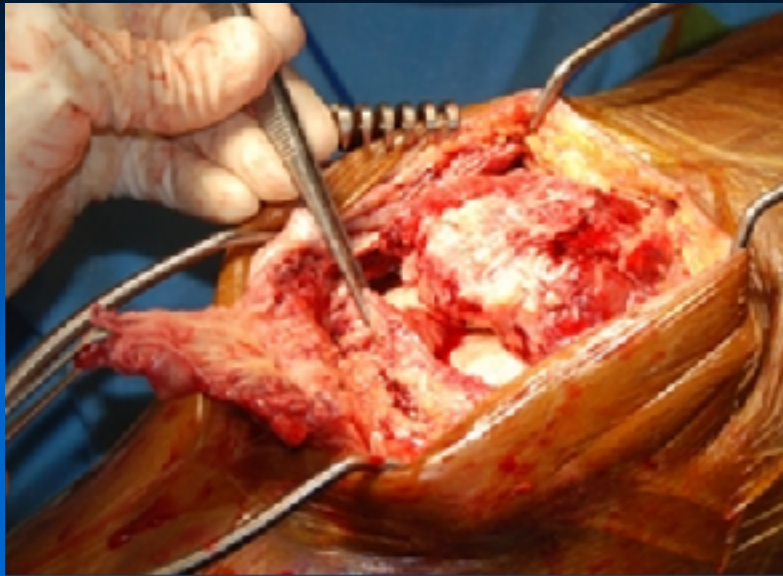
# Surgery

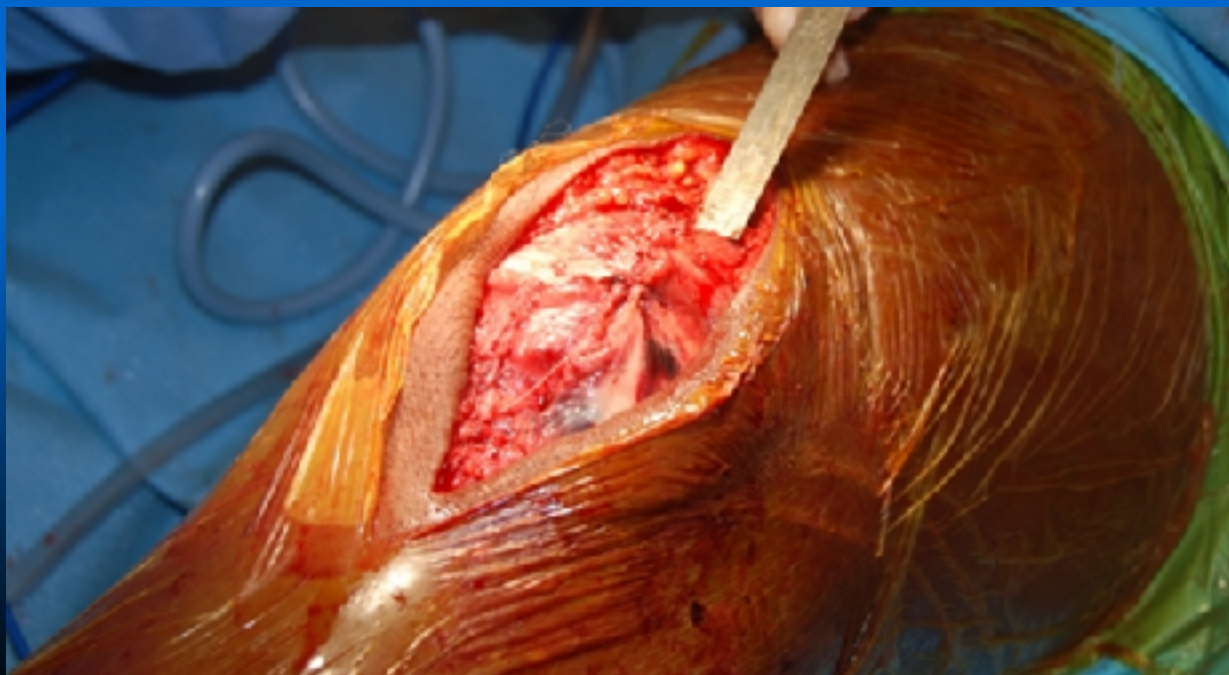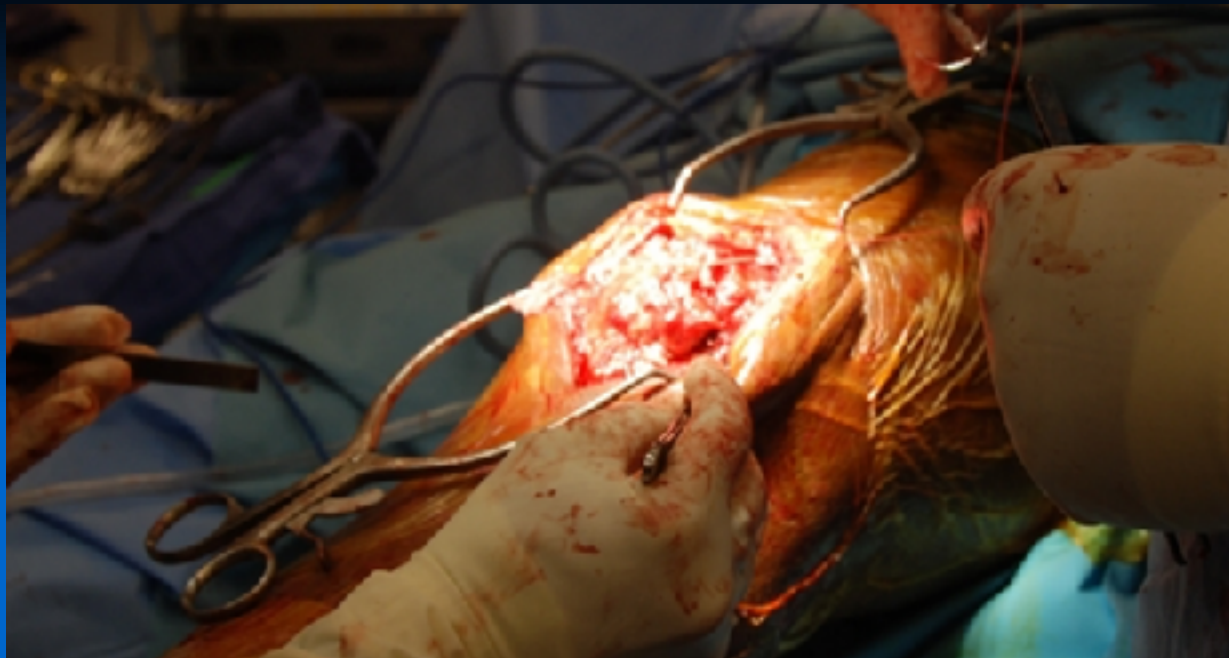


# Tear pattern: periosteal sleeve type












# 48 y.o. Female Ski Instructor Potter in Summer

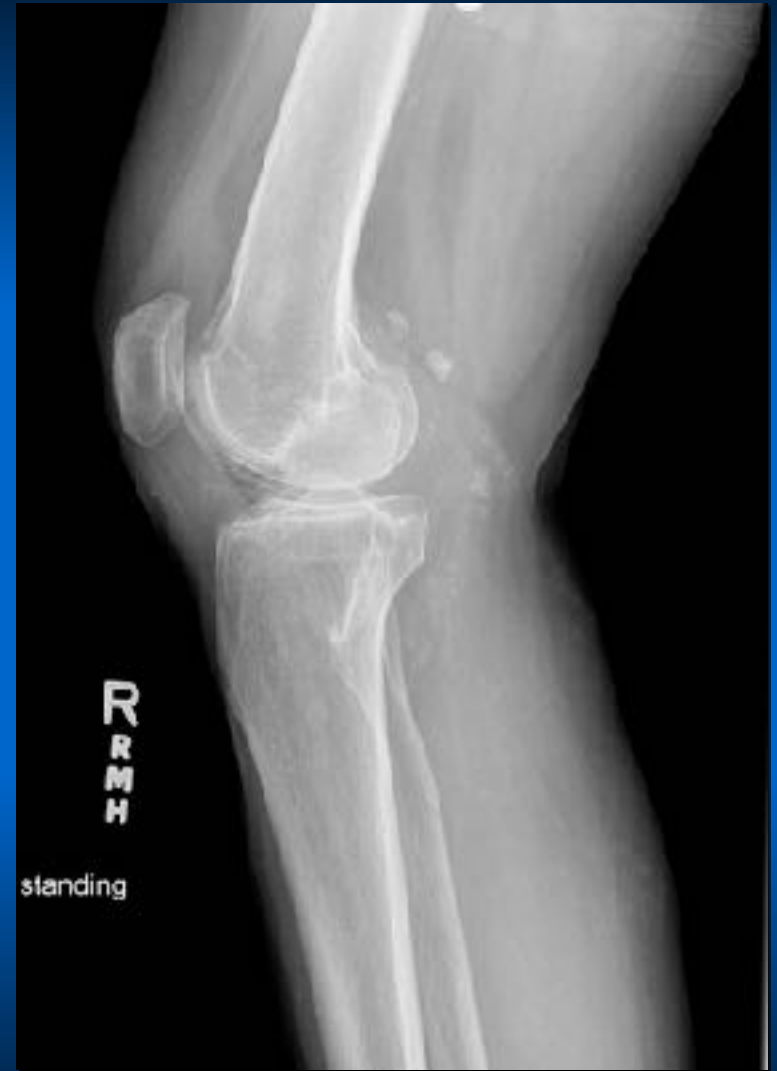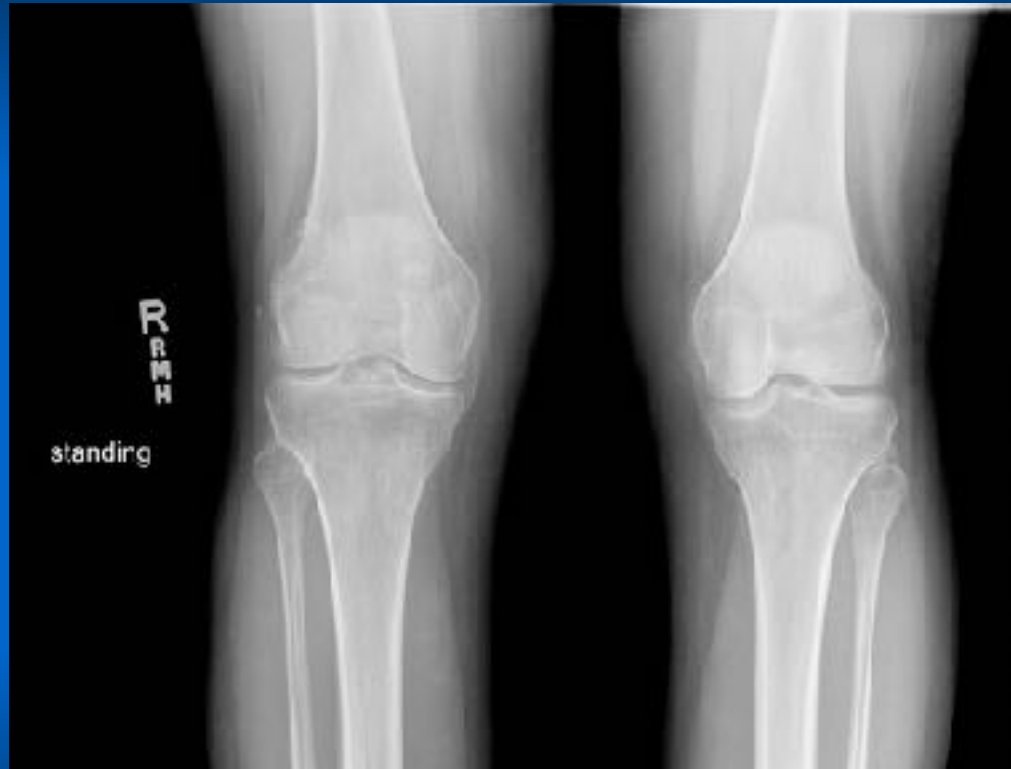- 6 Month History
- Atraumatic
- Swelling & Pain
- Occasional Locking
- Right Knee
- Lacks Full Flexion
- 1+ Effusion

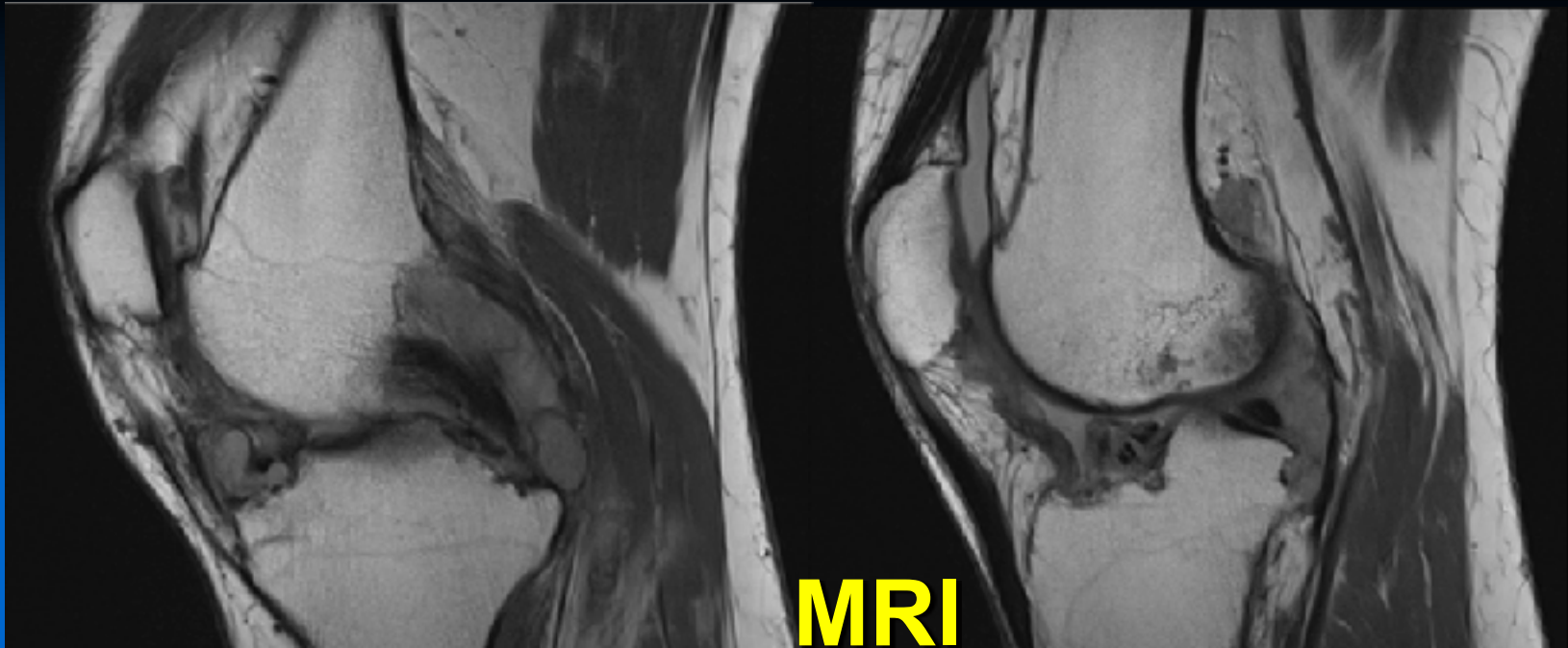


Courtesy of Daniel C. Wascher, M.D.

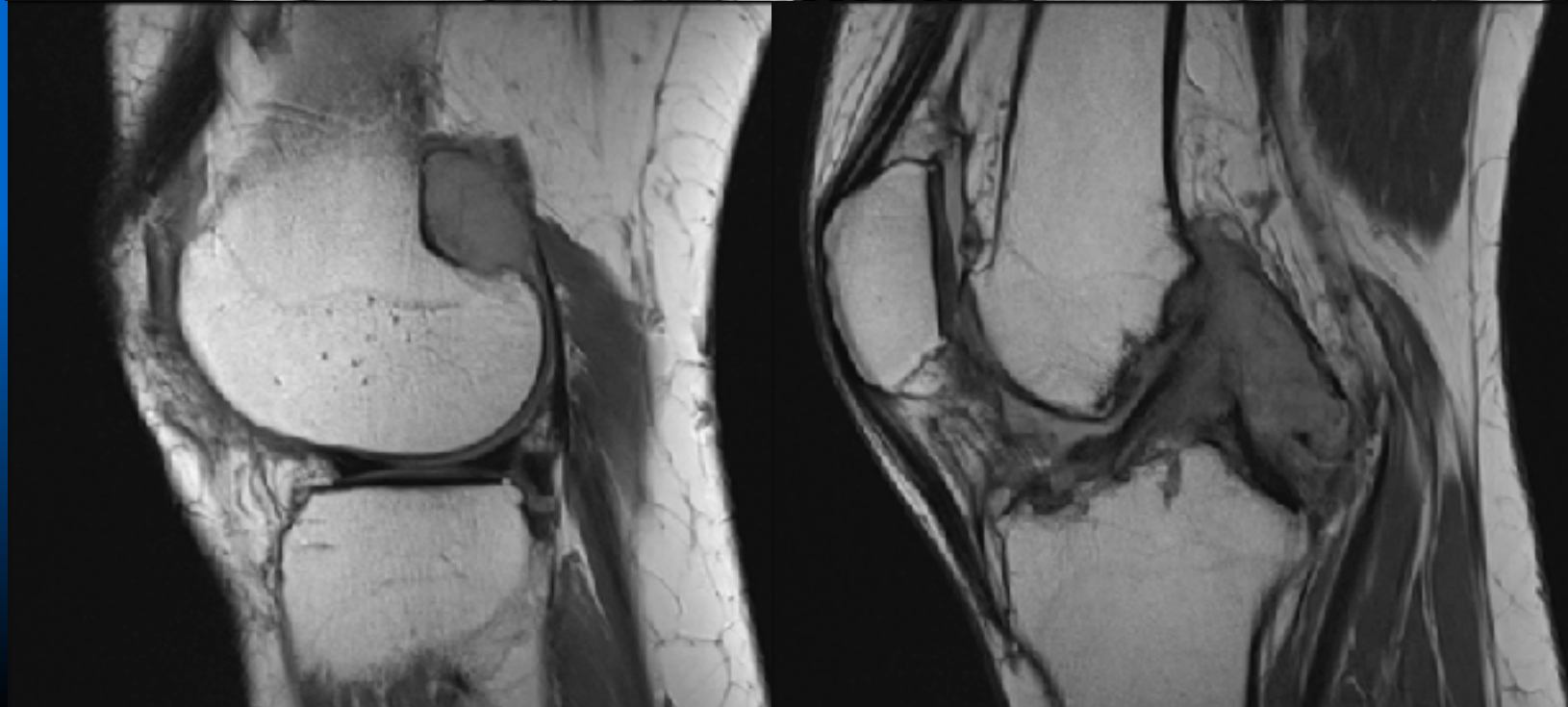


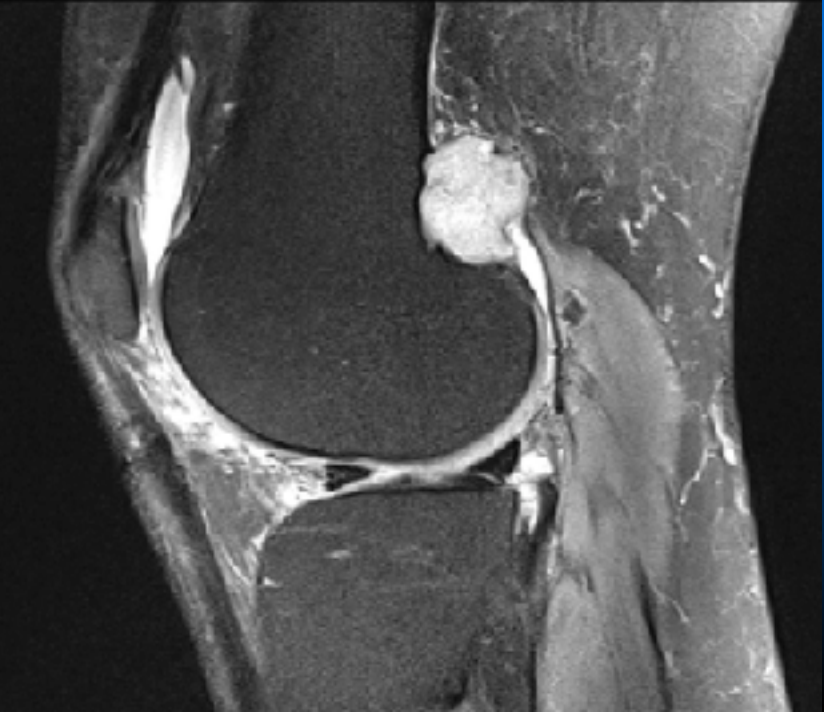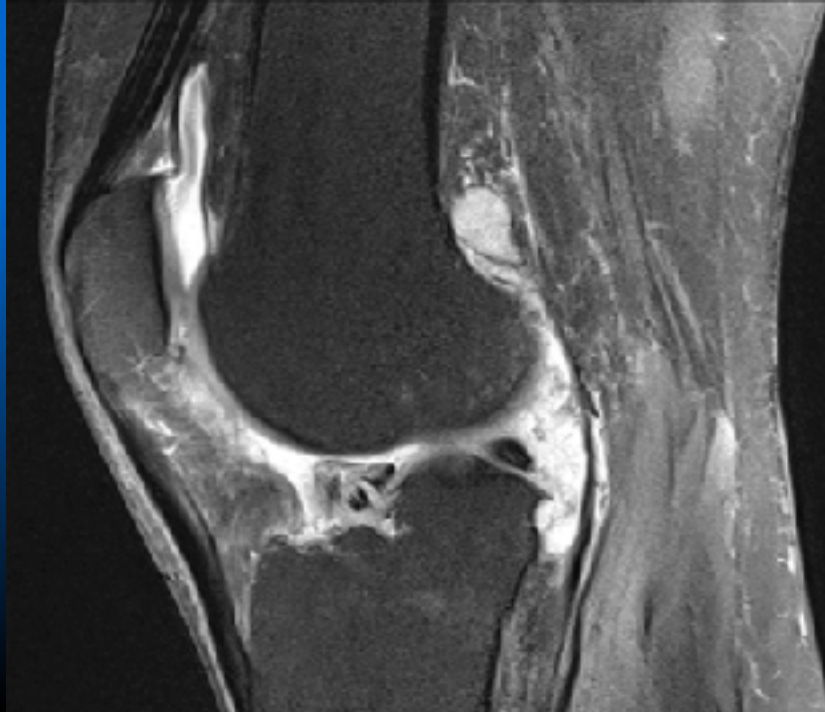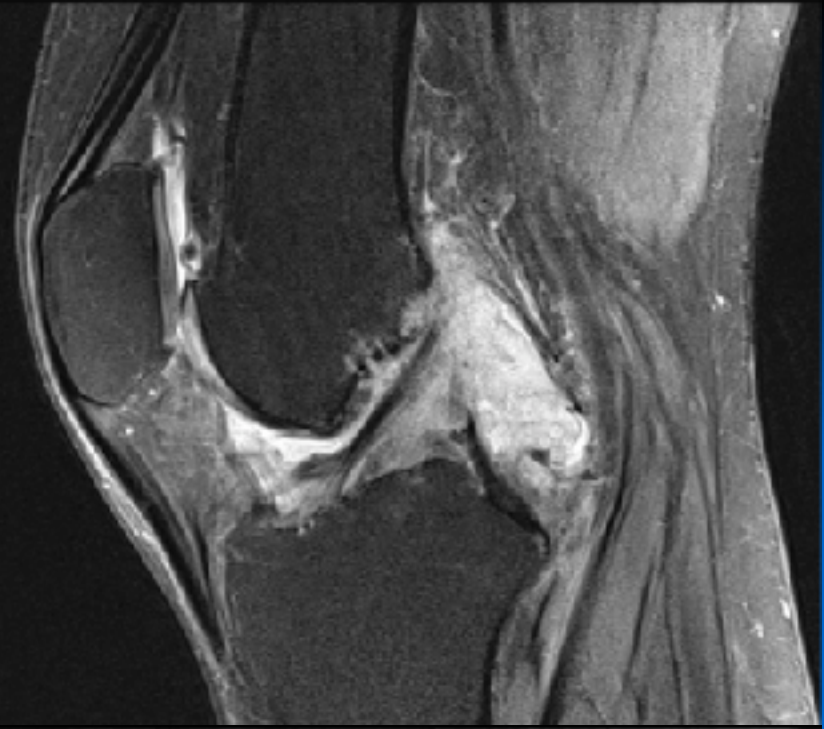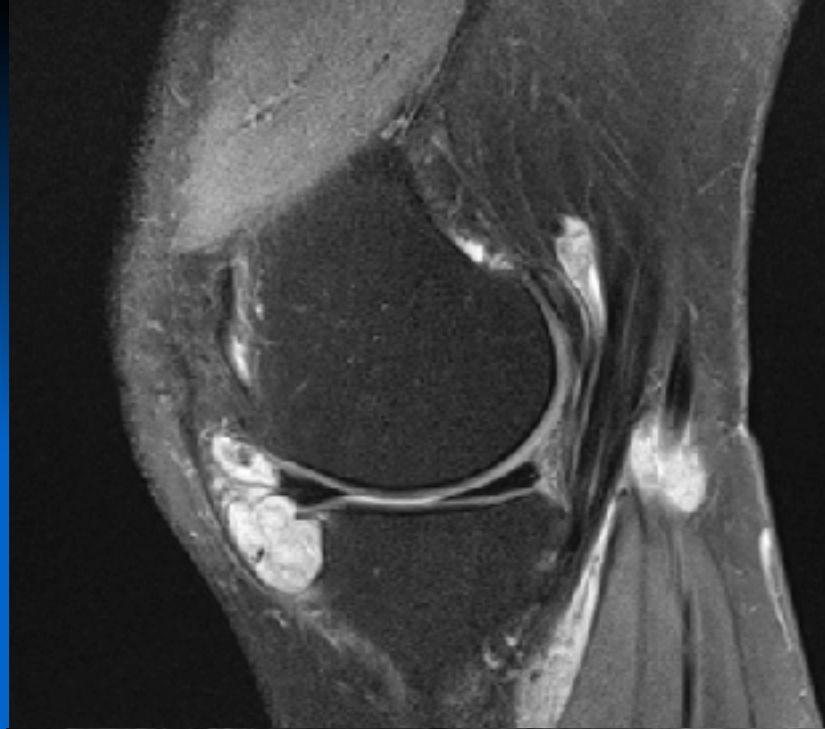
# Radiographs



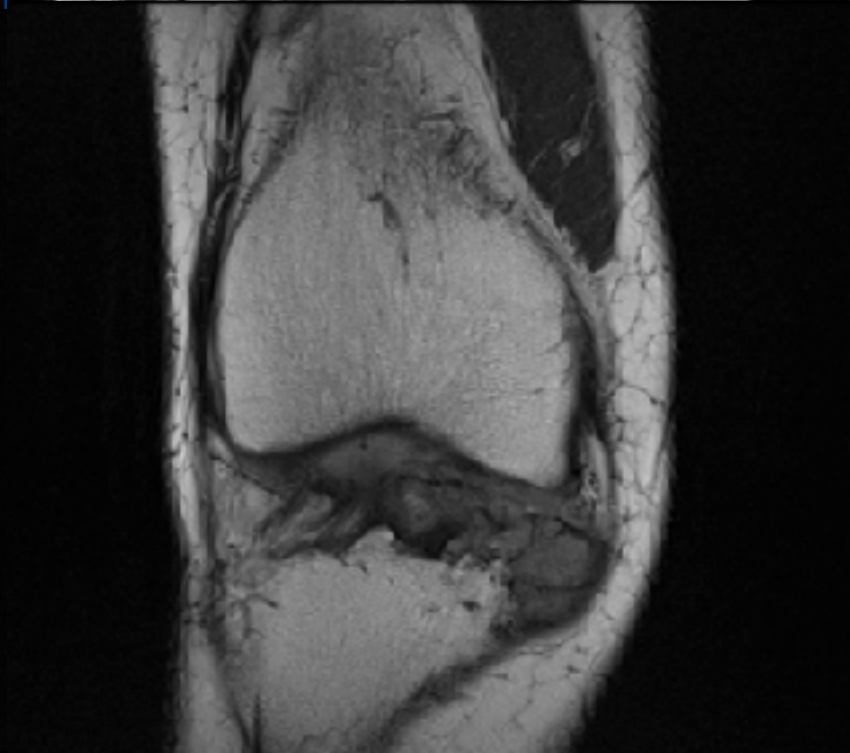
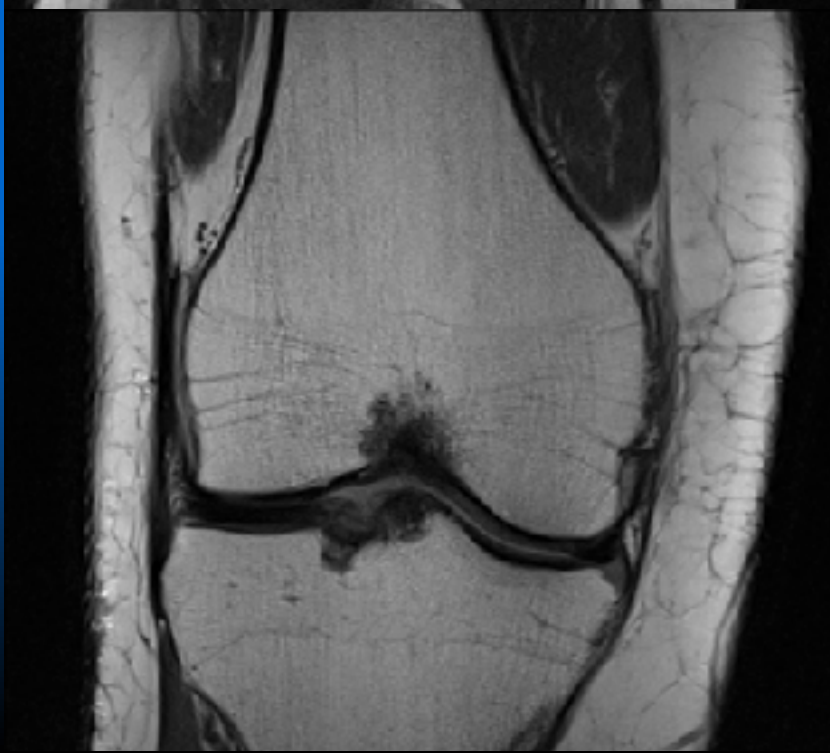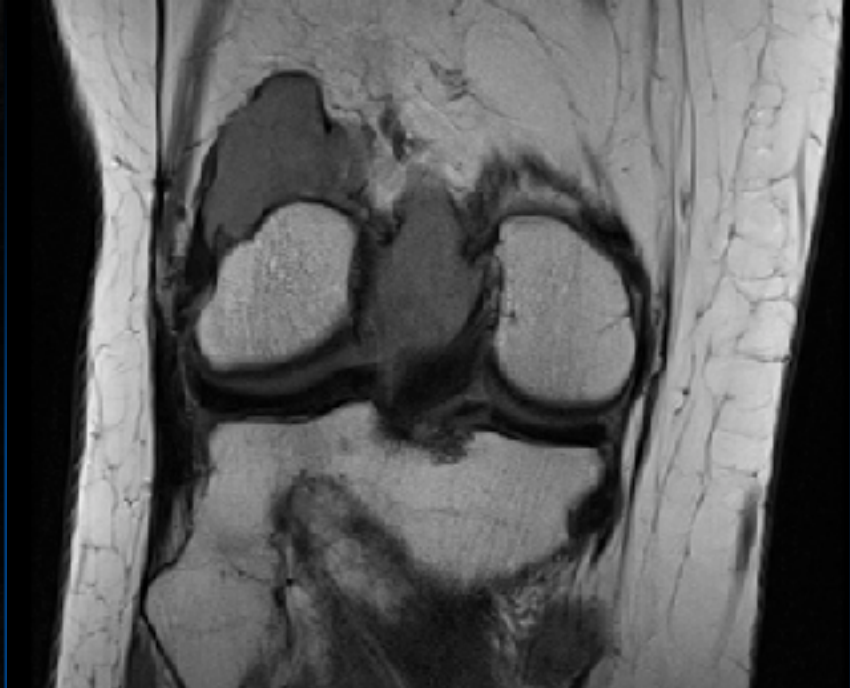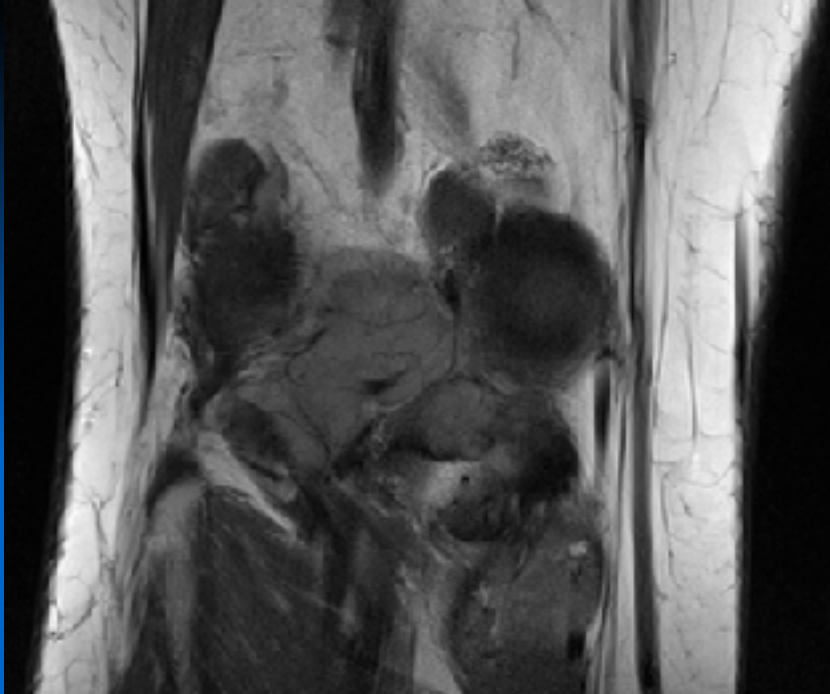


**MRI**







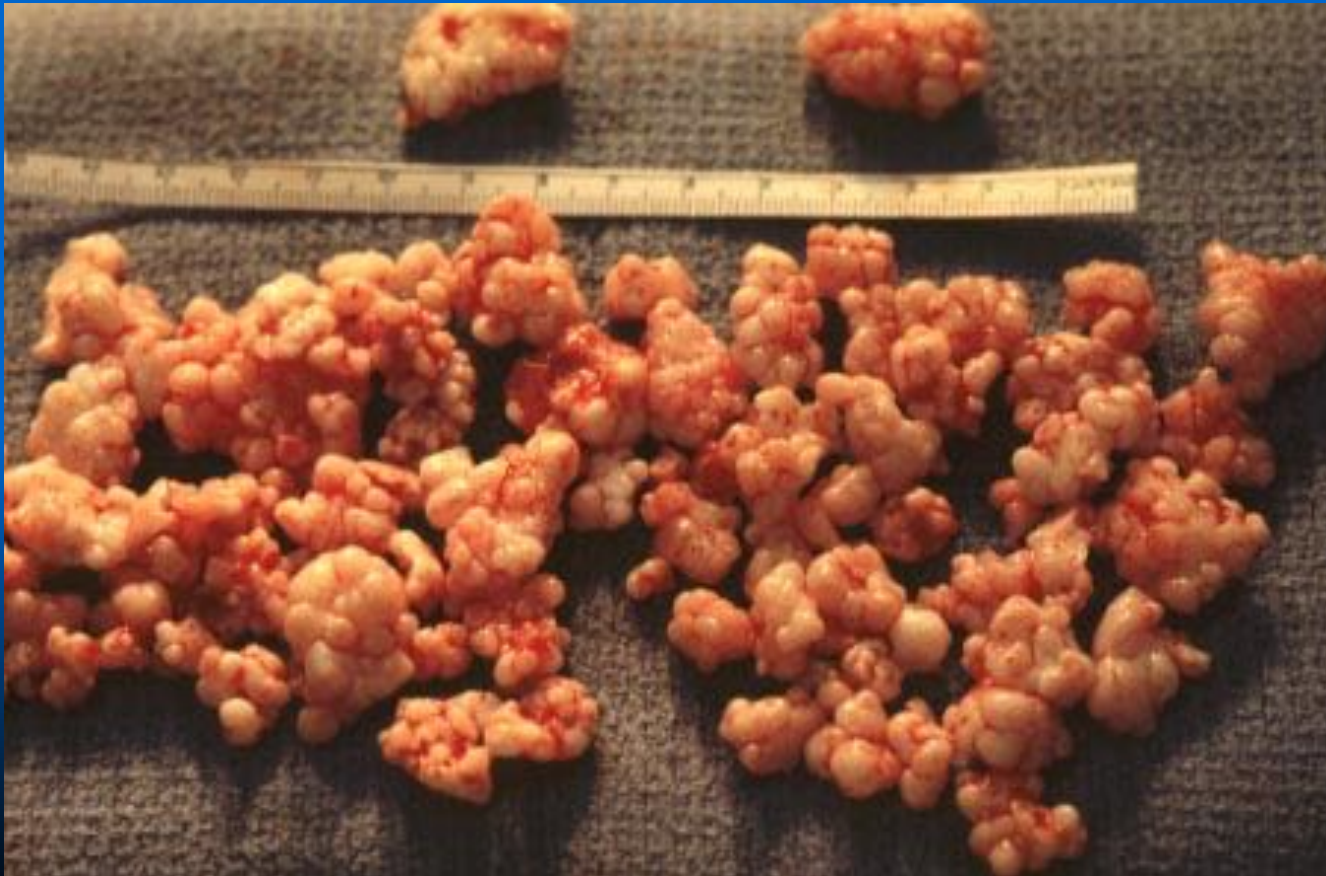


# Osteochondromatosis

Arthroscopic

Removal of Loose Bodies

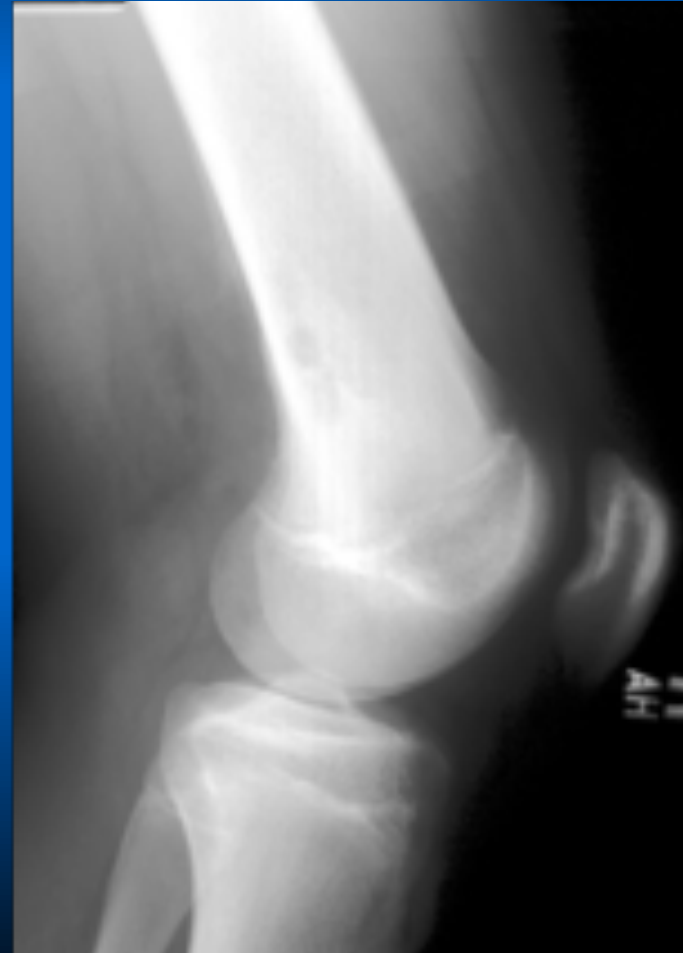
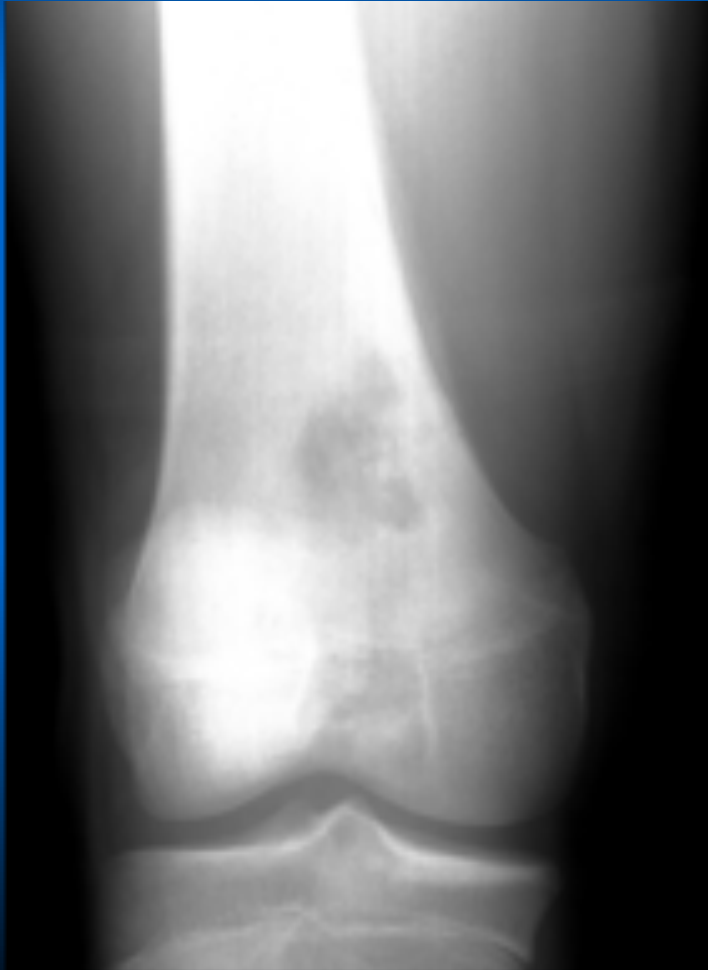Returned to Activity



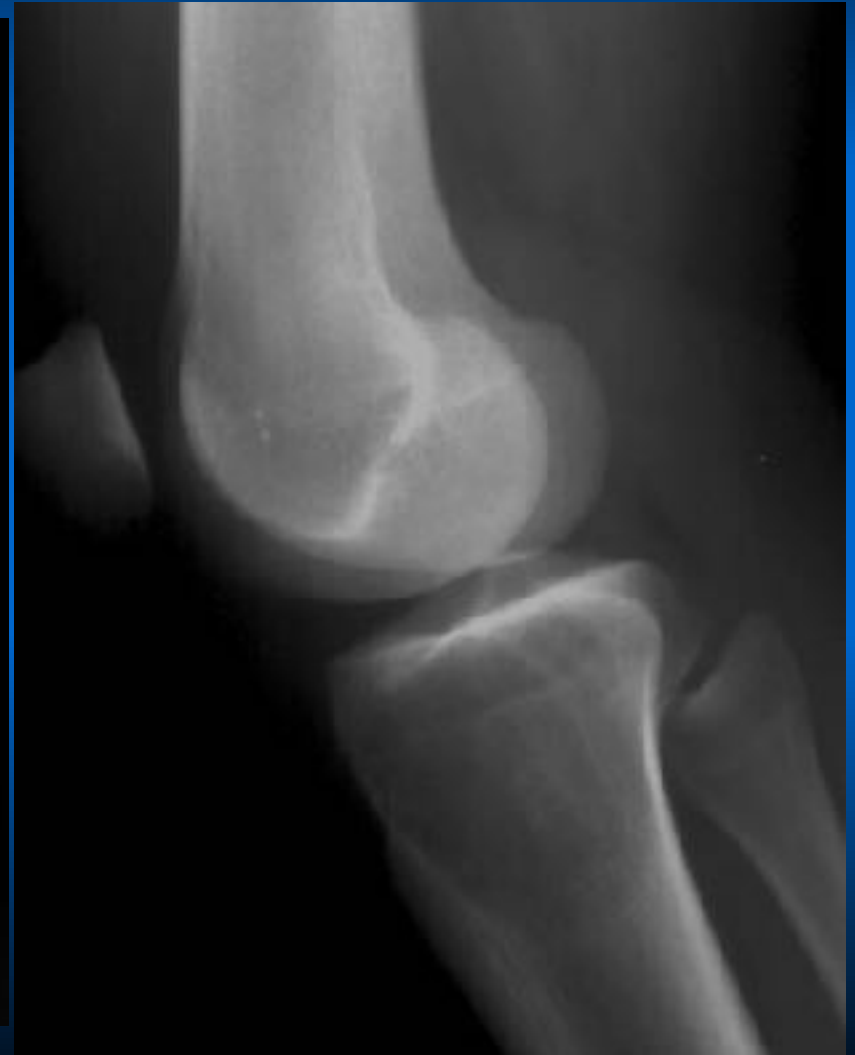
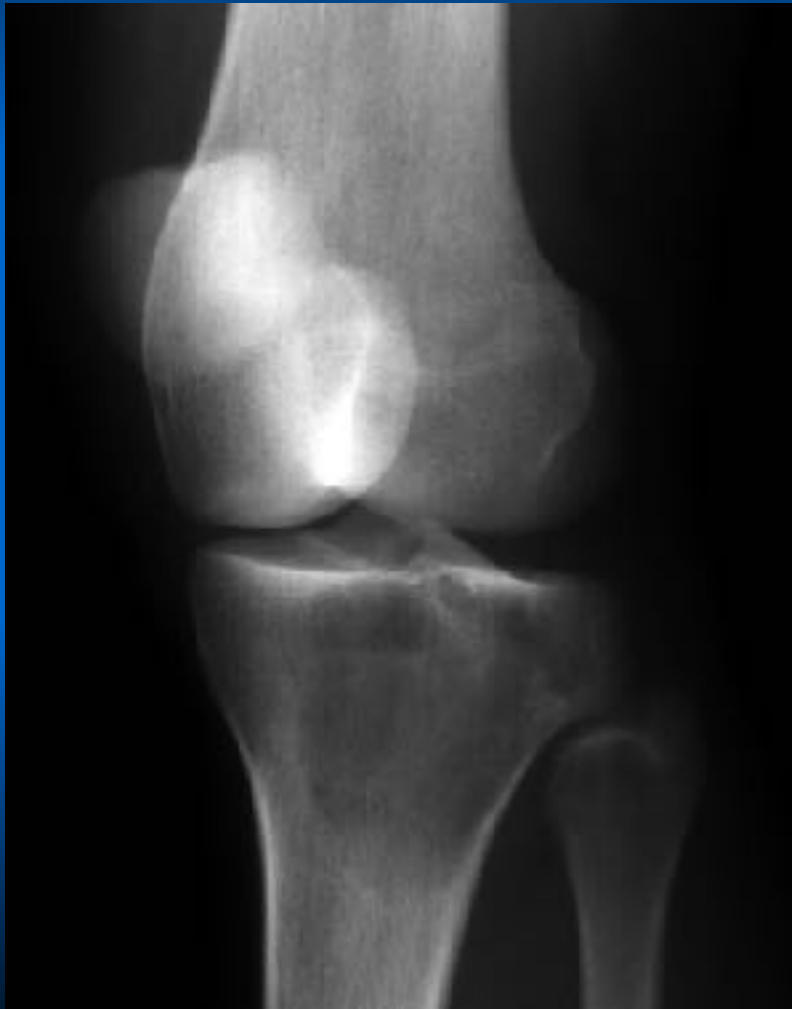
**15 YO BM**

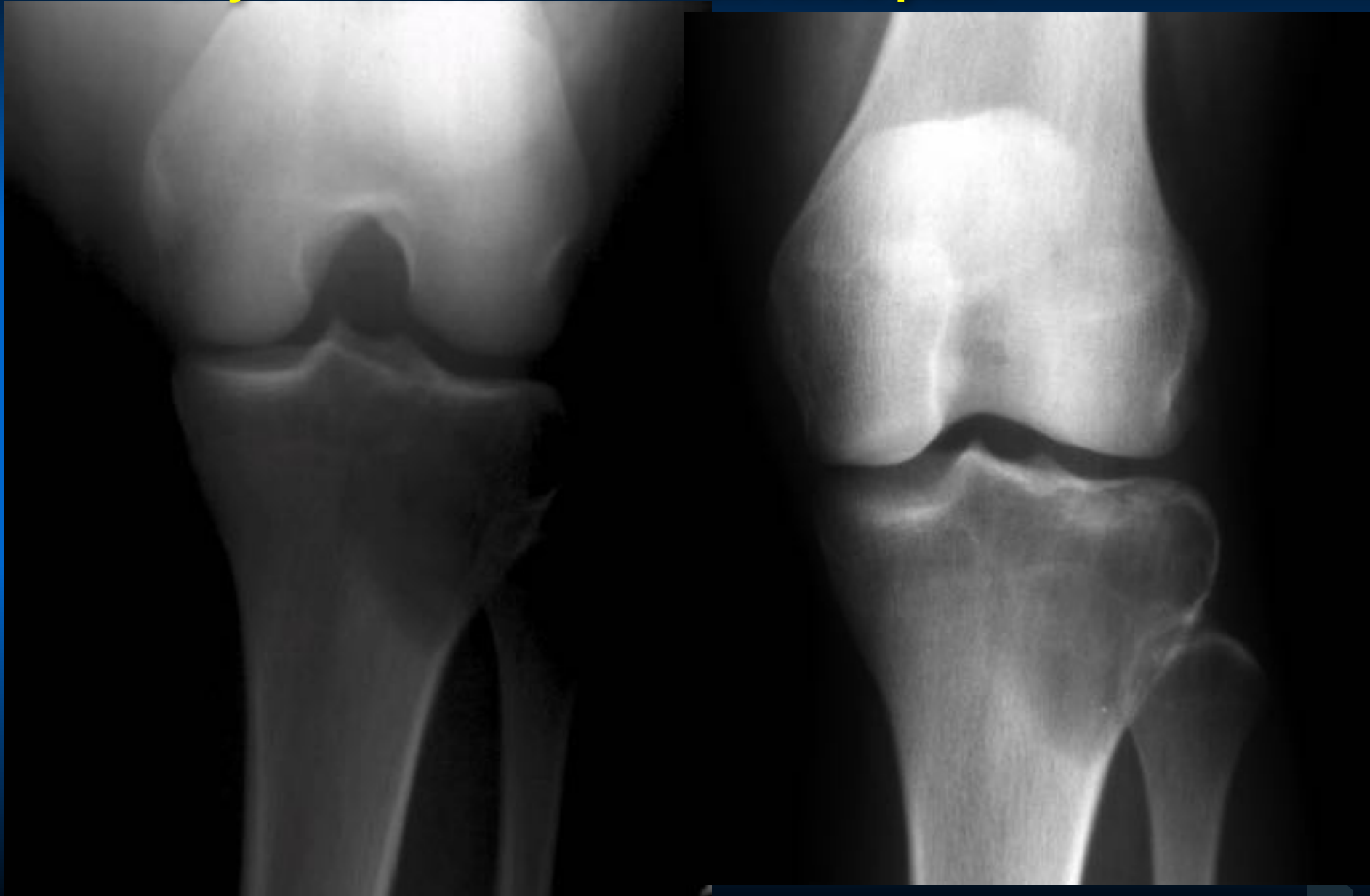
Destructive lesion distal femur,  
biopsy showed osteosarcoma.



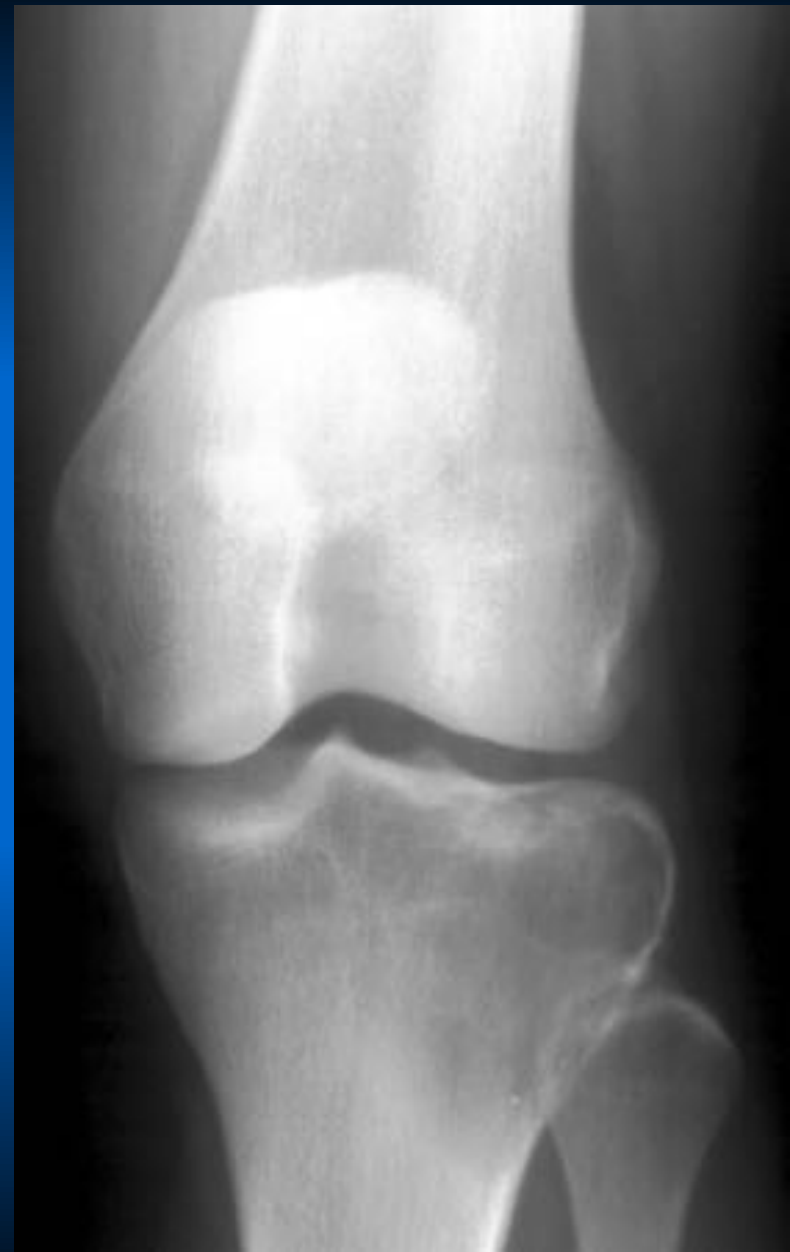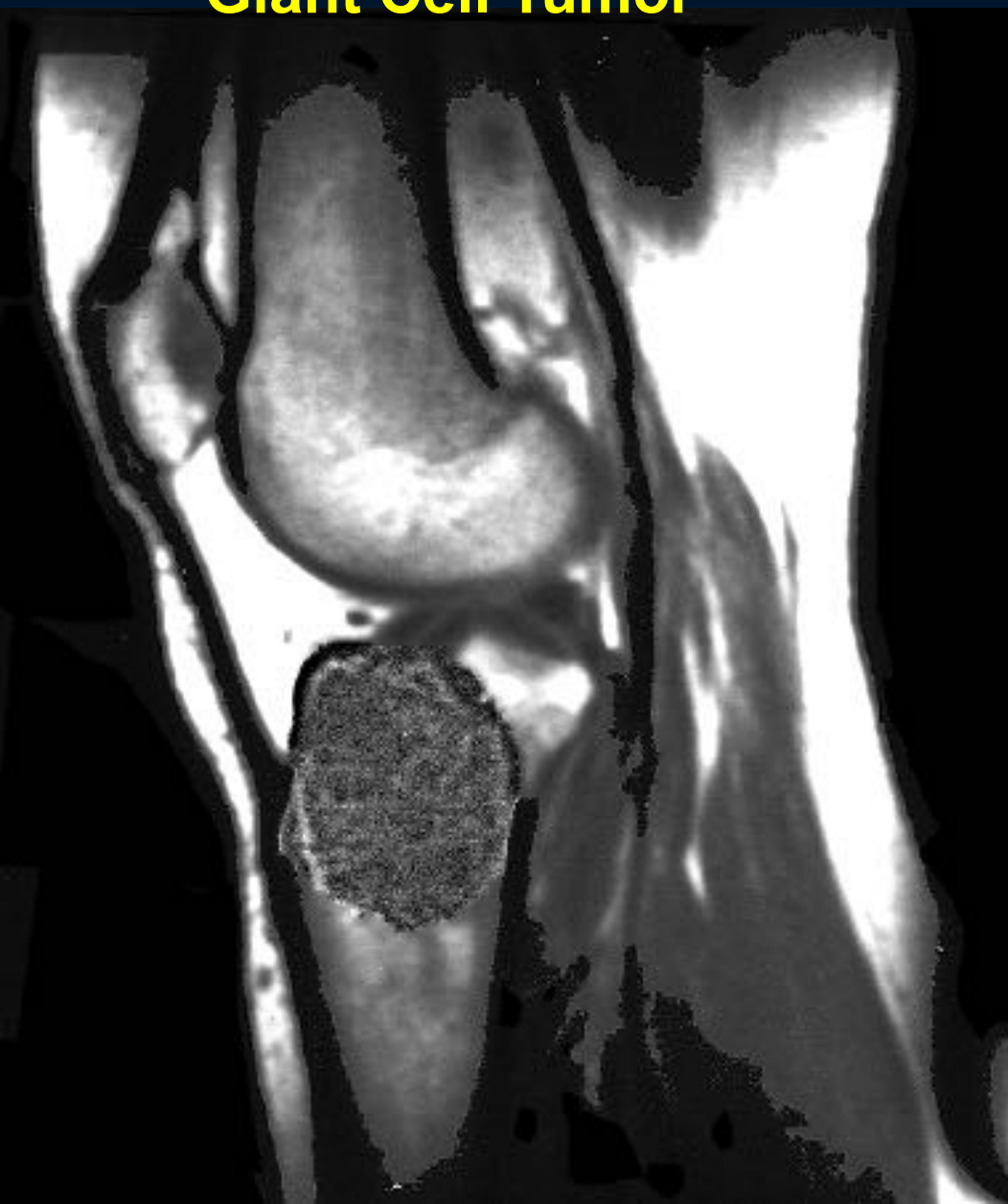## 30 yo Insidious Onset Left Knee pain

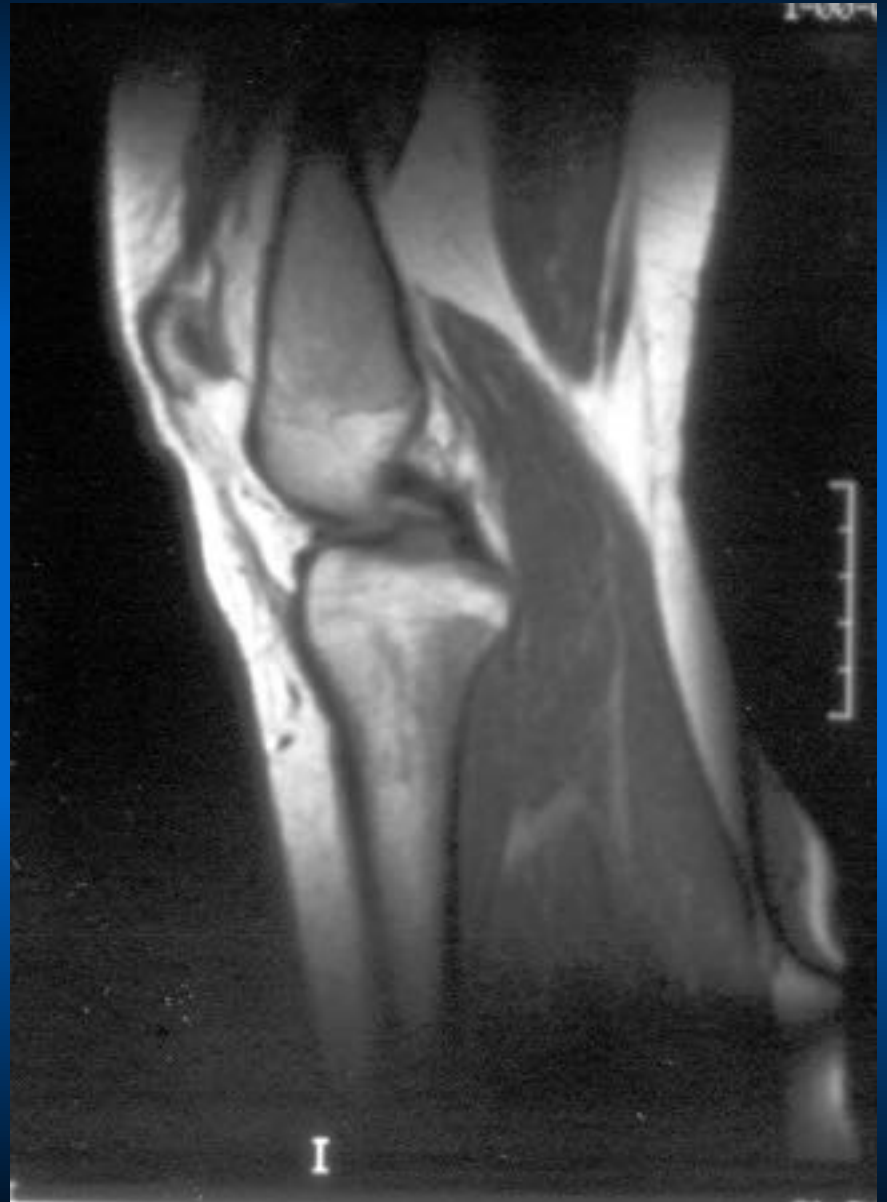
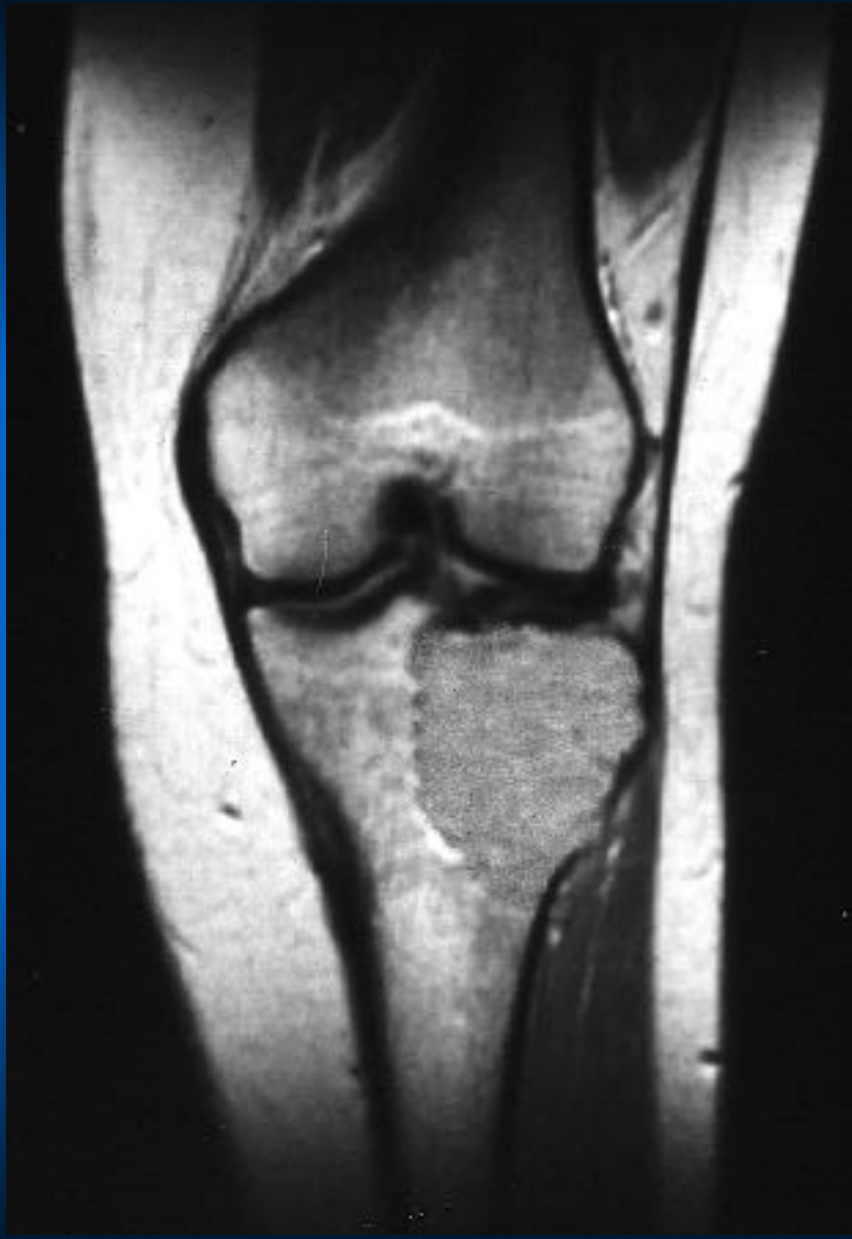
## 30 yo Insidious Onset Left Knee pain



# Giant Cell Tumor

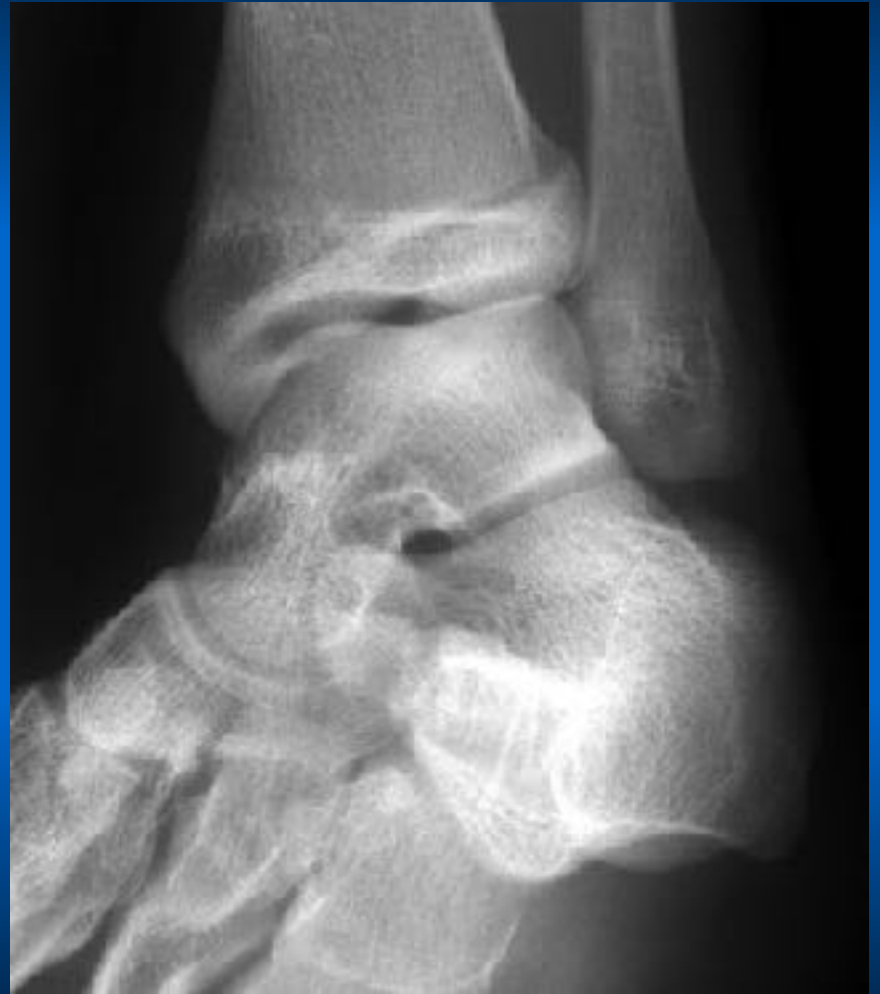


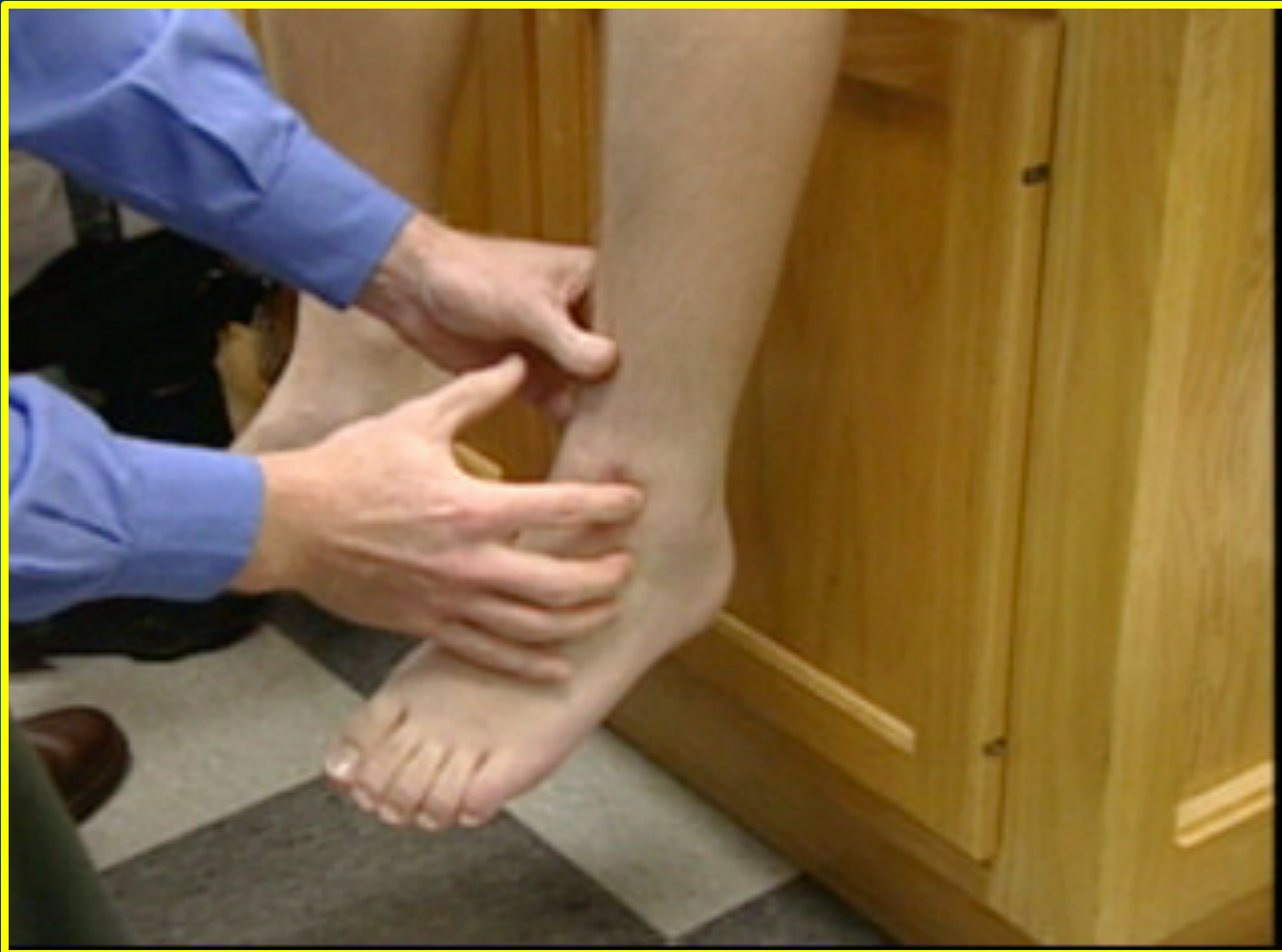


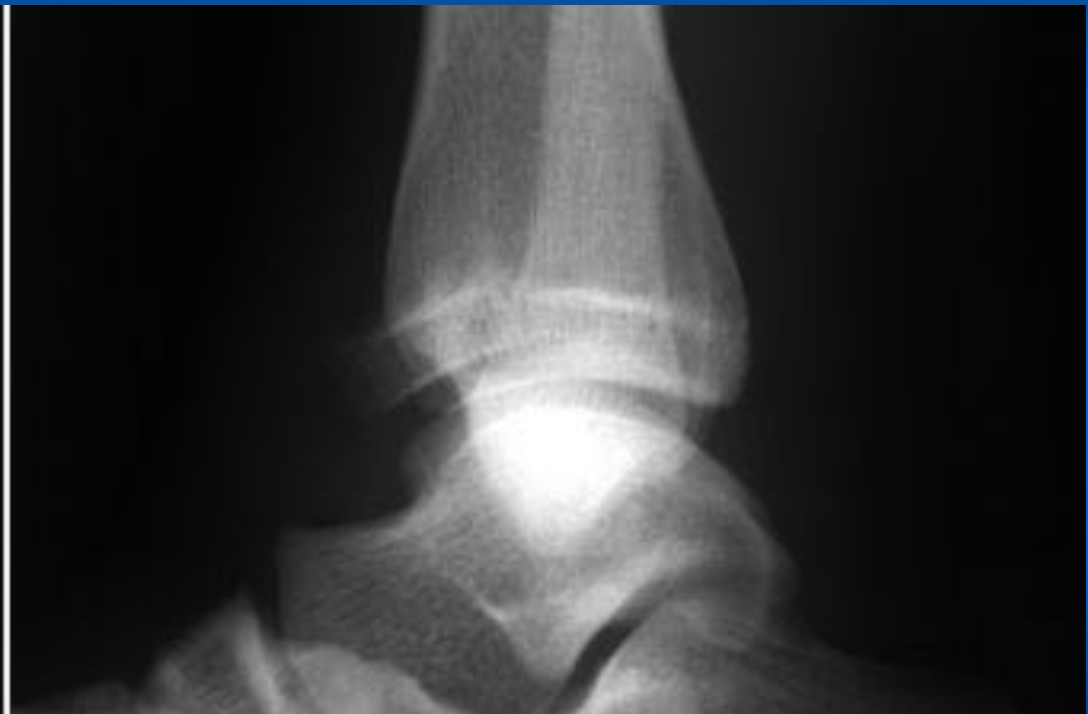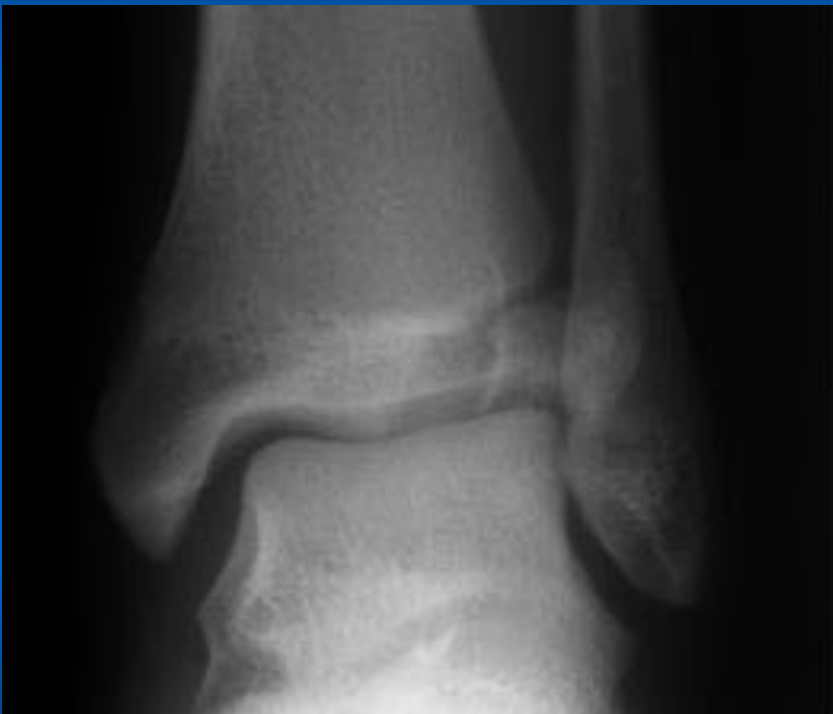# 14 YO Male

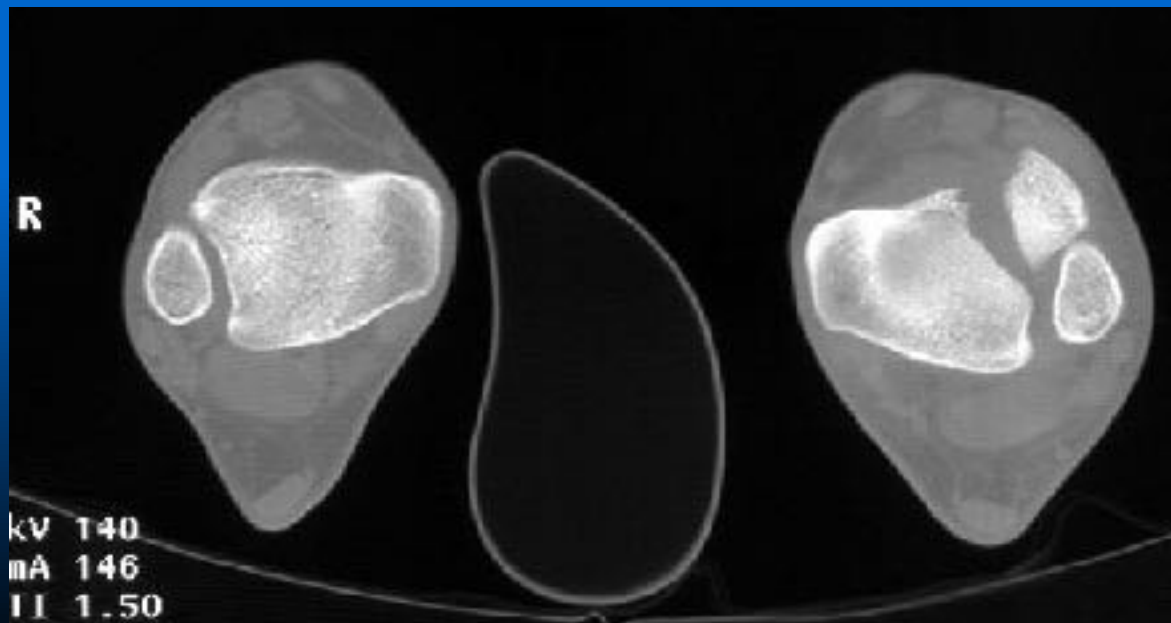
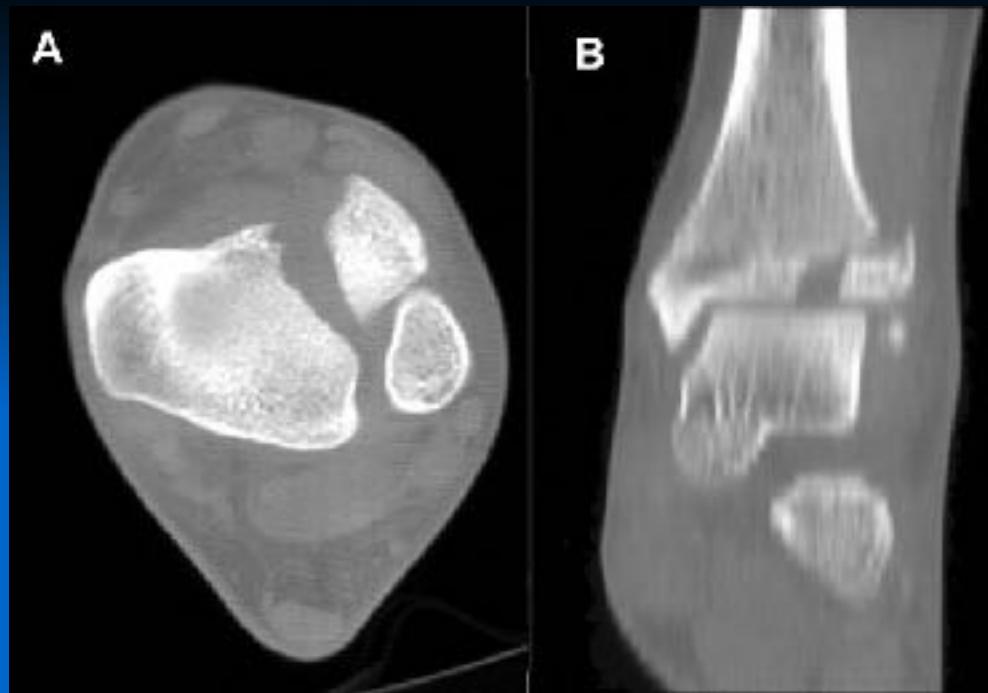
- Left ankle
- Tillaux fracture with displacement

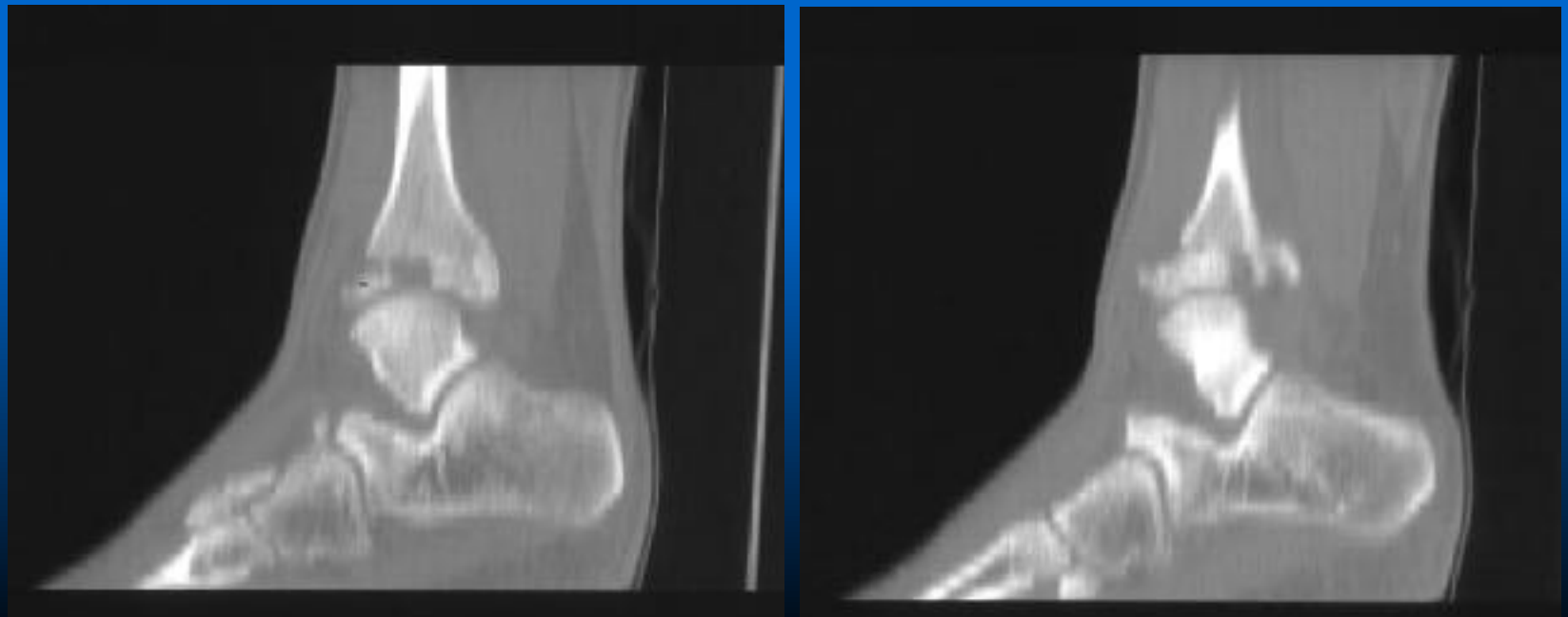
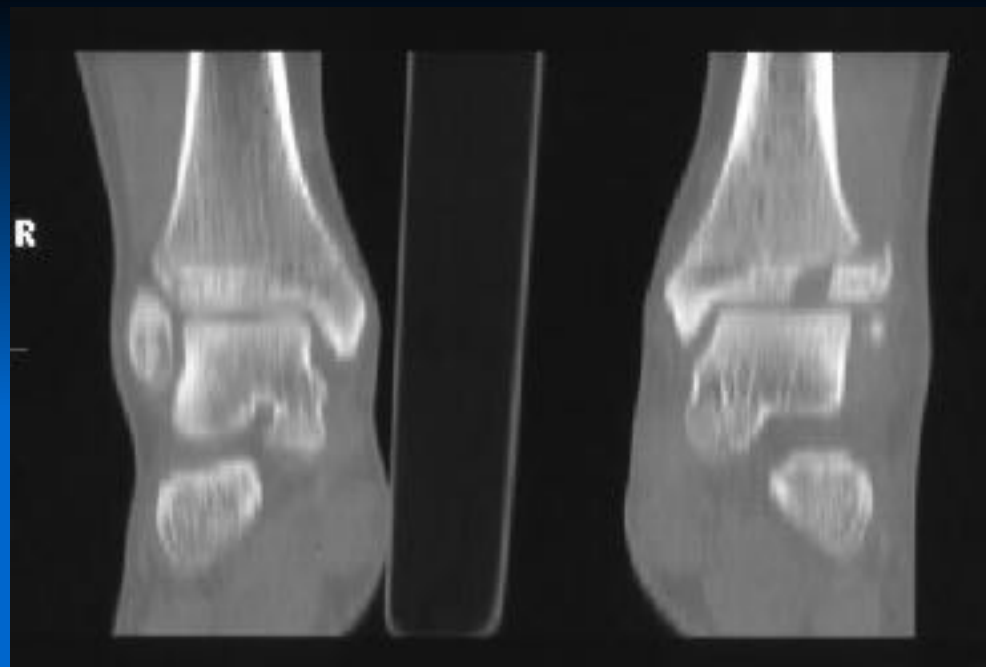




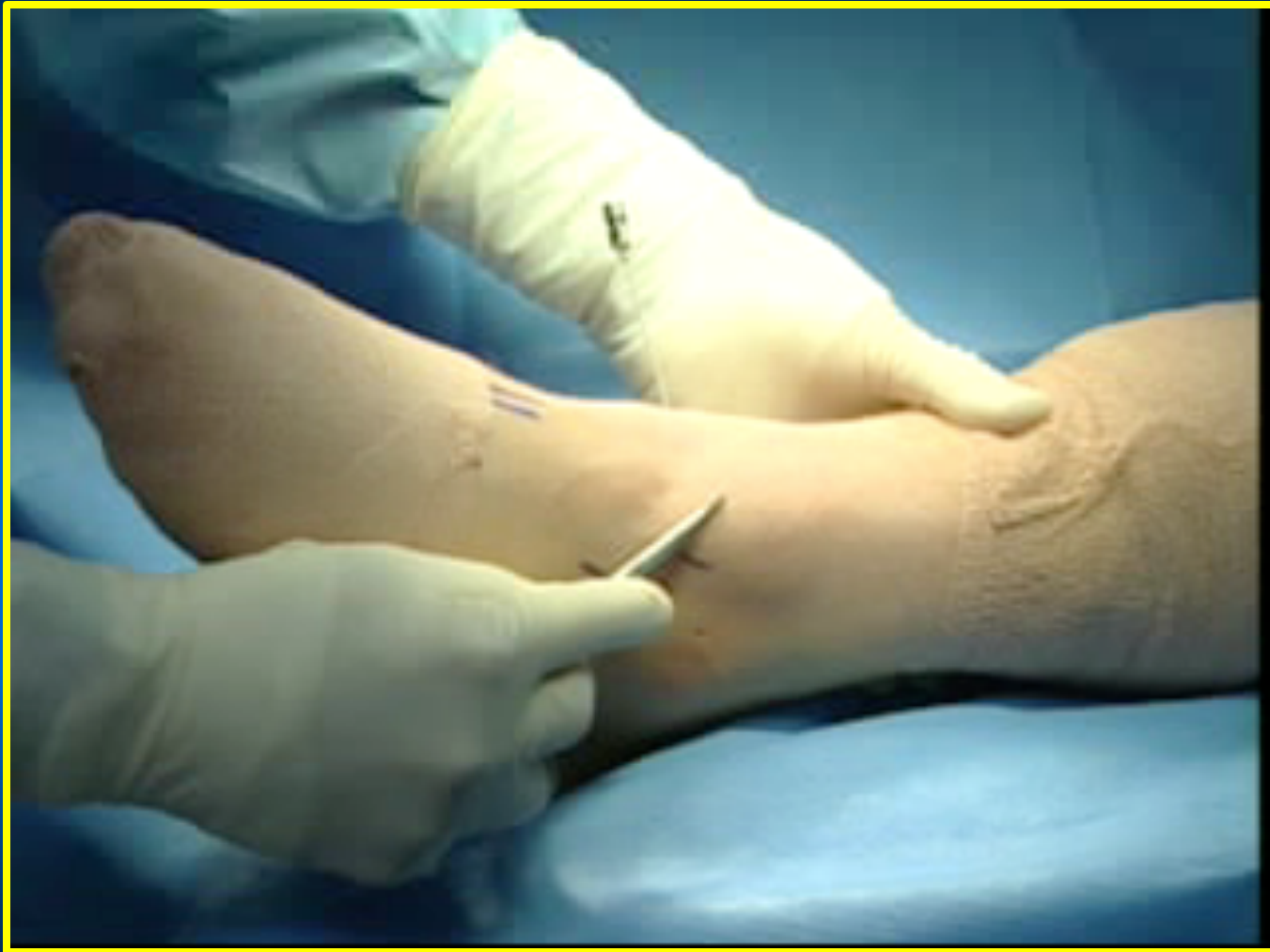
# CT Scan

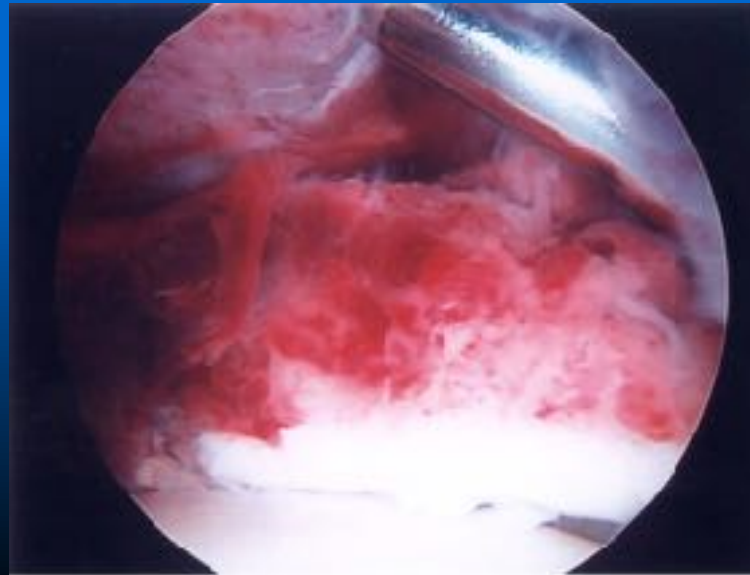
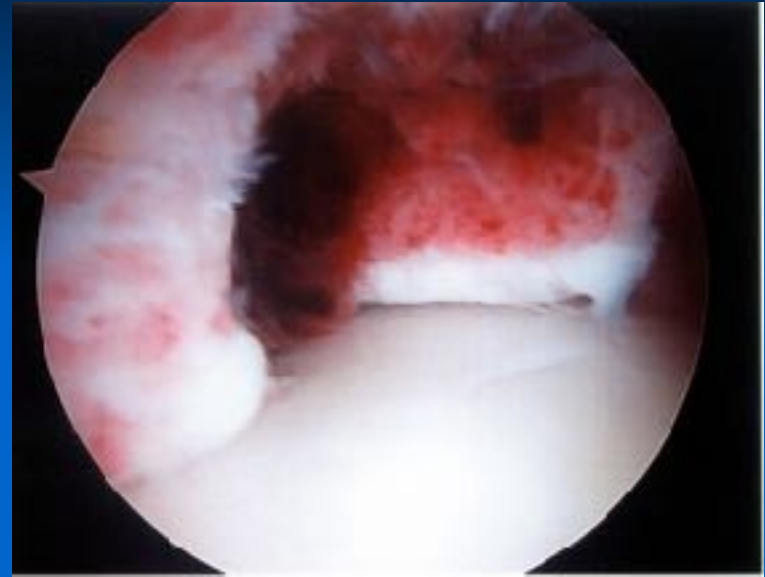
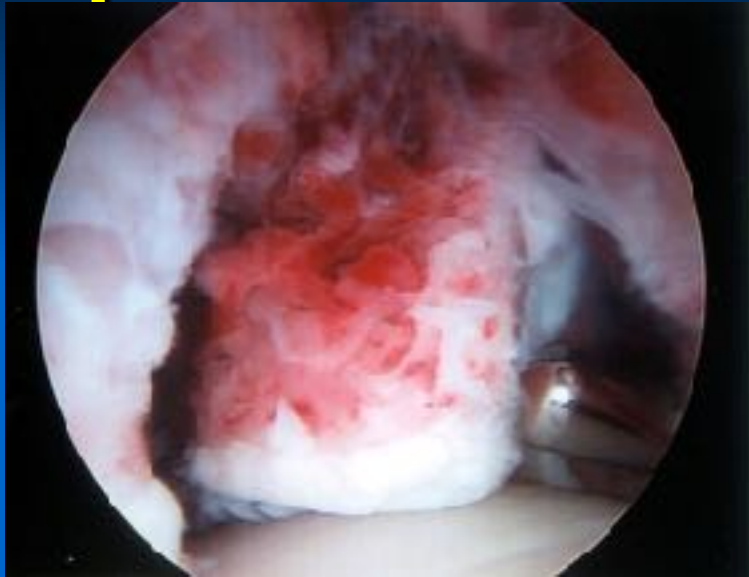




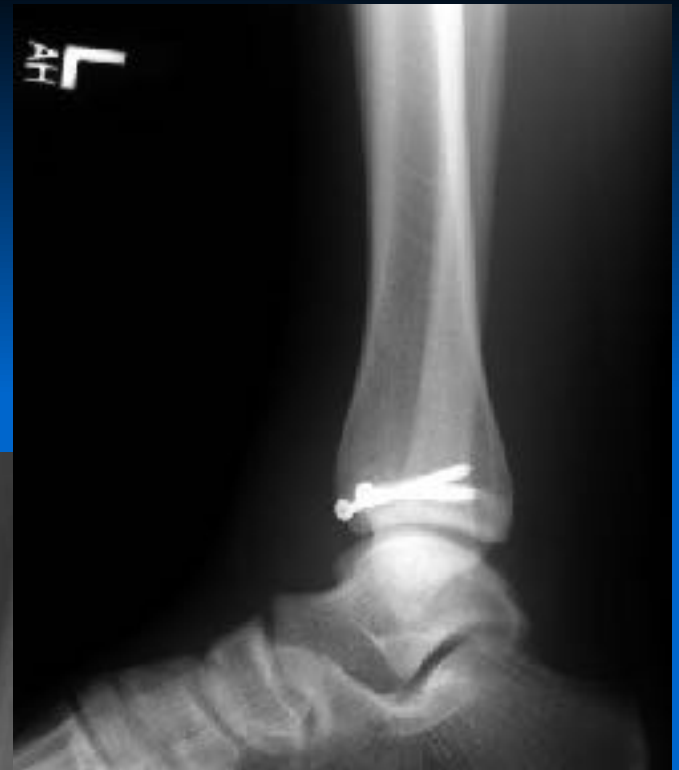
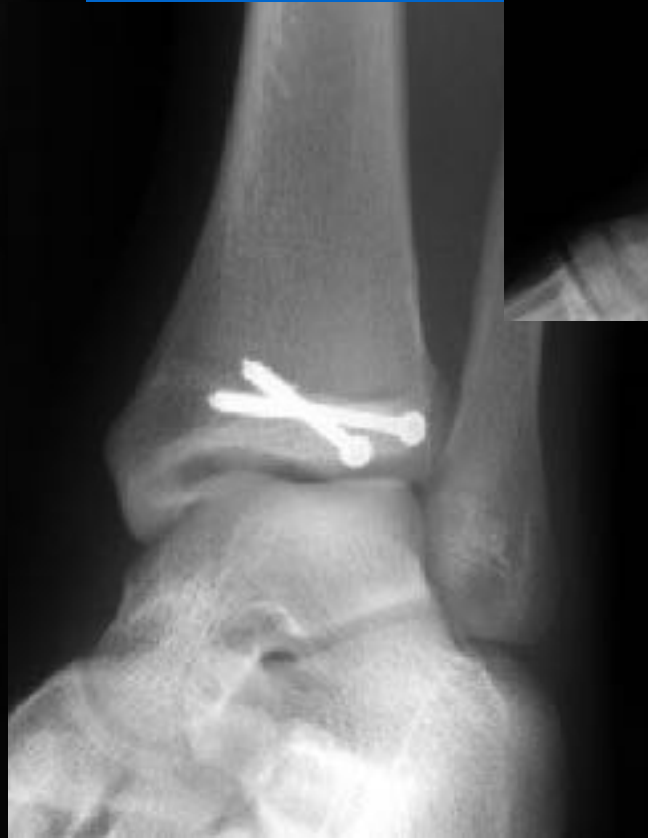
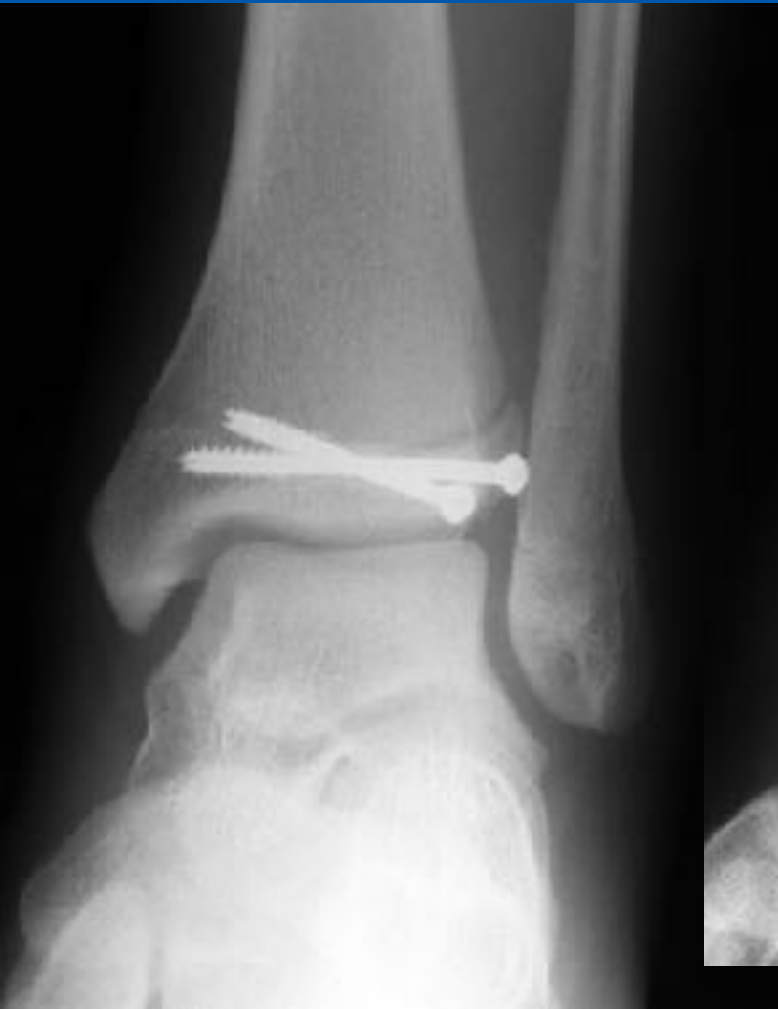
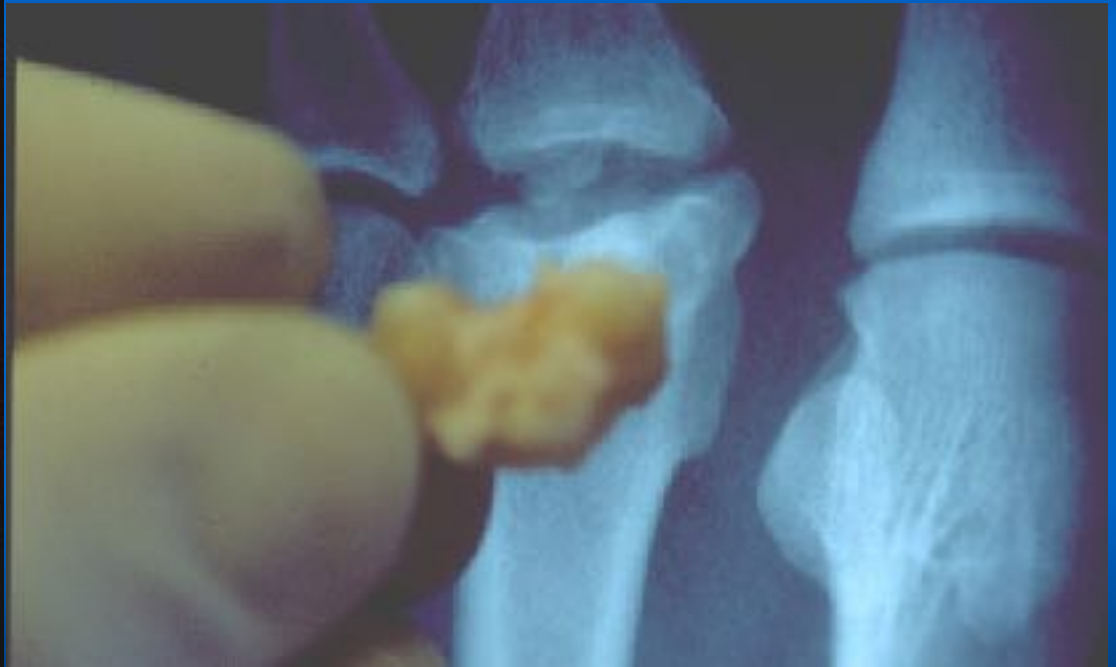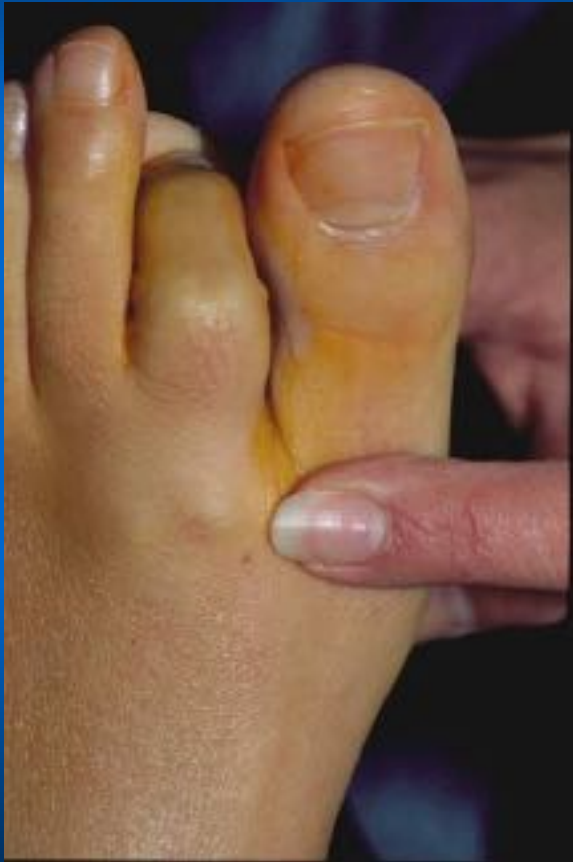# Scope



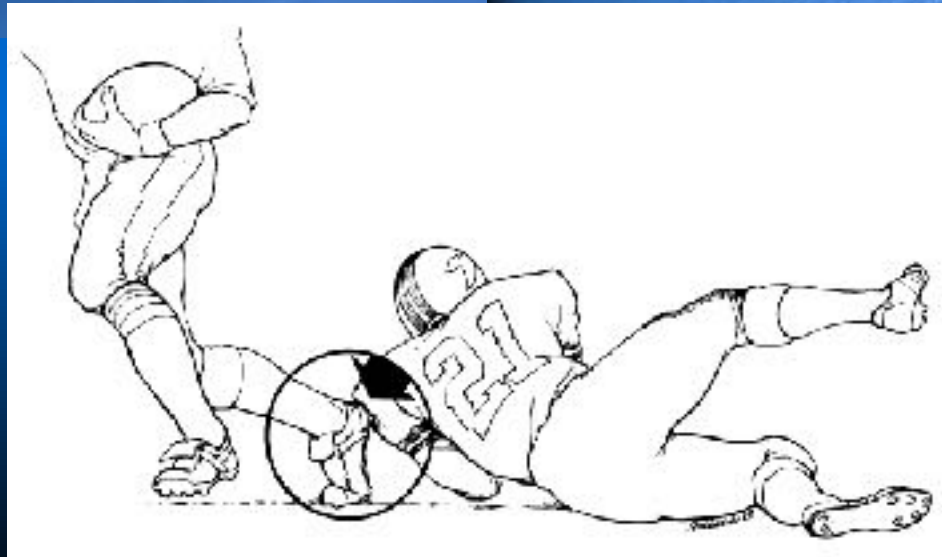
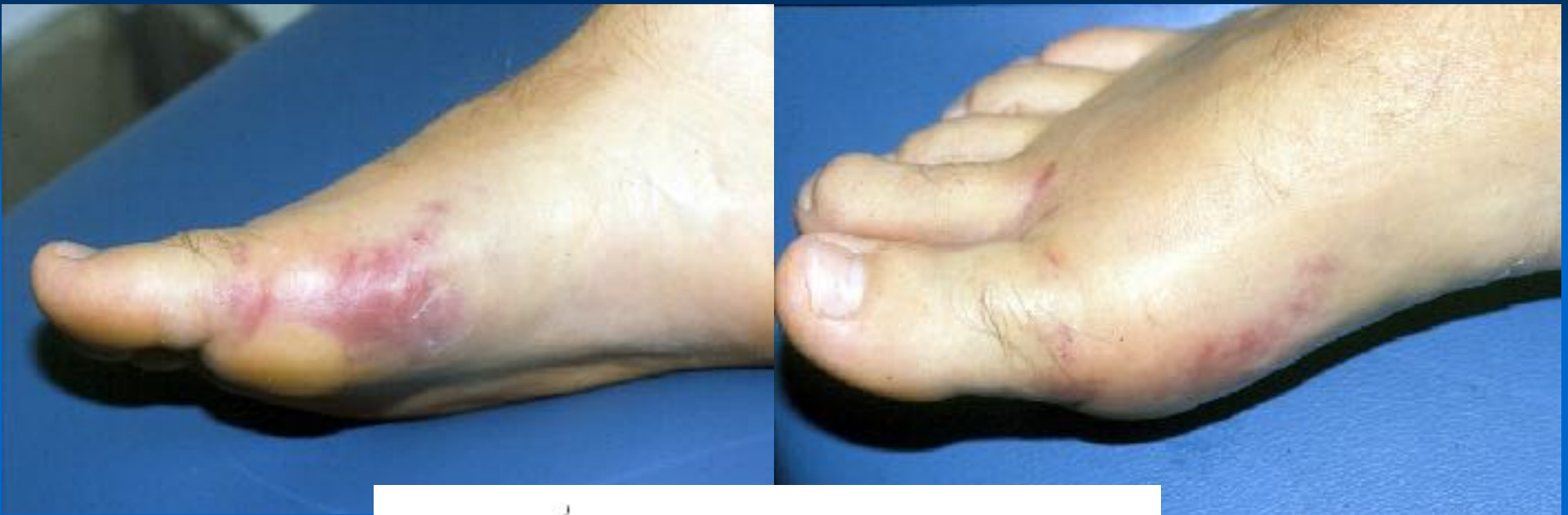**1 week  
post surgery**



# Freiberg's Infraction

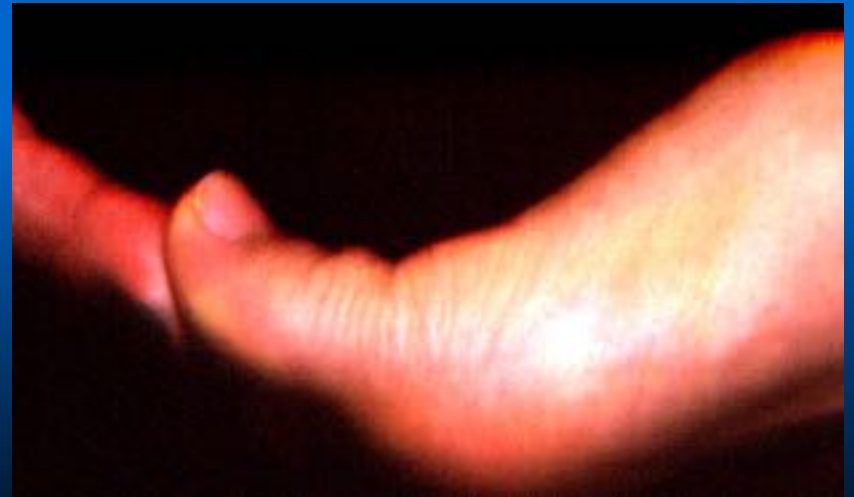
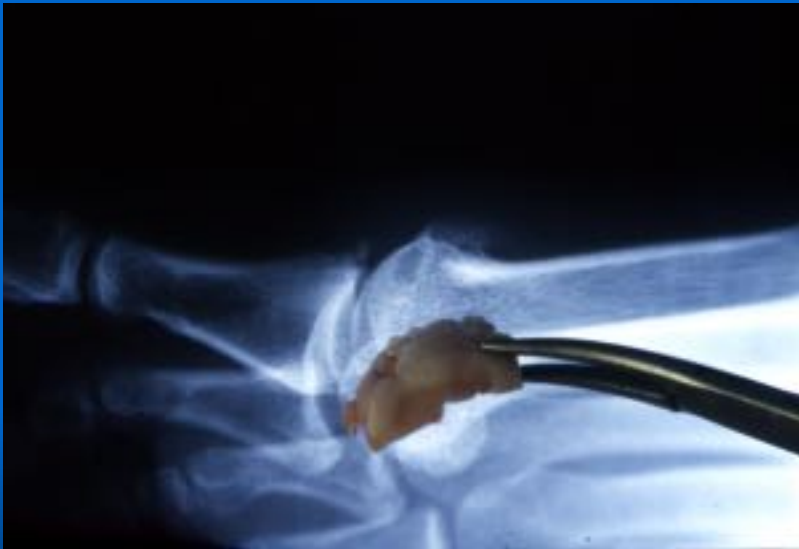
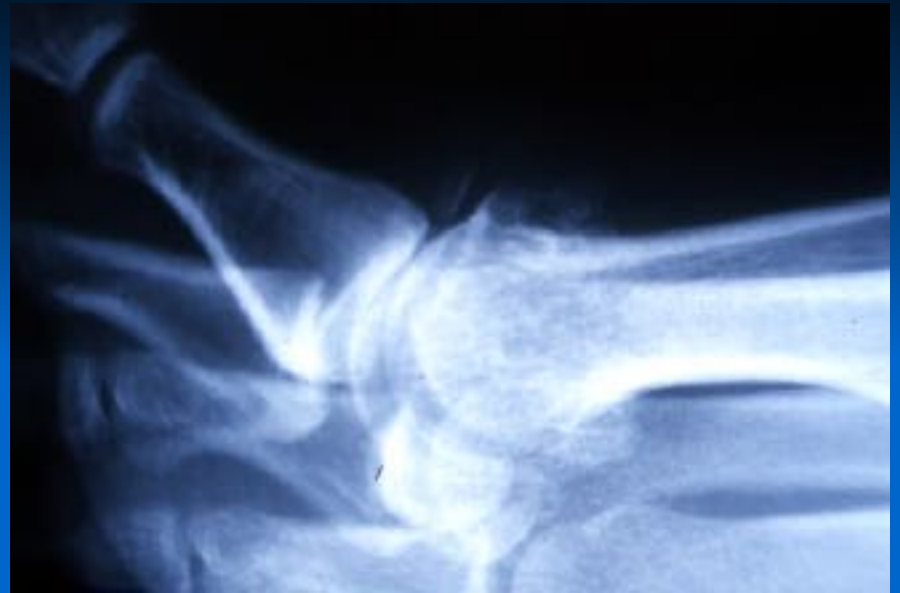# Turf Toe: Football Athlete

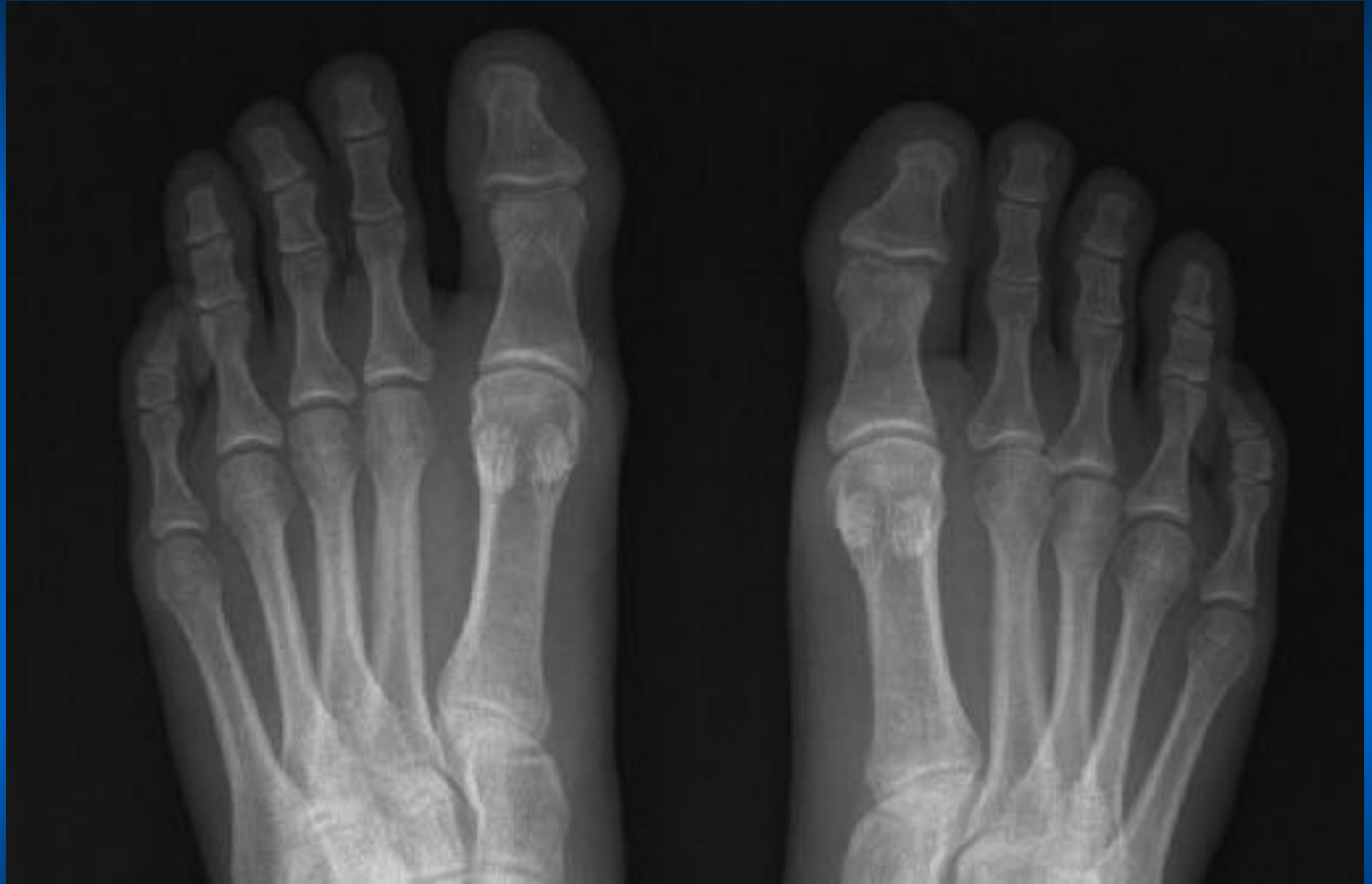



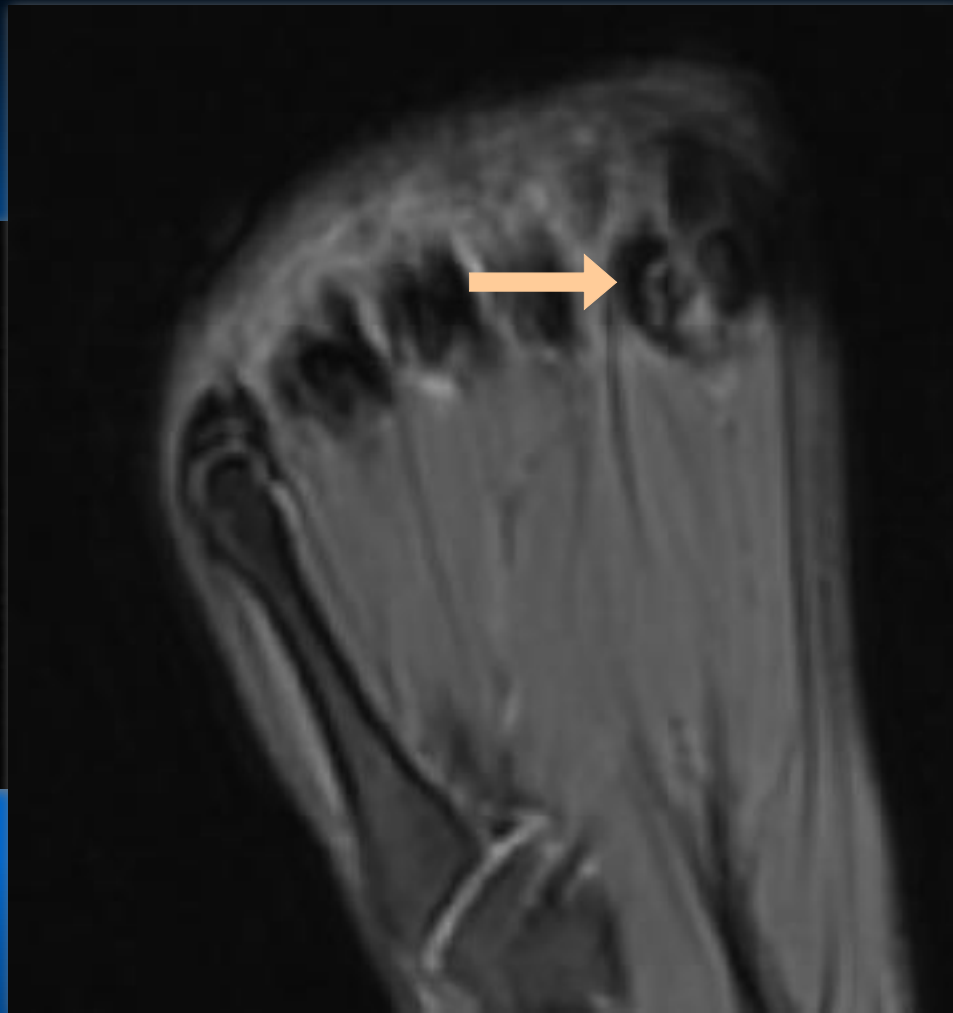
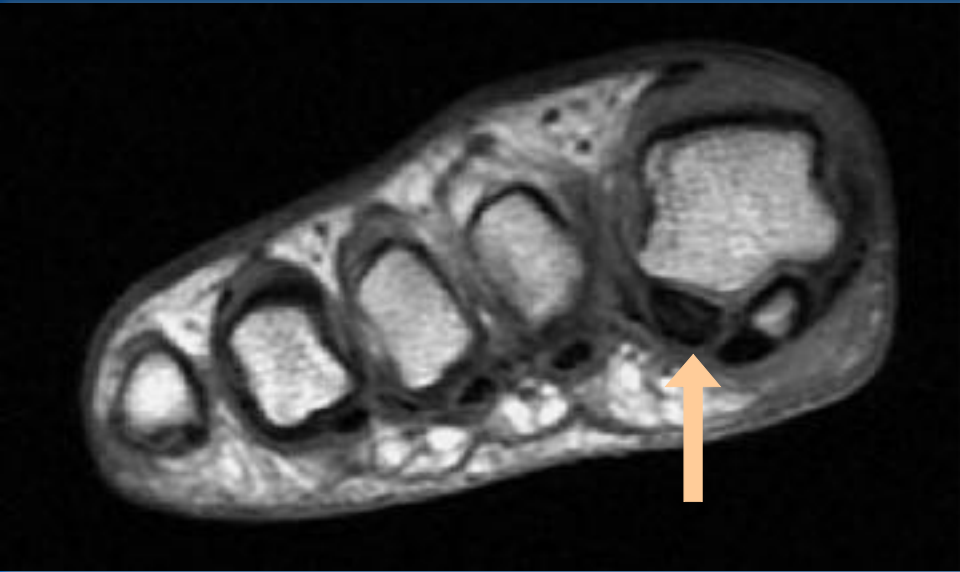
# Hallux Rigidus



# Dancer with Pain at Base of Great Toe

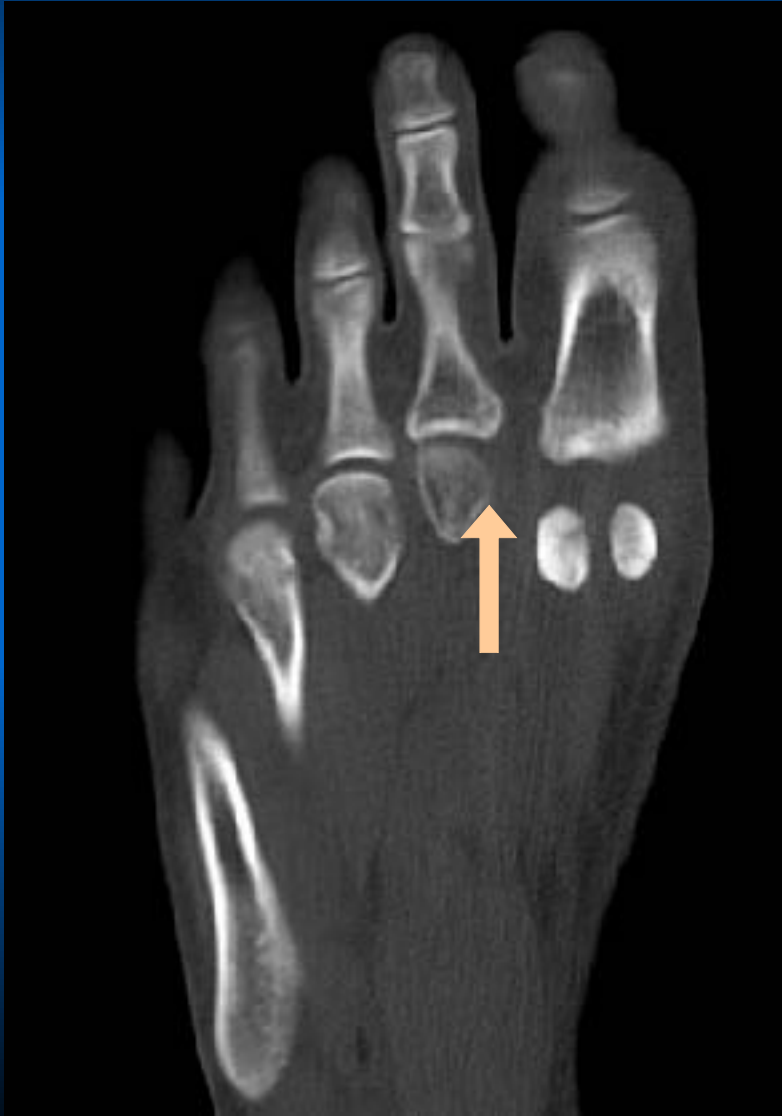

Courtesy Martin L. Schwartz, MD  
Clinical Prof. of Radiology, UAB



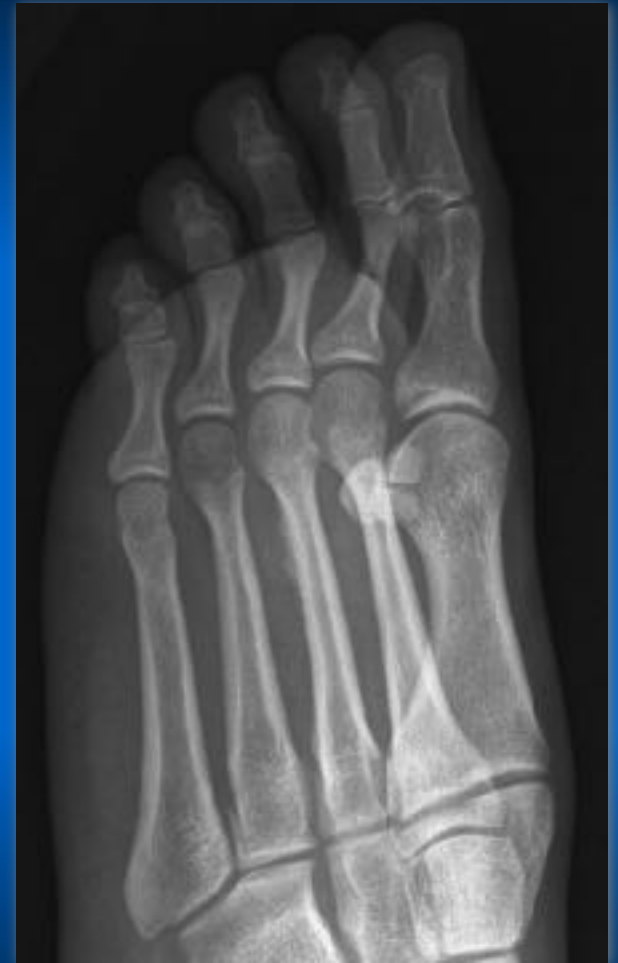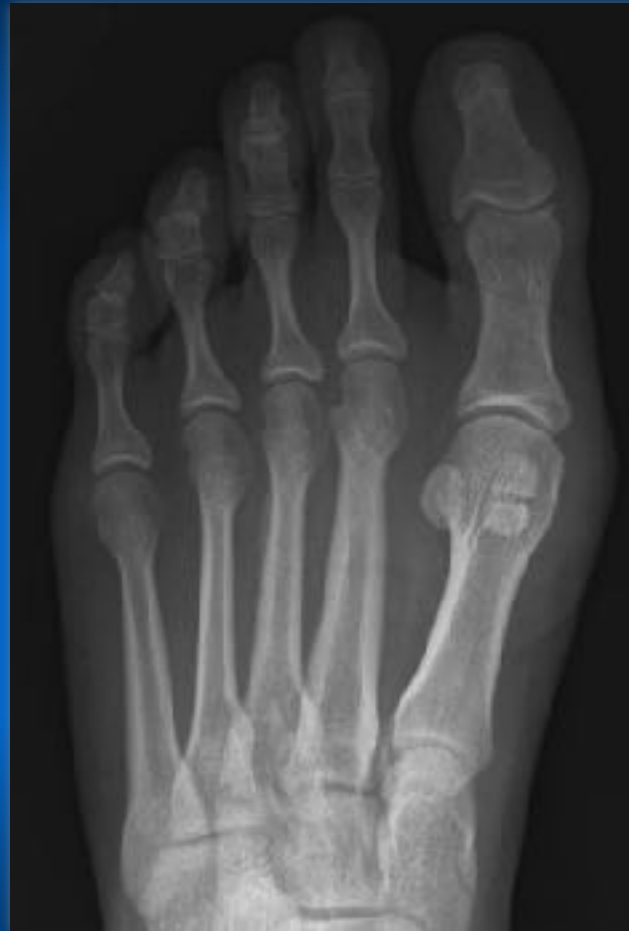Courtesy Martin L. Schwartz, MD  
Clinical Prof. of Radiology, UAB

# Lateral Sesamoid Fracture



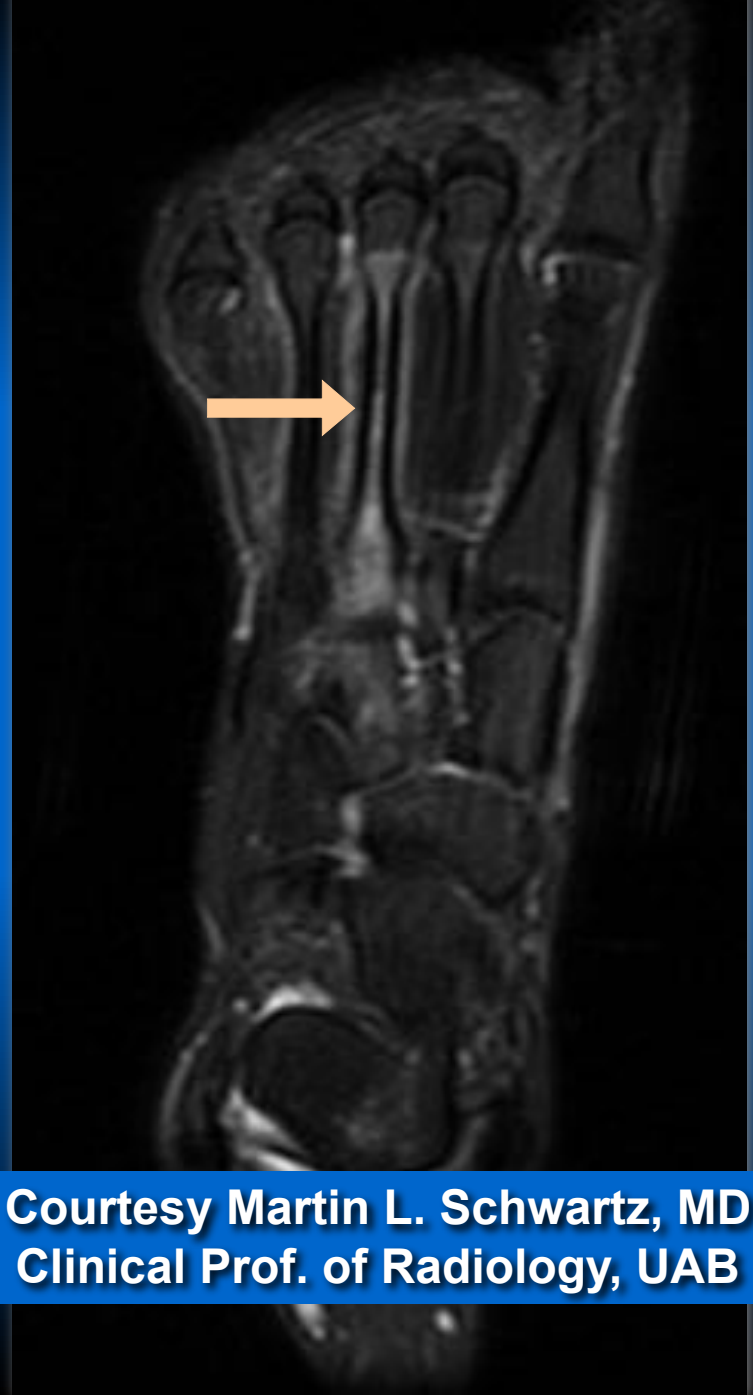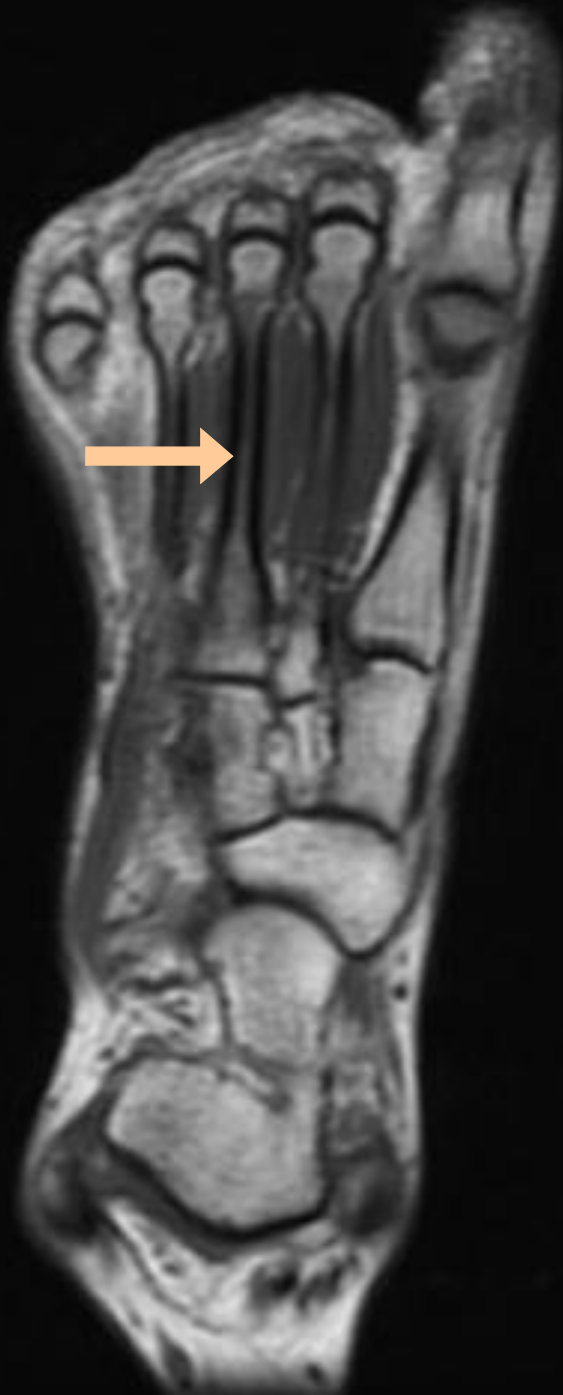Courtesy Martin L. Schwartz, MD  
Clinical Prof. of Radiology, UAB

# High School Distance Runner with Midfoot Pain



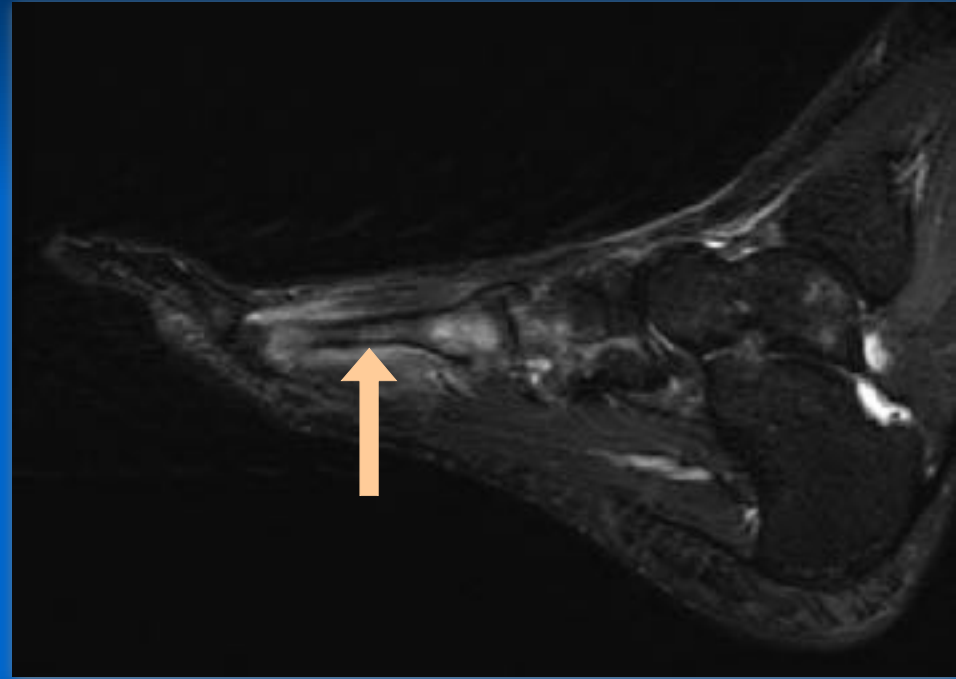
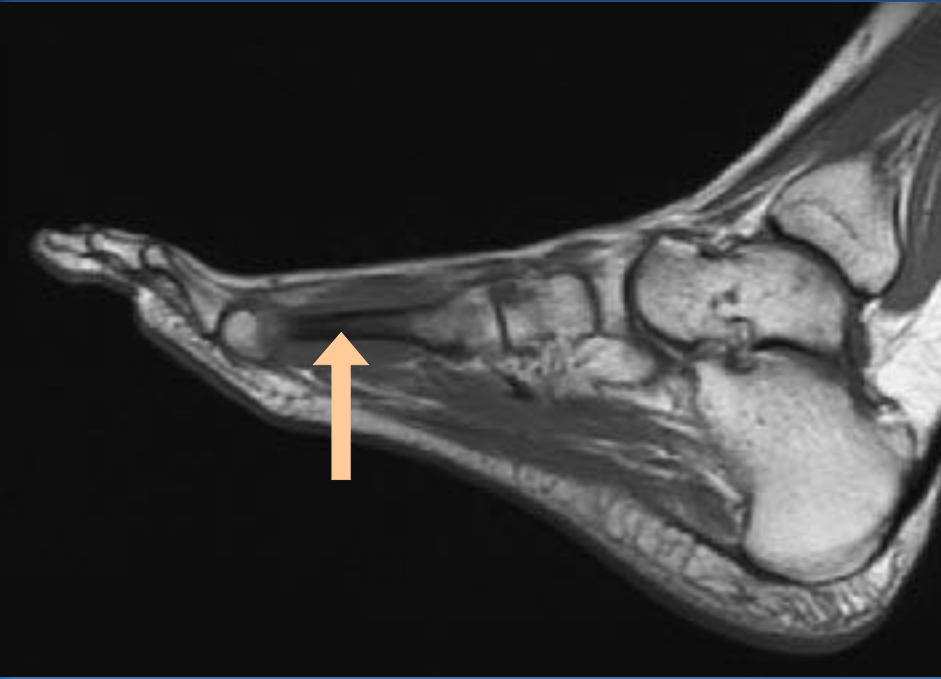Courtesy Martin L. Schwartz, MD  
Clinical Prof. of Radiology, UAB





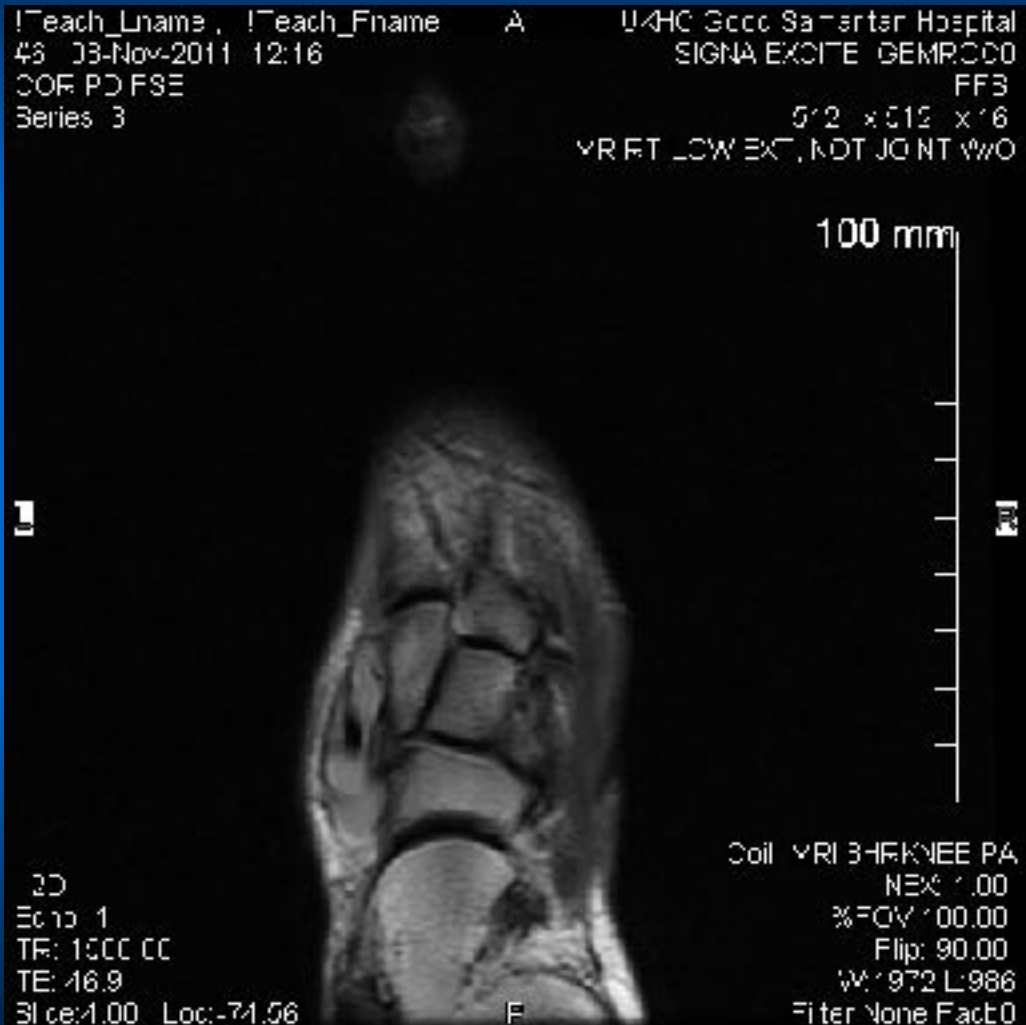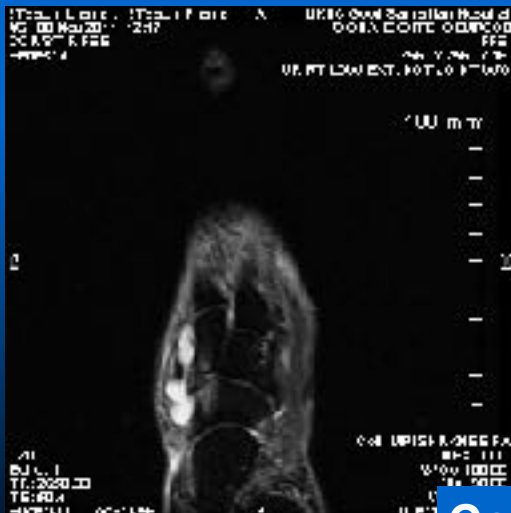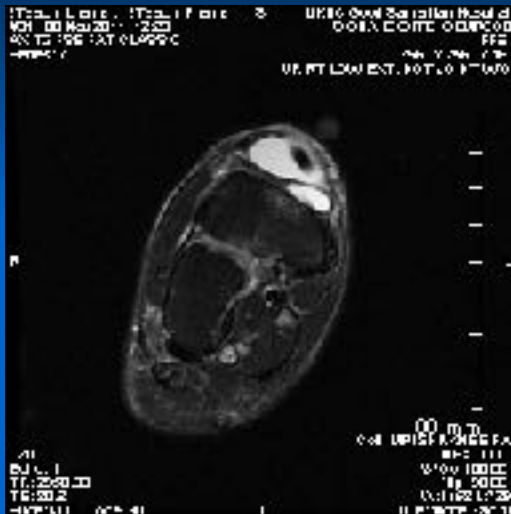
Courtesy Martin L. Schwartz, MD  
Clinical Prof. of Radiology, UAB

# 3<sup>rd</sup> Metatarsal Stress Fracture



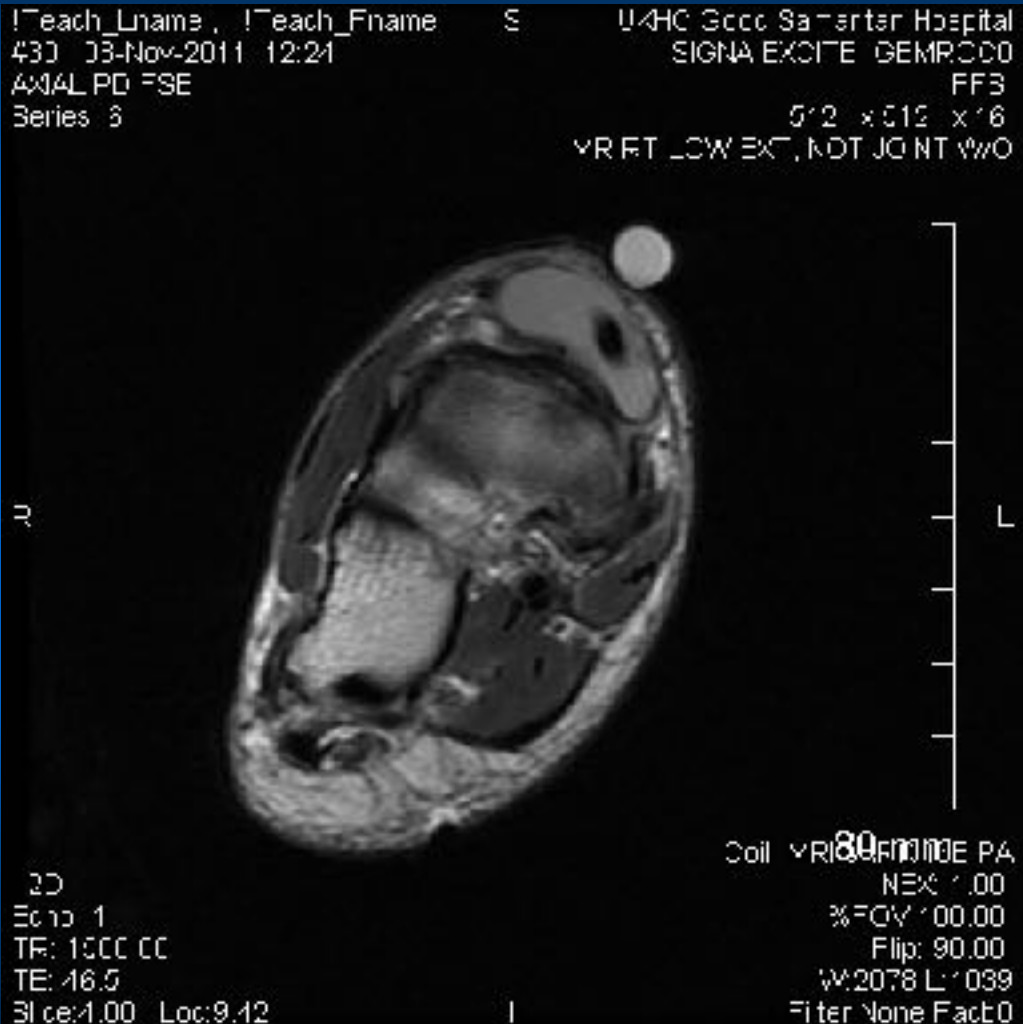
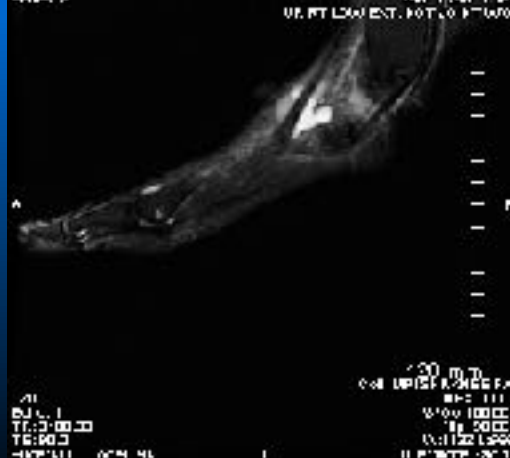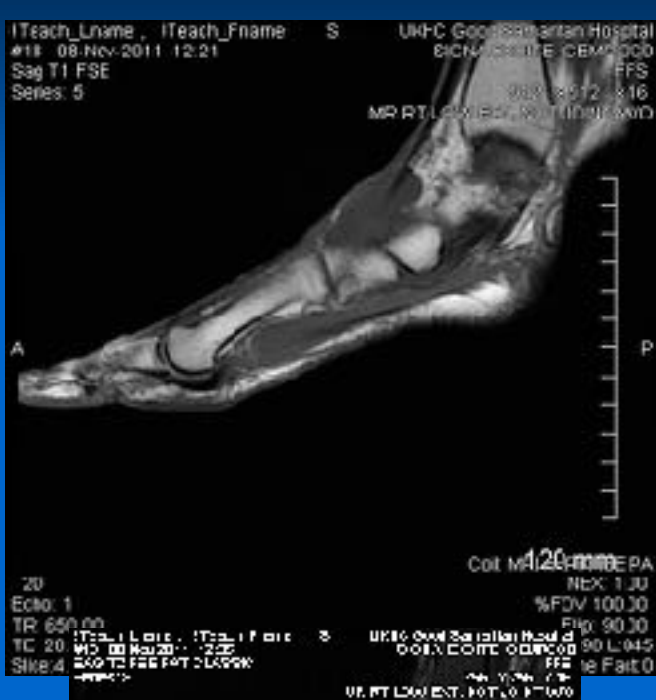Courtesy Martin L. Schwartz, MD  
Clinical Prof. of Radiology, UAB

# POST TIBIALIS FOCAL TENOSYN VS GANGLION



Courtesy UK Radiology

# POST TIBIALIS FOCAL TENOSYN VS GANGLION



Courtesy UK Radiology

**Ohio OHSA Div 3 Girls Cross County 2007:  
Left Leg: Tibia & Fibula Fractures**





**Pay Attention!**  
**Don't Let Anyone Trip You Up**



**Mary Lloyd Ireland, MD**

Associate Professor

Dept. of Orthopaedic Surgery & Sports Medicine

University of Kentucky

Lexington, Kentucky

**[www.MaryLloydIreland.com](http://www.MaryLloydIreland.com)**