

# The Injured Athlete

Third Edition

*Editor*

**David H. Perrin, Ph.D., A.T.C.**

*Professor*

*Curry School of Education*

*University of Virginia*

*Charlottesville, Virginia*

*Illustrations by Birck Cox*

*Photography by Daniel Grogan*



***Lippincott - Raven***

P U B L I S H E R S

*Philadelphia • New York*

Acquisitions Editor: Danette Knopp  
Developmental Editor: Anne M. Sydor  
Manufacturing Manager: Tim Reynolds  
Production Manager: Kathleen Bubbeo  
Production Editor: Carolyn Foley  
Cover Designer: Joseph DePinho  
Indexer: Dorothy Hoffman  
Compositor: CJS-Tapsco  
Printer: Maple Press

© 1999, by Lippincott-Raven Publishers. All rights reserved. This book is protected by copyright. No part of it may be reproduced, stored in a retrieval system, or transmitted, in any form or by any means—electronic, mechanical, photocopy, recording, or otherwise—without the prior written consent of the publisher, except for brief quotations embodied in critical articles and reviews. For information write **Lippincott-Raven Publishers, 227 East Washington Square, Philadelphia, PA 19106-3780.**

Materials appearing in this book prepared by individuals as part of their official duties as U.S. Government employees are not covered by the above-mentioned copyright.

Printed and bound in the United States of America

9 8 7 6 5 4 3 2 1

---

#### Library of Congress Cataloging-in-Publication Data

The injured athlete.—3rd ed. /editor, David H. Perrin;  
illustrations by Birck Cox.

p. cm.

Includes bibliographical references and index.

ISBN 0-397-51534-0

1. Sports injuries. 2. Sports medicine. I. Perrin, David H.,  
1954-

[DNLM: 1. Athletic Injuries—therapy. 2. Physical Education and  
Training—methods. 3. SportsMedicine—methods. QT 261156 1999]

RD97.155 1999

617.1'027—dc21

DNLM/DLC

for Library of Congress

98-26849

CIP

---

Care has been taken to confirm the accuracy of the information presented and to describe generally accepted practices. However, the authors, editors, and publisher are not responsible for errors or omissions or for any consequences from application of the information in this book and make no warranty, expressed or implied, with respect to the contents of the publication.

The authors, editors, and publisher have exerted every effort to ensure that drug selection and dosage set forth in this text are in accordance with current recommendations and practice at the time of publication. However, in view of ongoing research, changes in government regulations, and the constant flow of information relating to drug therapy and drug reactions, the reader is urged to check the package insert for each drug for any change in indications and dosage and for added warnings and precautions. This is particularly important when the recommended agent is a new or infrequently employed drug.

Some drugs and medical devices presented in this publication have Food and Drug Administration (FDA) clearance for limited use in restricted research settings. It is the responsibility of the health care provider to ascertain the FDA status of each drug or device planned for use in their clinical practice.

## CHAPTER 15

# The Knee

Mary Lloyd Ireland, Mark R. Hutchinson, Richard I. Williams,  
and Michael Gaudette

### THE KNEE

With advances in technology, more experience, and basic research, our understanding of knee injuries has reached a new level. Procedures once considered uncharted, radical, and dangerous are now the "gold standard." An open meniscectomy is unusual. Repairing and saving the meniscus is routine. The goal is to restore normal homeostasis of the knee (61).

Technologic advances in fiberoptics, computerized video data transmission, and the development of specialized instrumentation have resulted in the acceptance of arthroscopy and arthroscopically assisted procedures by an overwhelming majority of orthopaedic surgeons. New hopes for restoring "normal knee function" include articular surface reimplantation and meniscal allograft. Once reserved for only the most elite athletes, anterior cruciate ligament (ACL) reconstruction is commonplace among even middle-aged weekend warriors who enjoy and want to continue an active lifestyle.

Careful objective reporting of clinical results has provided an opportunity to reevaluate the earlier surgical procedures such as lateral retinacular release for "chondromalacia patella" or "diagnostic" arthroscopy. With the climate of health care reform, questions regarding access to specialty care have placed scrutiny on the results of our therapies, and "outcomes research" has become mandatory in the 21st century.

M. L. Ireland: Kentucky Sports Medicine Clinic, Lexington, Kentucky 40517

M. R. Hutchinson: Department of Orthopaedics and Sports Medicine, University of Illinois at Chicago, Chicago, Illinois 60612-7342

R. I. Williams: Upper Cumberland Orthopaedics and Sports Medicine, Cookeville, Tennessee 38501

M. Gaudette: Joyner Sportsmedicine Institute, Lexington, Kentucky 40517

A growing trend can be seen away from "emergent" and "urgent" operative intervention in most types of knee injuries. Studies documenting increased complications from stiffness following ACL reconstruction results in reconsideration of taking the athlete from the football field or ski slope directly to the operating room. After the acute knee injury, careful repeated examinations will establish the correct diagnosis. Prior to surgery, the goal is a normal-appearing knee—no swelling, normal range of motion, and good lower extremity muscle function. The physician should carefully stress to the athlete, however, that nonoperative treatment is not the same as "no treatment." The athlete must participate in his/her own care. Imagine the emotions involved when an urgent surgical procedure is performed for an acutely unstable knee and the result is less than satisfactory: the athlete did not have an opportunity to experience the consequences of the injury—perhaps it barely hurt at all—but he/she can certainly see the effects of the surgical intervention! The unfortunate consequence is the shifting of anger by the athlete from the injury itself to the treating physician, physical therapist, or athletic trainer.

Progress in other areas, including the advent of magnetic resonance imaging (MRI) for diagnostic use in selected cases, and rehabilitation protocols emphasizing closed chain activities and rapid return to play, have facilitated a more comprehensive and directed approach to therapy. The accuracy of MRI has revealed interesting injury patterns, such as "bone bruises" associated with ligament tears. The specificity of such diagnostic exams has rendered the old, nonspecific terminology "internal derangement of the knee" an historic footnote. Conversely, the fiscal and market separation of orthopaedist and physical therapist, brought about in the United States by ethical concerns regarding overutilization and self-referral, have caused a rethinking of protocols.

Indeed, controversy remains in almost every realm of

treating knee injuries. Operative versus nonoperative treatment of complete medial collateral ligament (MCL) tears, appropriate graft material choice and fixation in ACL surgery, treatment of combined instabilities, and indications for meniscal repair are currently hot topics for debate. Therefore, it is even more imperative that clinicians be systematic and thorough in all phases of diagnosis and treatment. Documentation of findings and therapies is of paramount importance, not only for future research but in a litigious climate to protect caregivers from frivolous attack. Always remember to examine the contralateral extremity, perform a systematic, complete exam, and record the findings in a medical record.

The importance of ongoing research, both on a basic science/biomechanical level, and solid clinical research (case series, prospective and well-defined retrospective studies) cannot be overemphasized. The health-care professional must remain current and well-read. New advances should be examined critically. Anecdotal experience should be viewed skeptically. Informed, thoughtful decisions should be made regarding "advances" in treatment and technology. Beware of the new technologic advance, which is not backed by solid clinical and basic research. Newer is not *always* better. Similarly, one must be careful not to hang on to outmoded concepts and therapies. A given technique or procedure should remain a viable alternative if it yields objectively acceptable results, and does not involve undue limitations or negative long-term consequences for the athlete. It may be better to stick with a tested remedy than switch to one involving a long learning curve and technical pitfalls that might jeopardize the ultimate outcome.

Finally, in order to apply the most effective treatment program, the correct diagnosis must be made. The basic requirement is a complete knowledge of the normal knee anatomy. Differential diagnosis is made easy by correlating the mechanism of injury with the physical exam.

## ANATOMY

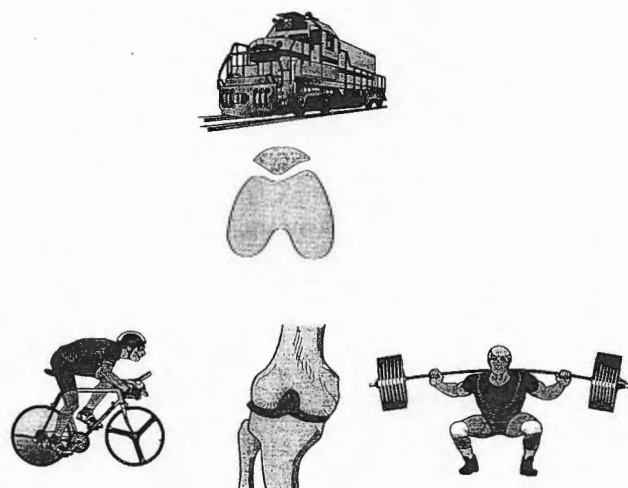
Understanding knee anatomy provides the basis for diagnosis and treatment of knee injuries. Knee anatomy has been well described in textbooks (16,57,69,94,114,134,175,178,200,210,221,234). Indeed, some textbooks are dedicated to a single component of knee anatomy such as the patellofemoral articulation (68,77) or the ACL (49,123). Surgical textbooks also provide detail of knee anatomy (49,96,104,114,123,175,221). Advances in arthroscopic techniques help to correlate anatomy, mechanism of injury, operative findings and treatment (9,126,166). This anatomy section will review bony anatomy, extensor mechanism, ligaments and capsule, (medial side lateral side) menisci, and cruciate ligaments.

## Bony Anatomy

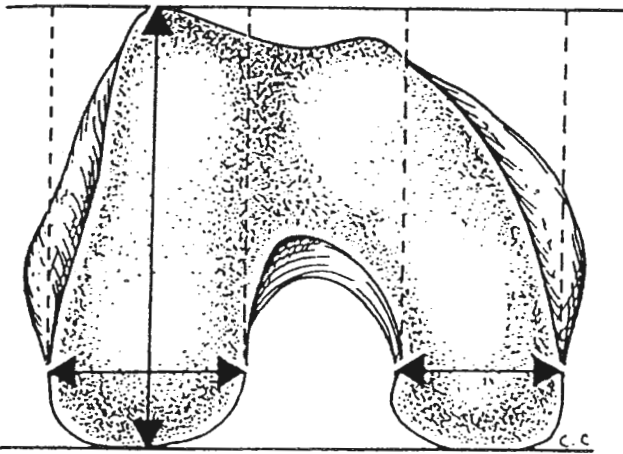
The knee joint is the largest and one of the most complex joints in the human body. There are three independent articulations. The patella and trochlear groove of the femur or patellofemoral (PF) articulation is anterior. The two weight-bearing compartments are the medial or inner compartment and the lateral or outer compartment. Each is composed of the tibial plateau, the femoral condyle and the meniscus with capsuloligamentous attachments. Each compartment is unique anatomically. The PF articulation can be compared to a train on a track. The patella (train) is more stable on a well-formed deep trochlear groove (track). The medial compartment has more compression forces and stronger capsuloligamentous attachments to the meniscus. The lateral compartment has a more convex lateral tibial plateau, more movement, distraction, and rotation (Fig. 15.1).

The distal femur forms two large, curved knuckles, or condyles, with a sulcus or depression in between. The distal portions of the condyles articulate with the tibial plateau, whereas the anterior sulcus or trochlea provides the contact surface for the patella, a floating sesamoid bone, embedded within the anterior quadriceps "extensor" mechanism. The lateral ridge of the trochlea is more anterior and wider than its medial counterpart and resists lateral translation of the patella (Fig. 15.2).

The condyles have a different shape and radius of curvature. The medial condyle is elliptical, larger, more distal, and a factor in the normal 5 to 9 degrees of valgus alignment. The lateral condyle is shorter and more spheroid (234). The differential sizes of the condyles result in a phenomenon known as the "screw-home" mechanism,



**FIG. 15.1.** Diagrammatically, the three compartments of the knee can be compared to a train (patella) on a track (trochlear groove). Medial compartment has more stability and compressive forces similar to a weight lifter and the lateral compartment has more mobility and rotation, compared to a bicyclist in a velodome.

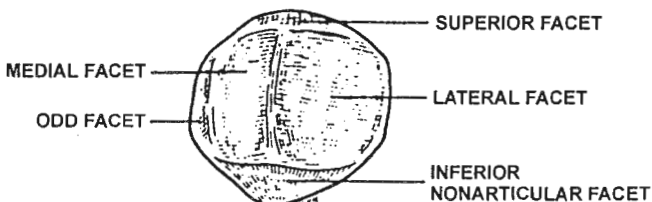


**FIG. 15.2.** A comparison of the medial and lateral femoral condyles shows that the lateral condyle is broader in the transverse plane. (Reprinted with permission from ref. 16.)

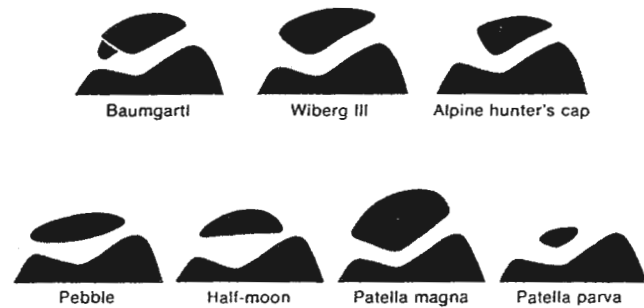
whereby the tibia subtly rotates externally on the femur slightly as the knee comes into full extension (234). Between the femoral condyles distally is a recessed area referred to as the intercondylar notch where the cruciate ligaments attach. The intercondylar notch size, width, and shape forms in relation to the size of the ACL. If the ligament is small, the notch will accordingly be small. On the tibial surface opposing the notch are two raised areas known as the medial and lateral tibial spines or eminences. These spines reduce rotational forces and serve as anatomic landmarks for the surgeon.

The tibia also serves as the insertion point of multiple muscles and ligaments that control knee function. These structures include: the tibial tubercle for the patellar tendon/ligament; Gerdy's tubercle—for the iliotibial tract; and the proximal fibula—for biceps femoris and lateral collateral ligament.

The patella is a sesamoid bone that functions as a fulcrum to improve the efficiency of the quadriceps mechanism. The undersurface of the patella consists of the following facets: medial, lateral, odd, and nonarticulating (77) (Fig. 15.3). The patella functions to increase the lever arm of the quadriceps and to shield and protect the femoral condyles. The articulating surface is covered with the thickest layer of hyaline cartilage in the body. Patellar



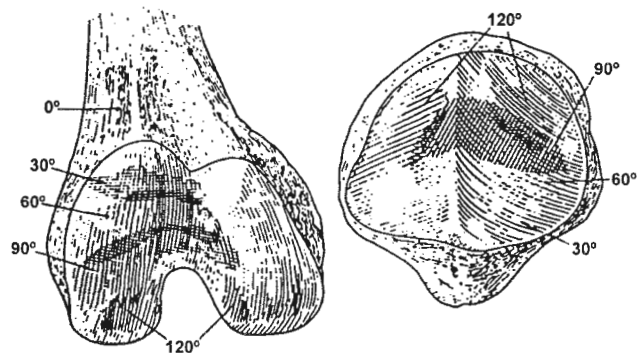
**FIG. 15.3.** Patellar articular surface consists of odd, medial, and lateral facets. Superior and inferior nonarticulating facets are shown.



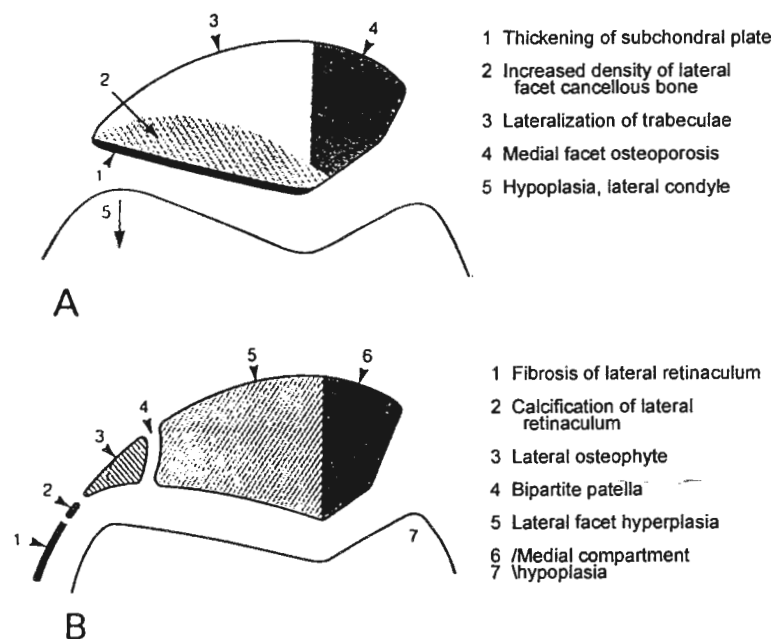
**FIG. 15.4.** Variations in patella form considered dysplastic. (Reprinted with permission from ref. 77.)

stability is enhanced by a deeper trochlear groove, less valgus alignment, and quadriceps balance between the vastus lateralis and vastus medialis obliquus. Wiberg and Baumgartl have described seven different types of patellar shape depth of the sulcus, including Baumgartl, Wiberg III, Alpine hunter's cap, Pebble, Half-moon, Patella magna, and Patella parva (Fig. 15.4) (19,221,253).

Patellar contact increases and moves more proximally throughout knee flexion. Early flexion at 30 degrees has contact at the superior trochlear groove (1) (Fig. 15.5). Also, with increasing knee flexion angle, there is increased tension in the quadriceps and patellar tendon (32,77,97). Excessive lateral pressure will cause a bony response with direct radiologic signs (77) (Fig. 15.6A). Patients with excessive lateral patellar syndrome (ELPS) have a very long patellar facet, an acute osteopenic medial patellar facet, and a long, flattened lateral trochlear groove. The result is thickening of the patellar subchondral plate, increased density of the lateral facet and cancellous bone, and lateralization of trabecula (see Fig. 15.6B). More localized problems of ELPS are lateral retinacular fibrosis and calcification, lateral osteophyte of the patella and sometime matching osteophyte of the femur, lateral facet hyperplasia and medial side hypoplasia.



**FIG 15.5.** Patellofemoral contact areas are shaded at 0, 30, 60, 90, 120 degrees flexion in this right-knee diagram. Femur (lateral to left and medial to right) and patella (lateral to right and medial to left) are shown. (Reprinted with permission from ref. 1.)



**FIG. 15.6. A.** Indirect radiologic signs of excessive lateral pressure. **B.** Indirect radiologic signs of excessive lateral ligamentous tension. (Reprinted with permission from ref. 77.)

### The Extensor Mechanism

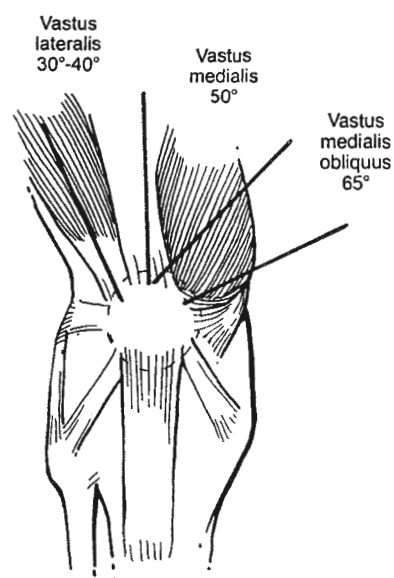
The quadriceps muscle group originates from the proximal femur and anterior hip capsule/pelvis. Muscular components include the rectus femoris, vastus lateralis, vastus intermedius, vastus medialis, and vastus medialis obliquus (VMO). The rectus femoris crosses the hip and knee joint, acting in hip flexion and knee extension. During a normal gait cycle, momentum and gravity actually allow for knee extension during the swing phase without significant quadriceps activity. The quadriceps eccentrically decelerates the flexed knee following heel strike (147). Walking creates patellofemoral force of one-half body weight, stair climbing 3.3 times body weight and with activities such as landing, forces approach seven to eight times body weight (208).

The four quadriceps muscles blend together in the distal thigh to form the quadriceps tendon, which subsequently envelops the patella. Two subspecialized portions of the quadriceps arise distally. The articularis genu comes from the deep vastus medialis and serves to retract the suprapatellar pouch from beneath the patella during extension. Although the vastus medialis obliquus (VMO) does not provide extension force, it stabilizes the patella medially (146). The VMO inserts on the proximal half of the medial patella at a 65-degree angle from its origin on the intermuscular septum and adductor magnus (Fig. 15.7). The appearance of the VMO reflects the overall health of the quadriceps. With its thinner fascia, the VMO is the first muscle to atrophy with injury and the last to return with full recovery.

The various anatomic structures in the knee act in concert. No one structure performs a particular function by

itself. The terminal 15 degrees of knee extension requires 60% more force by the quads than is needed up to that point; however, when the VMO effectively centers the patella, this force is decreased by 13% (146). Electromyographic (EMG) analysis has confirmed the medialization role of the VMO (147,159,207). Medially and laterally the extensor mechanism is stabilized by sheets of expanded fascia called the "retinaculum."

The quadriceps tendon/expansion narrows considerably



**FIG. 15.7.** Various muscular elements of the quadriceps. Different portions attach at different angles to the long axis of the thigh, creating various vectors of force. (Reprinted with permission from ref. 57.)

as it traverses the patella, tapering into the patellar tendon or more correctly a "ligament" in that it connects bone to bone. The average patellar tendon is between 30 to 40 mm in width and 40 to 50 mm in length.

### Biomechanics

The knee joint functions to absorb the shock of weight bearing, and maintain the height of the body's center of gravity along a gentle, sinusoidal line. As the link between hip and ankle, the knee possesses great flexibility and durability, and protects the important neurovascular structures of the limb while transmitting them from the thigh to the foot.

The bony anatomy of the knee provides very little inherent stability. Of the three rotational and three translational degrees of freedom that the knee joint is subject to, only rotation in the coronal plane and translation vertically are significantly limited by the bony anatomy of the knee (23,67,89,181) (Fig. 15.8).

The movements about the knee are around three planes—axial, coronal, and sagittal. The movements in the axial plane are rotational—internal (compression) and external (distraction); in the coronal plane, movements are flexion and extension; and in the sagittal plane, movements are adduction (varus) and abduction (valgus). To stabilize the knee in all other planes and directions, the knee depends on its capsule, menisci, ligaments, and muscle tendons. Although the patellofemoral joint contains some inherent stability relating to the depth of the patellofemoral groove, the height of the median ridge of the patella and lateral femoral condyle, it too depends on musculotendinous units, ligaments, and capsule for stability.

### Ligaments and Capsule

The bony anatomy of the knee joint does provide some static stability to the knee, especially in extension, whereas the muscle groups (quads, hamstrings, gastrocnemius) crossing the knee lend dynamic control. However, the four major ligaments of the knee are of utmost importance in maintaining knee kinematics throughout the vigorous acts of running, cutting, pivoting, and traveling on inclined surfaces. The functions of the ligaments are integrated and interdependent. Stability must exist in extension allowing a solid platform, yet great flexibility and rotational capacity must occur to dissipate anterotibial-directed tibial kinetic energy when "cutting" and shifting body momentum. The structures of the knee will be divided into sections: medial side (29,88,125,148,217), lateral side (86,88,223,242,243, 247), menisci (135), and the cruciate ligaments—anterior (52,83), and posterior (34,45,57a,90).

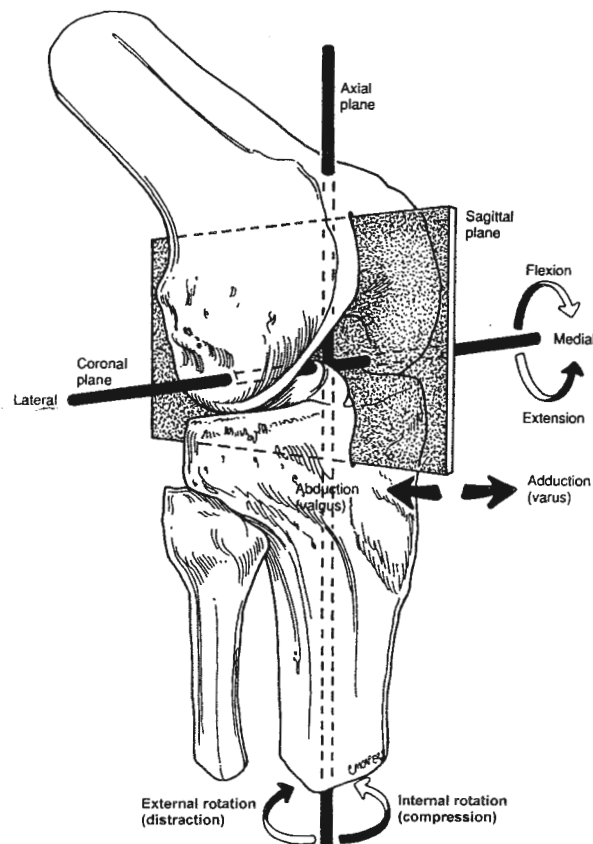
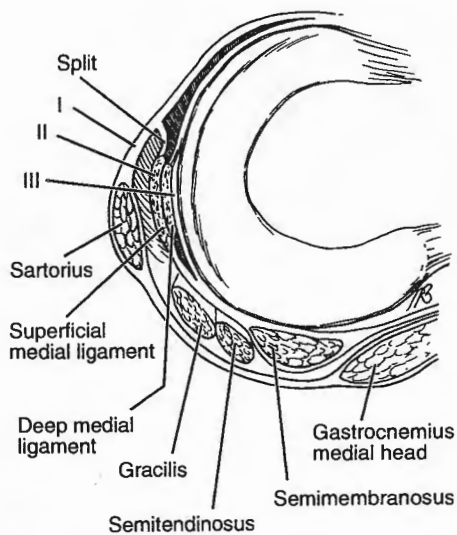


FIG. 15.8. A six-degrees-of-freedom model illustrates all possible rotations and translations about the knee. (Reprinted with permission from ref. 16.)

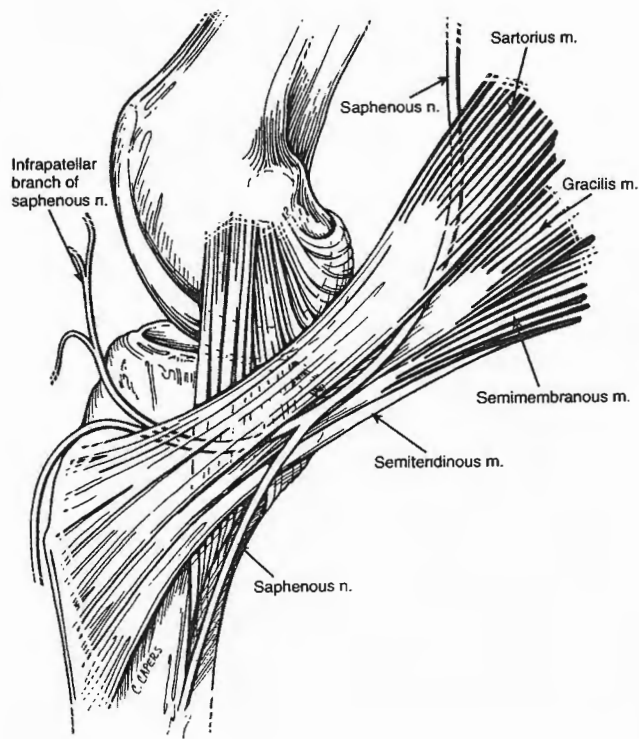
### The Medial Side of the Knee

It is helpful to think of the medial anatomy in three "layers"—discussing the various structures in relation to their depths (251) (Fig. 15.9). The most superficial layer (layer 1) contains the deep or crural fascia of the leg and the pes anserinus. In layer 2 are the superficial medial collateral ligament (SMCL), vertical fibers of the superficial medial collateral ligament, which have been termed the posterior oblique ligament. Layer 3 is the knee-joint capsule, deep medial ligament, and oblique popliteal ligament (98,104,217,251). The pes anserine tendon consists of three tendons shaped as a "goose's foot." It inserts into the tibia 3 cm. distal to the joint over the superficial tibial collateral ligament (Fig. 15.10). Each contributing muscle is innervated differently (sartorius—extensor group/femoral nerve; gracilis—adductors/obturator nerve; semitendinosus—hamstrings/sciatic nerve). The pes anserine serves to rotate the tibia internally and flex the knee. The sartorius, also known as the tailor's muscle, is the longest muscle in the body. The semimembranosus has multiple insertions onto the posterior tibia





**FIG. 15.9.** A bird's-eye view of the three layers of the medial structures, deep or crural fascia, sartorial fascia, superficial tibial collateral ligament and posteromedial corner, and layer III, joint capsule. The area labeled split denotes where the retinacular fibers anterior to the SML leave layer II and the SMA 3 to join layer I. (Reprinted with permission from ref. 217.)

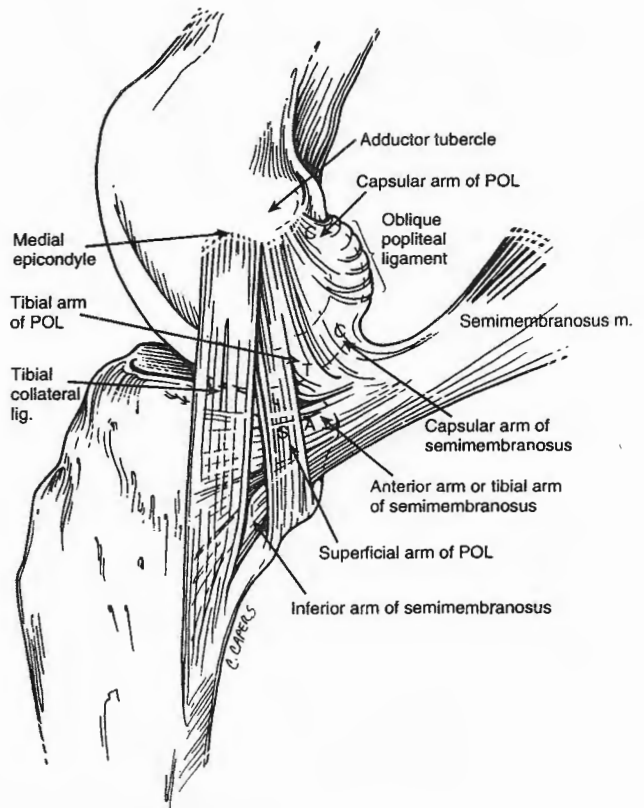


**FIG. 15.10.** The pes anserinus is the insertion of the tendinous expansions of the sartorius, the gracilis, and the semimembranosus muscles. (Reprinted with permission from ref. 16.)

(217,246). The medial head of the gastrocnemius is located posteromedially and can be used as an anatomic landmark for approaches to the posterior cruciate ligament (PCL) and posterior capsule. The plantaris originates from the linea aspera of the lateral femoral condyle proximal and superficially to the origin of the lateral head of the gastrocnemius. It inserts on the medial calcaneus. It does not appear to have any significant function at the knee.

Layers two and three merge posteriorly. The posterior oblique ligament forms a sling around the medial femoral condyle (37). The posteromedial complex (PMC) includes the posterior deep capsular ligament, which runs obliquely. The oblique popliteal ligament (OPL) and part of the semimembranosus expansion blend to insert into the posterior capsule (Fig. 15.11). In flexion, the medial hamstring dynamically tightens the posteromedial capsule and retracts the posterior horn of the medial meniscus. The remaining components of the semimembranosus insertion include a slip to the medial meniscus, one blending with the MCL, and a direct tibial attachment.

The deepest layer (layer 3) is the joint capsule itself. The capsular attachments to the medial meniscus have been named coronary ligament, deep capsular medial ligaments and deep MCL (29,99). The meniscal attachments to the capsule are described as the meniscotibial and me-



**FIG. 15.11.** The medial ligaments of the knee: medial view side. (Reprinted with permission from ref. 16.)



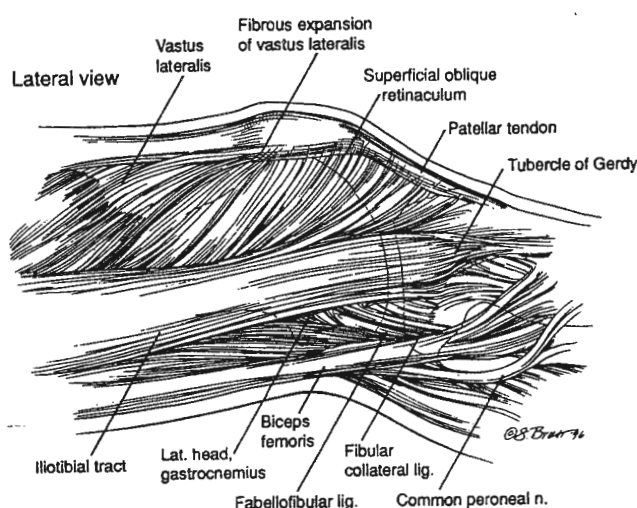
niscofemoral ligaments (Fig. 15.12). The "menisco-femoral ligament" is more stout and especially thick in the region just deep to the tibial collateral ligament.

### The Lateral Side of the Knee

Excellent descriptions of the lateral structures have been published (45,86,90,223,242,243). Correlation of injured structures to physical exam and injury mechanism is often helpful (57,104,175,247).

The iliotibial band (ITB) originates at the pelvis with contribution from gluteus maximus and tensor fascia latae. The iliotibial band is a fascial covering attaching to the lateral intermuscular septum at the level of the lateral femoral condyle, running over the lateral femoral epicondyle and blending anteriorly with the lateral patellar retinaculum. The iliotibial tract tapers distally, converging to insert on the proximal tibia at Gerdy's tubercle. Primarily a static stabilizer, some dynamic function occurs because of its proximal muscular connections. The biceps femoris inserts primarily at the fibular head, but also sends fibers to the posterolateral tibia, the joint capsule, and the iliotibial tract (Fig. 15.13). Both resist posterolateral tibial rotation.

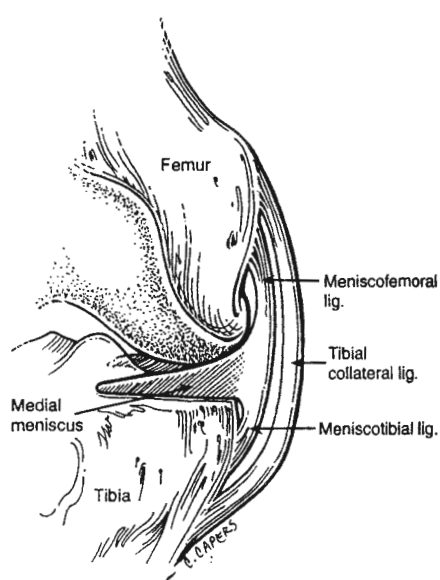
The lateral side of the knee is also described in three layers (86,175,223,247) (Fig. 15.14). Layer 1 consists of the iliotibial tract, and deep fascia of the thigh and calf. The biceps expansion and lateral insertion sites are also in this most superficial layer. The peroneal nerve is posterior to the biceps and classified in a knee layer. Layer 2 is formed by the quadriceps retinaculum confluent with the patella and the two patellofemoral ligaments. Layer 3, the deepest layer, is comprised of the lateral collateral



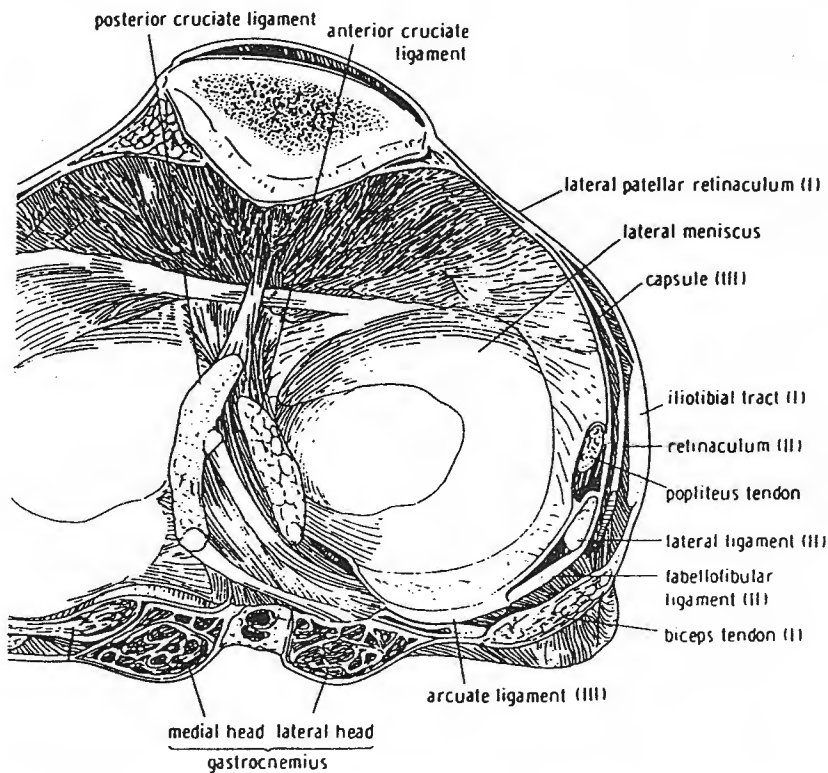
**FIG. 15.13.** Line drawing of the anatomy of the superficial portion of the lateral retinaculum and iliotibial tract of the knee. (Reprinted with permission from Greenleaf JE. The anatomy and biomechanics of the lateral aspect of the knee, *Operative Tech Sports Med* 1996;4(3):141.)

ligament (LCL), lateral capsule, fabellofibular ligament, short lateral ligament, lateral head of the gastrocnemius, popliteus tendon and coronary ligament, and the arcuate ligament. The Y-shaped arcuate ligament has two limbs—medial from proximal capsule to popliteus terminating in the oblique popliteal ligament and lateral from the posterior capsule to popliteus and fibular head. The LCL is a well-defined, pencil-shaped structure originating from the lateral epicondyle of the femur, inserting onto the fibular head. The LCL is tight in extension but relaxes in flexion. The arcuate complex is a triangular sheet of fibers diverging from the fibular head—the stronger lateral limb courses obliquely to the posterior femur, while the weaker medial limb attaches to the tibia posteriorly, crossing over the belly of the popliteus muscle. The fabellofibular complex is somewhat variable, arising from the fabella (itself variably present) on the deep aspect of the lateral head of the gastrocnemius muscle.

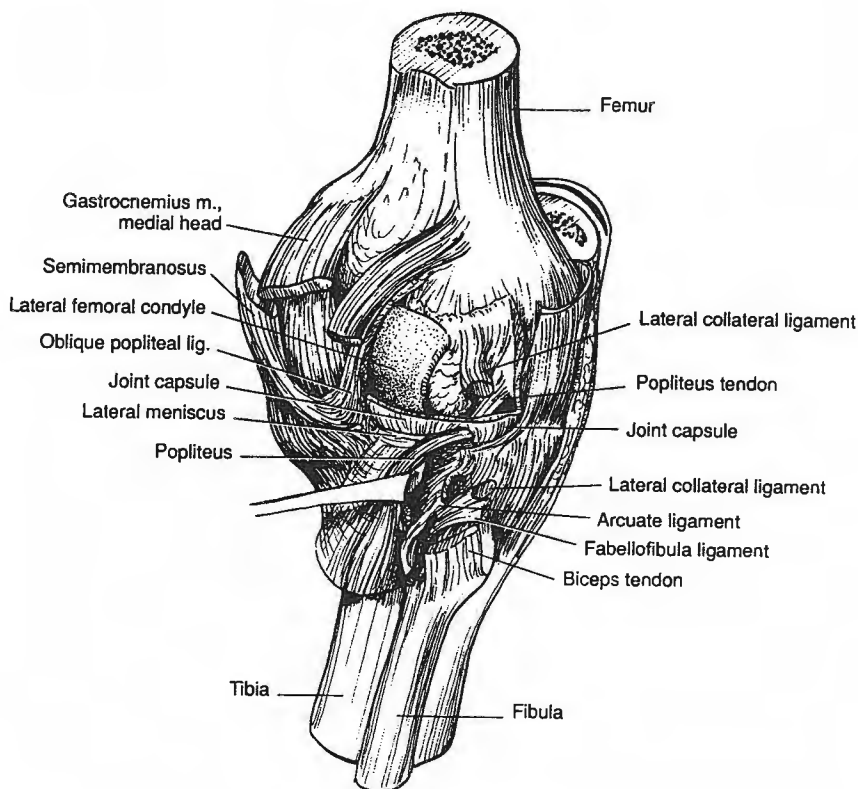
Recent interest in posterolateral knee instabilities has sparked a number of anatomic studies of the complex anatomy in this region (45,247). The posterolateral corner anatomy is key to understanding complex knee instabilities (223) (Fig. 15.15). Compared to the medial capsule, there is no distinct thickening of the capsule and less meniscal attachment. The lateral meniscus is much more mobile. An intraarticular structure, the popliteus tendon varies in its attachment to the meniscus and is a landmark for arthroscopic orientation much like the biceps of the shoulder. The popliteus originates on the tibia and inserts on the femur, which is opposite from all other muscles with origins proximal and insertions distal. The popliteus attaches to the distal and posterior aspect of the lateral condyle, and courses obliquely through an opening be-



**FIG. 15.12.** The medial ligaments of the knee: anteroposterior view. (Reprinted with permission from ref. 16.)



**FIG. 15.14.** Cross section demonstrating the layered approach to anatomy of the lateral aspect of the knee. Numerals I, II, and III designate layers 1, 2, and 3. (Reprinted with permission from ref. 223.)



**FIG. 15.15.** The posterolateral corner of the knee. (Reprinted with permission from ref. 223.)

tween the lateral meniscus and the capsule. Fibers may originate from the posterior meniscus and fibula. The popliteus functions to stabilize the posterolateral corner in flexion and govern the movement of the lateral meniscus.

## Menisci

The menisci are semicircular fibrocartilaginous structures between the tibia and the femur (16,146). Meniscal shapes and attachments to PCL and medial capsule are shown by bird's eye view (Fig. 15.16). The functions of the menisci are to increase conformity and transfer stresses between tibia and femur, increase stability, provide shock absorption and cartilage nutrition, and reduce articular cartilage wear (248). The importance of load transmission has been demonstrated in follow-up in patients who have had an arthrotomy and total meniscectomy (63,230,239). Following subtotal medial meniscectomy, radiographs show progressive joint narrowing, sclerosis and progressive varus deformity over time. In the ACL deficient knee, the medial meniscus does provide stability. The medial meniscus reduces anterior displacement of the tibia on the femur (64). The lateral meniscus covers a large portion of the lateral compartments. Meniscectomy changes these forces (127).

Made of type I collagen and fibrocartilage, the menisci are wedge-shaped in cross section and wider at the periphery, which allows the curved femoral surface to better conform to the flat tibia. The menisci are not rigidly fixed to the tibia, which allows them to conform to the different surfaces and varying radius of curvature of the femoral surfaces at varying angles of flexion (12).

The medial meniscus is more tightly attached than the lateral meniscus, which may be a factor in the increased incidence of isolated medial meniscus tears. It is "C" shaped and covers the concave plateau. The lateral meniscus is more oval or "O" or "U" shaped and covers a larger area of the more convex lateral plateau. The lateral meniscus is more mobile with less peripheral attachment and variable anatomy at the popliteus hiatus.

The primary nutrition for the menisci comes from the synovial fluid by diffusion. The cyclical compression and decompression of the meniscal fibrocartilage causes the synovial fluid to flow in and out of the meniscus. Peripheral vascularity is present only in the outer 25% to 30% of the meniscus (12). Blood supply is from the periphery through the medial and lateral geniculate arteries, which supply radial branches from the capsule. In fetal development, the blood supply extends more centrally but with aging is peripheral only. Therefore, only tears in the peripheral third or vascular red/white junction are most amenable to surgical repair.

## Cruciate Ligaments

Crossing in the intercondylar notch, the anterior cruciate ligament (ACL) and posterior cruciate ligament (PCL) are intraarticular and extrasynovial. The tibial and femoral attachments of the ACL and PCL are important for understanding function and principles of surgical reconstruction. The ACL and PCL attachment points on the tibia and femur have been well described by Girgis (81). The ACL is divided into two bundles based on location on the tibia, the anterior medial bundle (A-A') and posterior

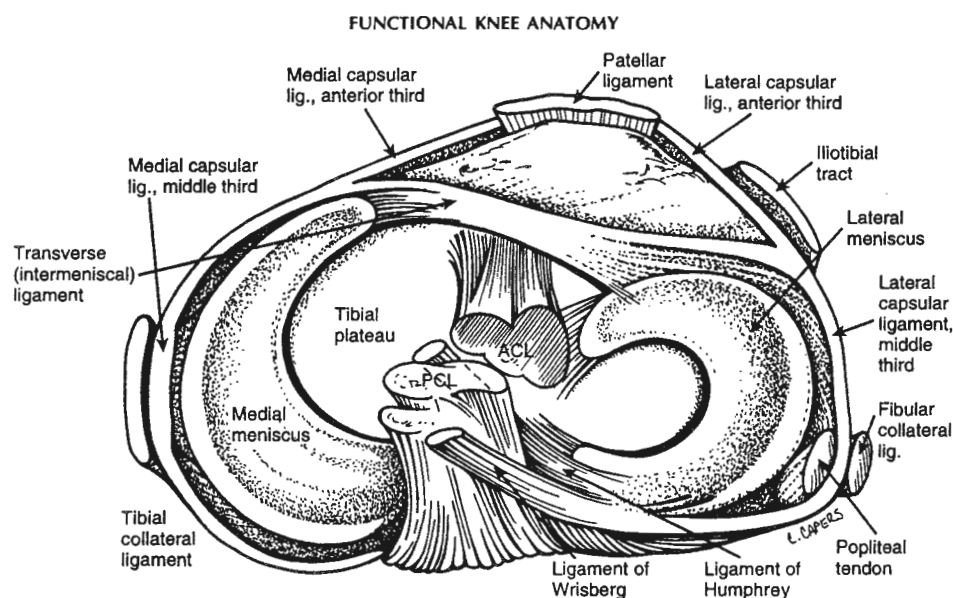
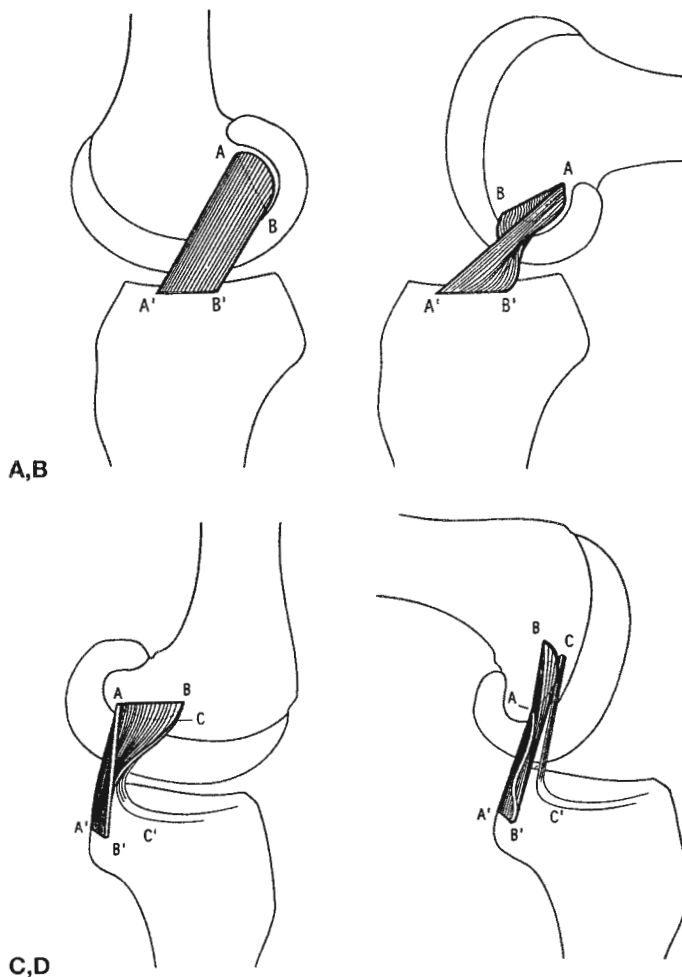


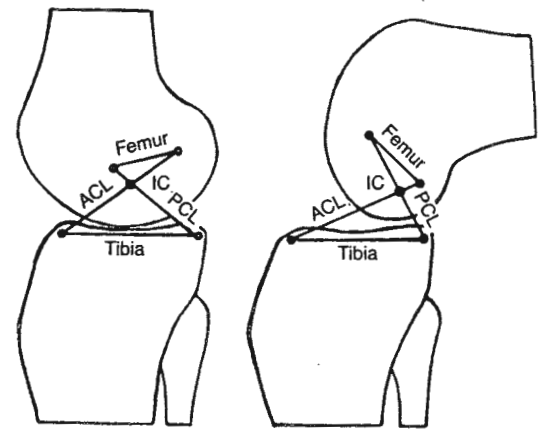
FIG. 15.16. An overhead view of the menisci shows the ligamentous attachment by the transverse ligament and the ligaments of Humphrey and Wrisberg. (Reprinted with permission from ref. 16.)

lateral bundle (B-B'). In extension, the intraarticular length is 30 mm and attachment on the femur is in a  $4 \times 23$  mm area, just 4 mm anterior to the posterior wall of the lateral femur. Both bundles are tight in extension (Fig. 15.17A) but only the anteromedial bundle is tight in flexion (see Fig. 15.17B).

The PCL is much broader than the ACL, attaches on the tibia in an “over-the-bottom” position 13 mm below the articular level on the posterior tibia in the fovea. Bundles have been described based on naming attachments on the tibia and the femur. Girgis described the attachments on the tibia as the anterior or bulk bundle, the small or posterior bundle, and ligaments of Humphrey and Wrisberg (see Fig. 15.17C,D). In extension, the small bundle is taut and the bulk bundle is loose. The bulk of

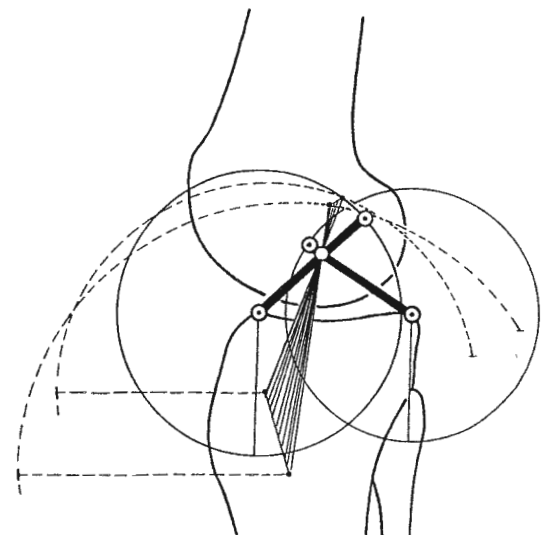


**FIG. 15.17. A,B.** Schematic drawing representing changes in the shape and tension of the anterior cruciate components in extension and flexion. In flexion lengthening of small medial band (A-A') and shortening of the bulk of the ligament (B-B'). **C,D:** Schematic drawing representing changes in the shape and tension of the posterior cruciate components in extension and flexion. In flexion lengthening of the bulk of the ligament (B-B') and shortening of small band (A-A'). C-C' is the ligament of Humphrey attached to the lateral meniscus. (Reprinted with permission from ref. 81.)

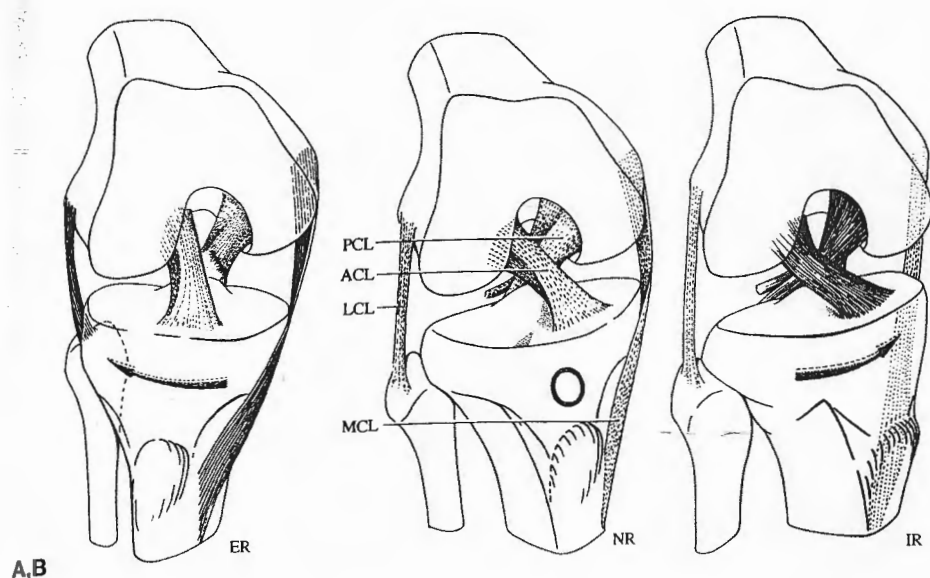


**FIG. 15.18.** The four-bar cruciate linkage model. The model includes two *crossed bars*, which represent the anterior and posterior cruciate ligaments (ACL;PCL). The remaining two *bars* represent the tibial and femoral attachments of the ligaments. IC, instantaneous center of joint rotation. (Reprinted with permission from Hefzy MS, Grood ES. Review of knee models. *Appl Mech Rev* 188;41:1–13.)

the PCL is loose in extension and becomes tight at 30 degrees flexion (see Fig. 15.17C). Newer anatomic definitions label the bands off of the femur. The PCL attachment to the femur measures 30 mm (81,90). The bands based on names from the femur are anterolateral and posteromedial. The posteromedial band tightens in knee extension, and the anterolateral band tightens in knee



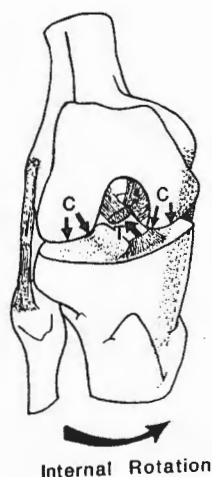
**FIG. 15.19.** The circular paths of motion of the anterior cruciate ligament are indicated by solid lines. The smaller circle is traced out by the shorter posterior cruciate ligament, and the larger circle by the longer anterior cruciate. The broken lines show the paths of the anterior and posterior edges of the medial collateral ligament and indicate a smaller circle for the fibers that insert anteriorly on the tibia and a larger circle for those that insert posteriorly. (Reprinted with permission from ref. 175.)



**FIG. 15.20.** Besides their synergistic functions, the cruciate and collateral ligaments also exercise a basic antagonistic function during rotation. **A.** In ER it is the collateral ligaments which tighten and inhibit excessive rotation by becoming crossed in space. **B.** In NR none of the four ligamentous structures is under unusual tension. **C.** In IR the collateral ligaments become more vertical and so are lax, while the cruciate ligaments become coiled round each other and come under strong tension. (Reprinted with permission from ref. 175.)

flexion. The anatomic sites on the femur have been described arthroscopically (174). The anterolateral band attaches on the femur 13 mm posterior and 13 mm inferior to the articular surface. The posteromedial band attaches 8 mm posterior and 20 mm inferior to the articular surface of the femur. The importance of these two femoral attachments is best appreciated by inability to successfully reduce all posterior translation by the present "single tunnel" reconstruction techniques (90,174).

A four-bar linkage system is formed by the ACL, PCL, femur, and tibia (23,52,175,191) (Fig. 15.18). The intersection centrally represents the instant center of the joint in



**FIG. 15.21.** Internal rotation of the tibia relative to the femur. The internal rotation causes the femoral condyles to ride up on the tibial spine, producing tension in the cruciate ligaments and a compressive force across the articular surfaces. **C**, the compressive force produced between the tibiofemoral articular surfaces; **T**, the tensile load developed along the anterior cruciate ligament. (Reprinted with permission from ref. 57.)

the sagittal plane. The cruciate ligaments and fibers change shape during flexion and extension. With rotation, the bony femoral and tibial lengths change. Reconstructive surgery must restore this four bar linkage system with appropriate tunnel placement on the femur and tibia and ligament tautness. All ligamentous elements contribute to the principles of the Burmester curve, a model for describing the complex kinematics of the knee joint (175). Numerous reviews of the principles of the Burmester curve are necessary for a full understanding. This complex model emphasizes the importance of a thorough knowledge of basic anatomy and restoration of normal instant centers, in an attempt to recreate normal knee function. During rotation, the cruciate and collateral ligaments act antagonistically. With tibial external rotation, the collateral ligaments tighten to prevent excessive rotation (Fig. 15.19). In neutral tibial rotation, none of the four ligamentous structures are under excessive tension. In internal rotation, the cruciate ligaments become coiled around each other and are under significant tension (Fig. 15.20). When analyzing mechanisms of injury such as a noncontact ACL tear, many factors should be viewed. With internal rotation of the tibia, the ACL is under significant tension. If weight bearing has occurred, there is compression under tension, which will result in potential failure. If the joint is loaded, there are significant compression forces in the medial and lateral compartments, resulting in meniscal or articular surface injury (Fig. 15.21).

The menisci move posteriorly in flexion and anteriorly in extension. There is more movement of the lateral meniscus. The menisci also move with rotation as the knee flexes (175). During external rotation, the femoral condyle moves the medial meniscus posteriorly and the lateral meniscus anteriorly at a much greater distance. During femoral condyle internal rotation, the medial meniscus is displaced anteriorly and the lateral meniscus is displaced posteriorly at a much greater distance. Because of the

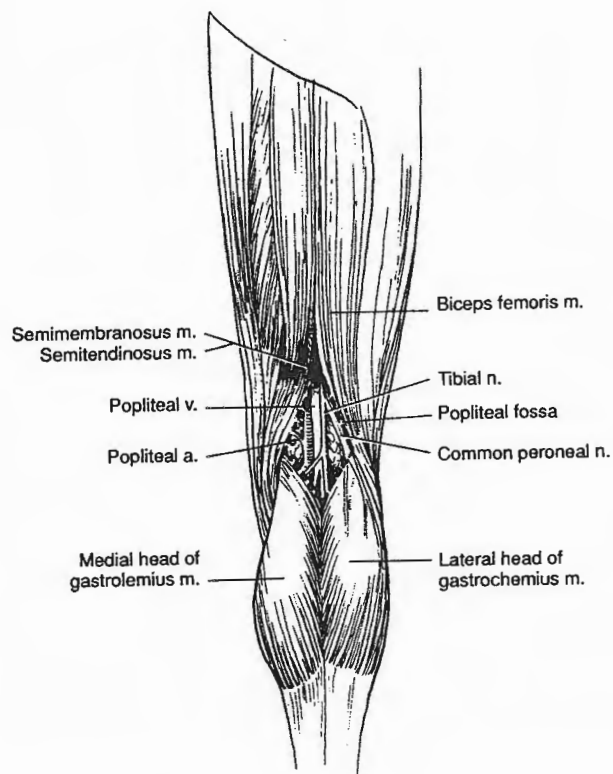
meniscal role as a stabilizer and shock absorber, restoration of these particular movements during surgical reconstruction with attempts to save the meniscus must be performed.

Principles of restoring the knee to its normal function are based on anatomic reattachments of all ligaments and preserving the menisci. If ligaments are not anatomically positioned, risks of abnormal joint kinematics and stretching out of the reconstruction exist.

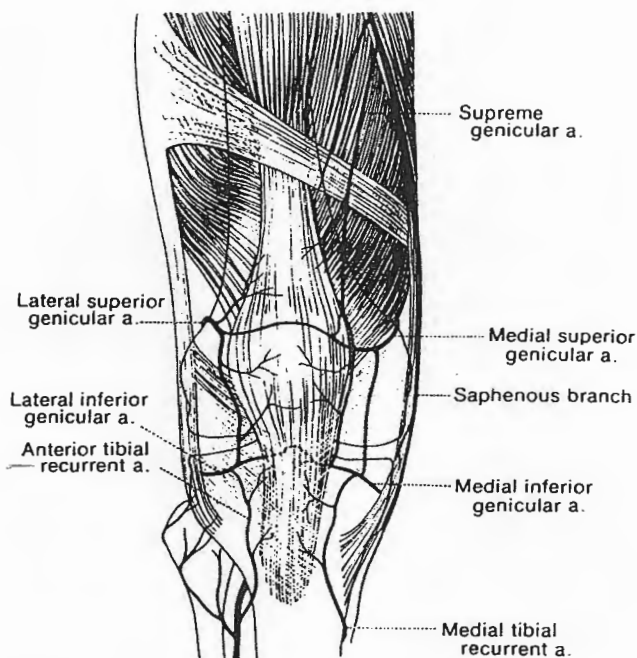
## NEUROVASCULAR STRUCTURES

### The Popliteal Fossa

The structures in the popliteal fossa include the popliteal artery and vein, tibial nerve, and common peroneal nerve (Fig. 15.22) (224). A branch of the femoral artery, the popliteal artery lies directly on the posterior capsule, secured proximally at the adductor hiatus. In knee dislocations, careful neurovascular assessment must be done. There is risk of inimal arterial or venous injury (by stretch or puncture) or deep venous thrombosis. The blood supply to the ACL, PCL, and posterior capsule is the middle genicular artery, a branch of the popliteal artery. The



**FIG. 15.22.** Popliteal fossa contents include popliteal artery and vein, tibial and common peroneal nerves. The borders are bone and capsule anteriorly, medial hamstring and medial gastrocnemius and laterally biceps femoris and lateral gastrocnemius. (Reprinted with permission from ref. 57.)



**FIG. 15.23.** The branches of genicular arteries provide the blood supply of the patellofemoral joint. The lateral genicular artery is at risk when a lateral release is performed. (Reprinted with permission from ref. 77.)

anastomosis of genicular arteries (medial superior, medial inferior, lateral superior, and lateral inferior provide the blood supply to the patella (77) (Fig. 15.23). The lateral superior genicular artery is usually sacrificed during a lateral release. Four nerves cross the knee joint: saphenous, peroneal, tibial, and sural. The saphenous nerve pierces through the medial hamstrings and branches into the infrapatellar branch, as it becomes more superficial, emerging through the semimembranosus. Branches of the saphenous nerve can be injured during medial meniscal repairs, resulting in reduced sensation from the medial calf to the ankle (see Fig. 15.10). The peroneal nerve is at the most risk with lateral meniscal repairs and injuries involving the proximal fibula and posterolateral corner of the knee. Pre- and postoperative assessment of peroneal nerve function including assessment of dorsiflexion strength and sensation on the dorsum of the foot should be standard practice.

## PHYSICAL EXAMINATION OF THE KNEE

The examiner must develop a systematic and routine approach to a knee evaluation (16,69,235). After a detailed history has been obtained, one should have several specific diagnoses in mind. Allow the patient to demonstrate the functional problem. If pain is caused by the patient, it is much more easily accepted by them. If you anticipate a potentially painful test, that test should be



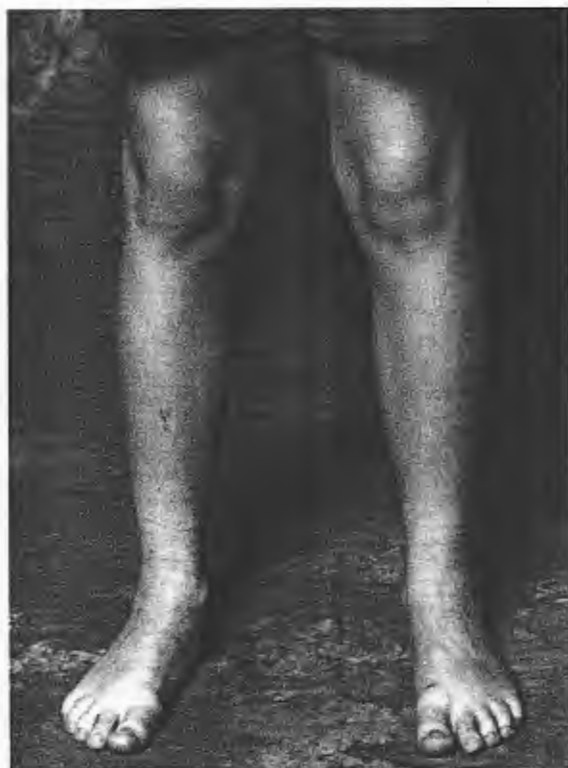performed at the end of your exam. For example, if the patient has a potential meniscus tear, then the provocative meniscal tests should be performed after ligamentous testing. Observation of gait, standing alignment, documentation of active and passive range of motion, particularly any differences in extension, should be routinely performed.

### Physical Examination—Normal Knee

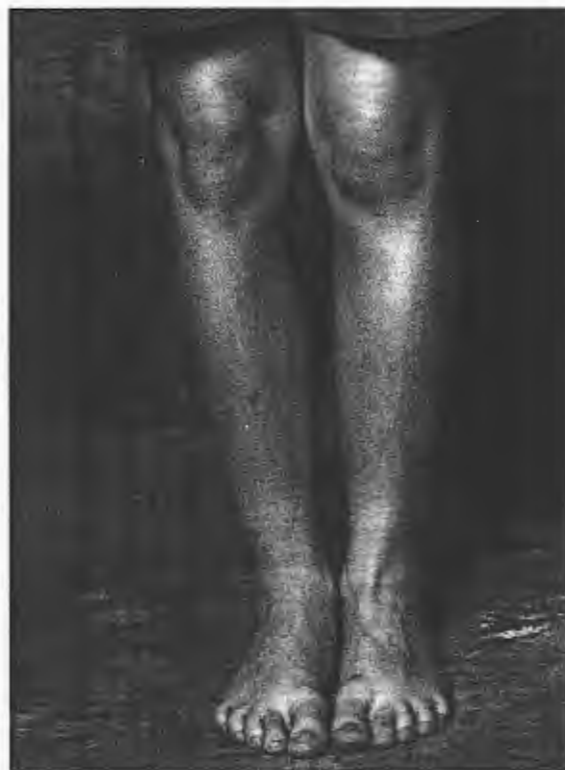Have the patient stand to observe his or her natural alignment, muscle definition, knee joint position, and ankle and foot flexibility and position (Fig. 15.24). In the “feet together” stance, better assessment of the femoral anteversion, patellar orientation, and alignment is shown (Fig. 15.25).

Assessment of the posterior tibialis function and foot alignment should routinely be performed. As the patient rises up on his or her toes, the heel should naturally invert (Fig. 15.26). Posterior tibialis tendon rupture is rare in the young athlete; however, posterior tibialis dysfunction is common secondary to painful inhibition.

With the patient standing, observation of squatting maneuvers is helpful in assessment of patellar tracking and meniscal function. Squatting in hyperflexion with the feet



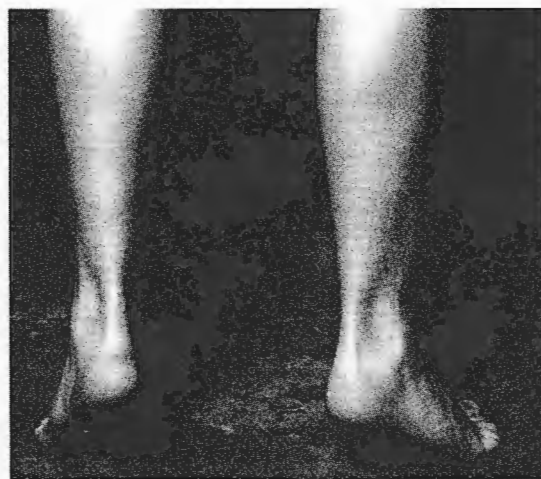**FIG. 15.24.** This 10-year-old patient was asked to stand naturally. He demonstrates a valgus attitude, feet apart for balance, hindfoot in valgus, forefoot pronation.



**FIG. 15.25.** In the foot-together stance, better assessment of the femoral anteversion, patellar orientation, and alignment is shown.

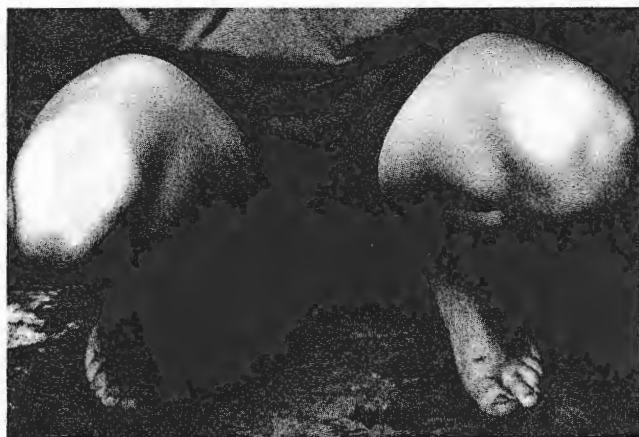pointed straight can help localize the pain, specifically to anterior, medial, or lateral aspect of the knee (Fig. 15.27).

Assessment of the medial meniscus is best done with the feet and tibia externally rotated while palpating the medial joint line (Fig. 15.28, *arrows*). If there is pain in this position, specifically over the medial joint line, this is indicative of a medial meniscus tear. In the “snow-



**FIG. 15.26.** As the patient goes up on his toes, the heel should naturally invert, indicative of normal posterior tibialis tendon function.

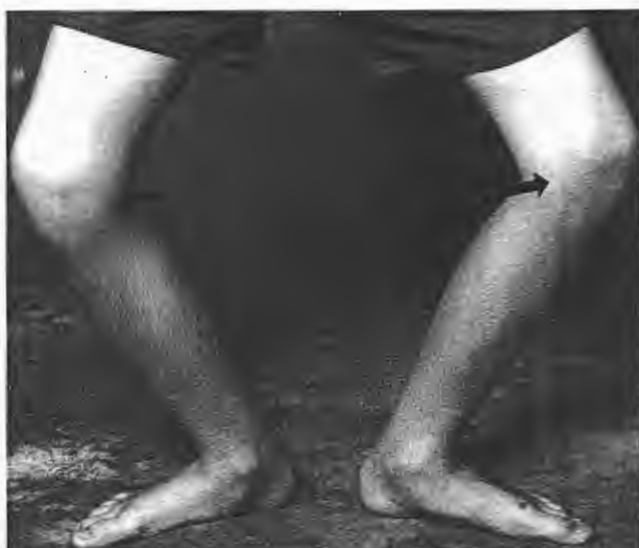



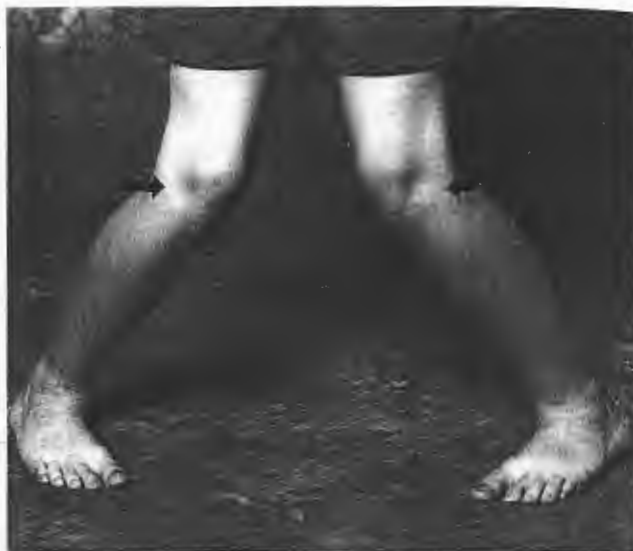**FIG. 15.27.** Squatting in hyperflexion with the feet pointed straight can help localize the pain, whether it is anterior, medial, or lateral.

plow" or internally rotated position with the feet maximally apart, the lateral compartment is loaded and painful popping may indicate a lateral meniscus tear (Fig. 15.29, arrows).

With the patient sitting on the table, Q angle measurements, palpation of the patella, and observation of patellar tracking with resistive testing of active extension should be performed (Fig. 15.30). The Q angle is measured from the anterior superior iliac spine to the center of the patella—to the center of the tibial tubercle. A Q angle measurement can be performed in several positions—standing, 30 degrees flexed, supine 0 degree, and 90 degrees flexion. A "J" sign indicates patellar maltracking. This occurs at about 30 degrees when the patella is centralized in the trochlear groove, then incongruently jumps laterally



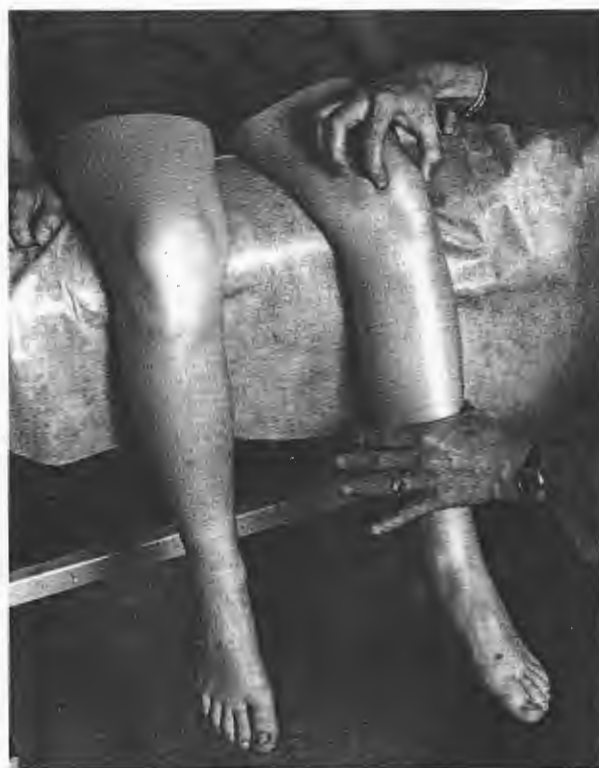**FIG. 15.28.** Assessment of the medial meniscus is best done with the feet and tibia externally rotated and palpating the medial joint line (arrows).



**FIG. 15.29.** Snowplow or internally rotated position with the feet maximally apart loads the lateral joint line (arrows).

as the knee goes into further extension. This is best observed when having the patient actively extend against the examiner's hand. Always compare to the opposite, normal knee.

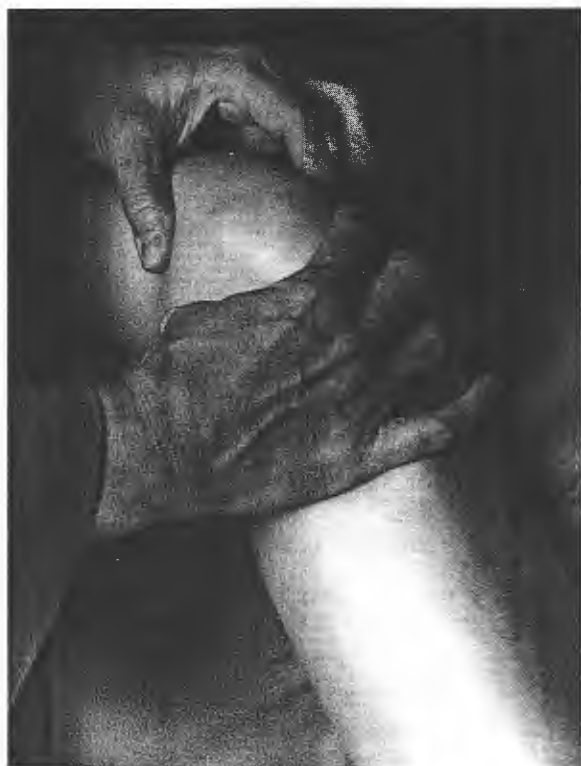After comparing range of motion, palpation of the joint



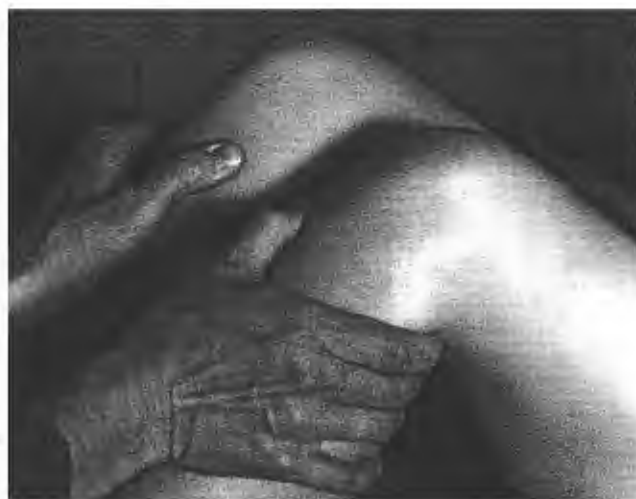**FIG. 15.30.** Patient sitting on the table, Q angle measurements, palpation of the patella, observation of patellar tracking with resistive testing of active extension should be performed.

line, tibial tubercle, inferior pole of the patella, quadriceps insertion, medial, and lateral patellar facet should be done. The apprehension test for patellar subluxation is performed with the knee at 30 degrees of flexion (Fig. 15.31). Assessment of lateral retinacular tightness should also be done. Move the patella to estimate quadrants of movement medially and laterally.

The medial tibial plateau is usually 5 to 8 mm anterior to the medial femoral condyle. Palpation of this should be done to determine integrity of the PCL (Fig. 15.32). If the PCL is involved, the medial tibial plateau will be in a more posterior position compared to the normal 5 to 8 mm anterior location. Anterior drawer test is performed in neutral, internal, and external rotation with positive pulling of the tibia forward (Fig. 15.33). Palpate the hamstrings to make sure they are relaxed. Perform a drawer test with rotation, pushing the tibia posterior in an externally rotated position to assess the laxity of the posterolateral corner. Always compare both sides starting with the uninjured site. In the 90-degree knee-flexed position, there is often significant "normal" physiologic movement of the lateral tibial plateau both posterolaterally and anterolaterally. The Lachman test is performed with the knee in 30 degrees flexion pulling the tibia forward and keeping the femur stationary. The Lachman test is more reliable, especially in the acute setting because the hamstrings are in a less favorable position to resist anterior and directed force than the 90 degree flexed anterior drawer position.

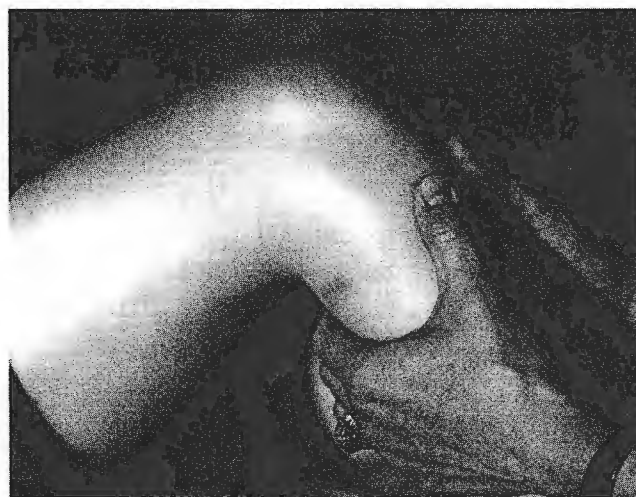

**FIG. 15.31.** Apprehension test for patellar subluxation is performed with the knee at 30 degrees of flexion.




**FIG. 15.32.** Assessment of lateral retinacular tightness should also be done and the estimate based on quadrants of movement. The medial tibial plateau is usually 5–8 mm anterior to the medial femoral condyle. Palpation of this should be done to determine integrity of the posterior cruciate ligament (PCL).

There are many variations of the pivot shift maneuver. Descriptions of various pivot shift maneuvers have been described by numerous authors (78,99,131). The flexion rotation drawer, or reduction, test is performed from extension to flexion (179,232). The subluxation test is performed from flexion to extension (152). The most comfortable way to stabilize the leg to perform a pivot shift is by letting the patient's calf rest on the forearm and apply an axial load along with gentle tibial internal rotation using that arm. The opposite hand pushes the proximal tibia forward with the forces directed more anteriorly than toward internal rotation. If the ACL is injured, a shifting is felt at 40 degrees as the lateral tibial plateau



**FIG. 15.33.** Anterior drawer test is done in neutral, internal, and external rotation.



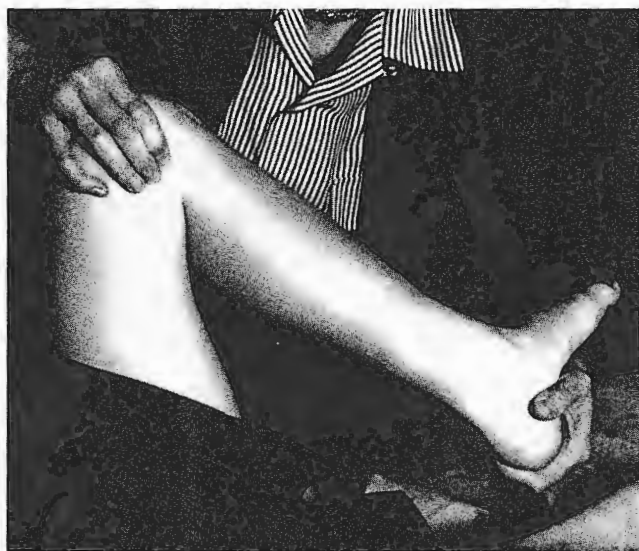**FIG. 15.34.** In a subluxation test, the knee is taken from flexion to extension. **A:** At 30–40 degrees if the anterior cruciate ligament (ACL) is injured, a clunk or shifting is felt. **B:** The lateral tibial plateau (arrow) is shown subluxing in physiologically pivot glide.

subluxes (Fig. 15.34A). A physiologically normal pivot glide is shown in this subluxation pivot shift test (see Fig. 15.34A). The lateral tibial plateau is reduced at 60 degrees flexion and glides forward at 30 degrees flexion (see Fig. 15.34B, arrows).

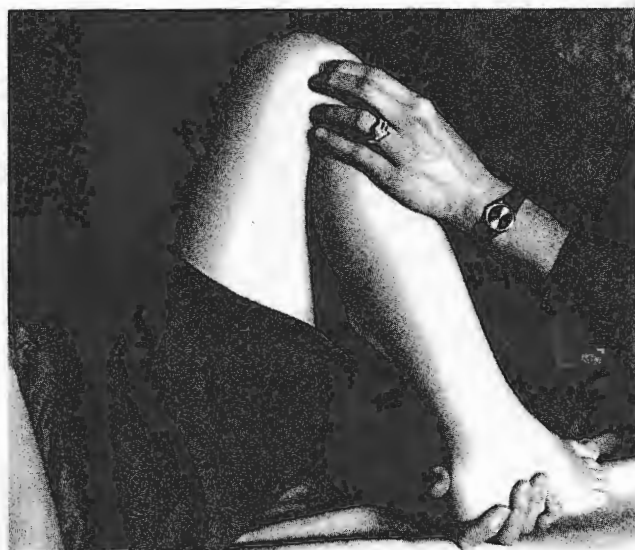McMurray's test is performed by rotating the tibia externally in hyperflexion for medial meniscus tear and internal rotation for lateral meniscus tear. Palpate the joint line for popping (168) (Fig. 15.35). If pain and popping over the joint line is reproducible, particularly in hyperflexion with an axial load, the exam indicates a probable meniscal tear. A bounce home test is performed by grab-

bing the heel and gently extending the knee. A positive test will result in pain if there is a posterior horn tear in the medial meniscus. The more common location for a lateral meniscus tear is within mid-third. With the knee flexed, a small localized cyst associated with pain on palpation is often seen (Fig. 15.36).

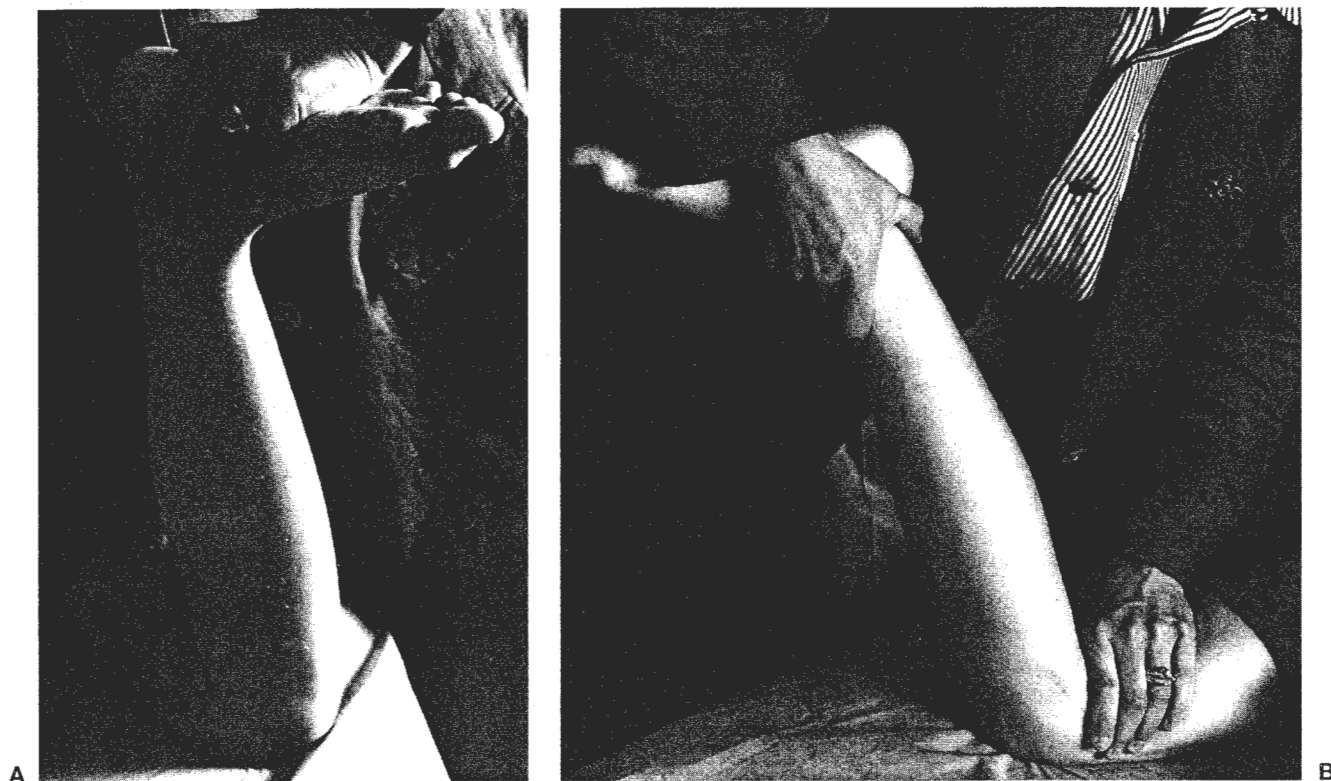
Apley's compression test is performed with the patient prone, applying axial or compressive load and external rotation, while palpating the medial joint line (Fig. 15.37A). A distraction test will help identify more capsular and medial collateral ligament sprains by stabilizing the thigh and pulling up on the foot and palpating the ligament (see Fig. 15.37B).



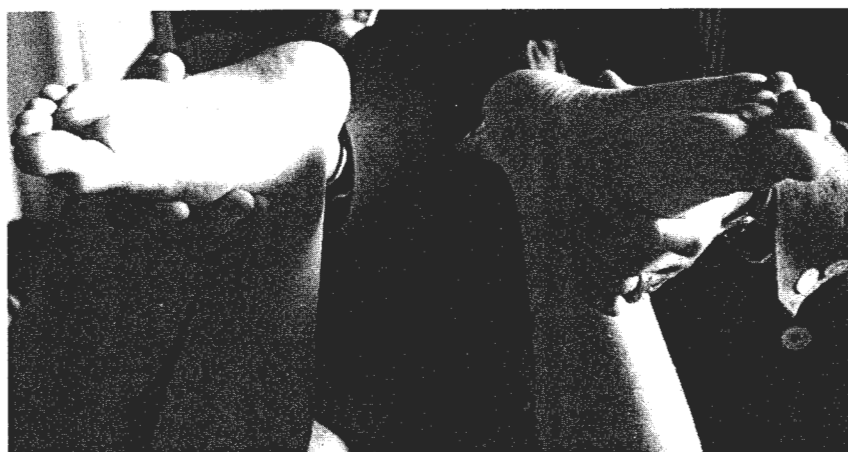**FIG. 15.35.** McMurray's test is performed hyperflexing the knee while palpating the joint line being stressed for medial hyperflexion external rotation, and for lateral hyperflexion internal rotation.



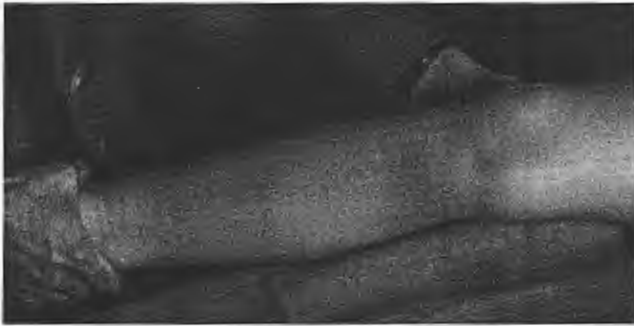**FIG. 15.36.** Apley's compression test with palpation of the lateral joint line for a cyst.



**FIG. 37.** **A:** Apley's compression test is performed with the patient prone, applying axial load and external rotation, while palpating the medial joint line. **B:** Palpation of the medial joint line while loading the foot in external rotation. Distraction tests will help identify more capsular and medial collateral ligament sprains by stabilizing the thigh and pulling up on the foot and palpating the ligament.



**FIG. 15.38.** While supine, any excessive rotation of the feet or an asymmetry will identify posterolateral corner injury.



**FIG. 15.39.** With Lachman or varus-valgus, the leg can be rested on the examiner's leg or held over the side of the table testing the medial side at 30 degrees for medial opening.

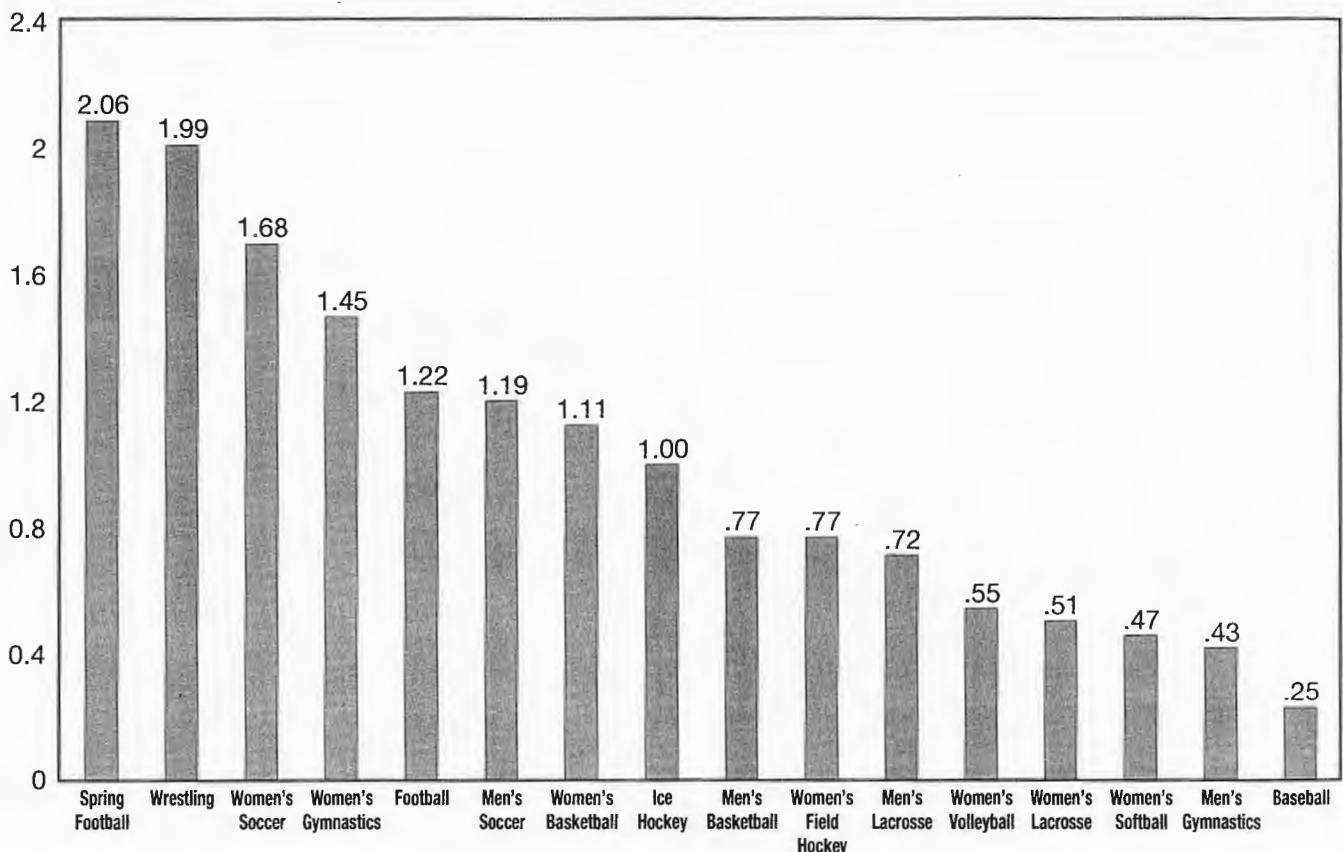
A prone comparison is done to look for any excessive rotation of the feet or asymmetry that could identify a posterolateral corner injury (Fig. 15.38). Varus-valgus testing for ligamentous stability is performed at both 0 degrees and 30 degrees. Varus-valgus testing is done with the leg resting on the examiner's leg or held over the side of the table testing the medial side at 30 degrees by abduction/adduction forces (Fig. 15.39).

## DISORDERS AND INJURIES

### Epidemiology of Injury

The National Collegiate Athletic Association (NCAA) runs an injury surveillance system where 18% of member institutions, division I, II, and III, are polled (176). The athletic training staff completes an injury questionnaire for 16 sports—spring football, wrestling, women's soccer, women's gymnastics, football, men's soccer, women's basketball, ice hockey, men's basketball, women's field hockey, men's lacrosse, women's volleyball, women's lacrosse, women's softball, men's gymnastics, and baseball. The injury rates are reported as the number of injuries per 1,000 athletic exposures. The averages over a three-year period, beginning 1993 to 1994, ending in 1995 to 1996 are shown (Table 15.1). For overall knee injury rates, spring football is the highest at 2.06, then wrestling (1.99), women's soccer (1.68), women's gymnastics (1.45), and football (1.22). Statistics are completed in different categories. ACL and meniscus injuries rates are shown (Table 15.2). No determination of contact versus noncontact is made in this initial format. The top six ACL injury sports were

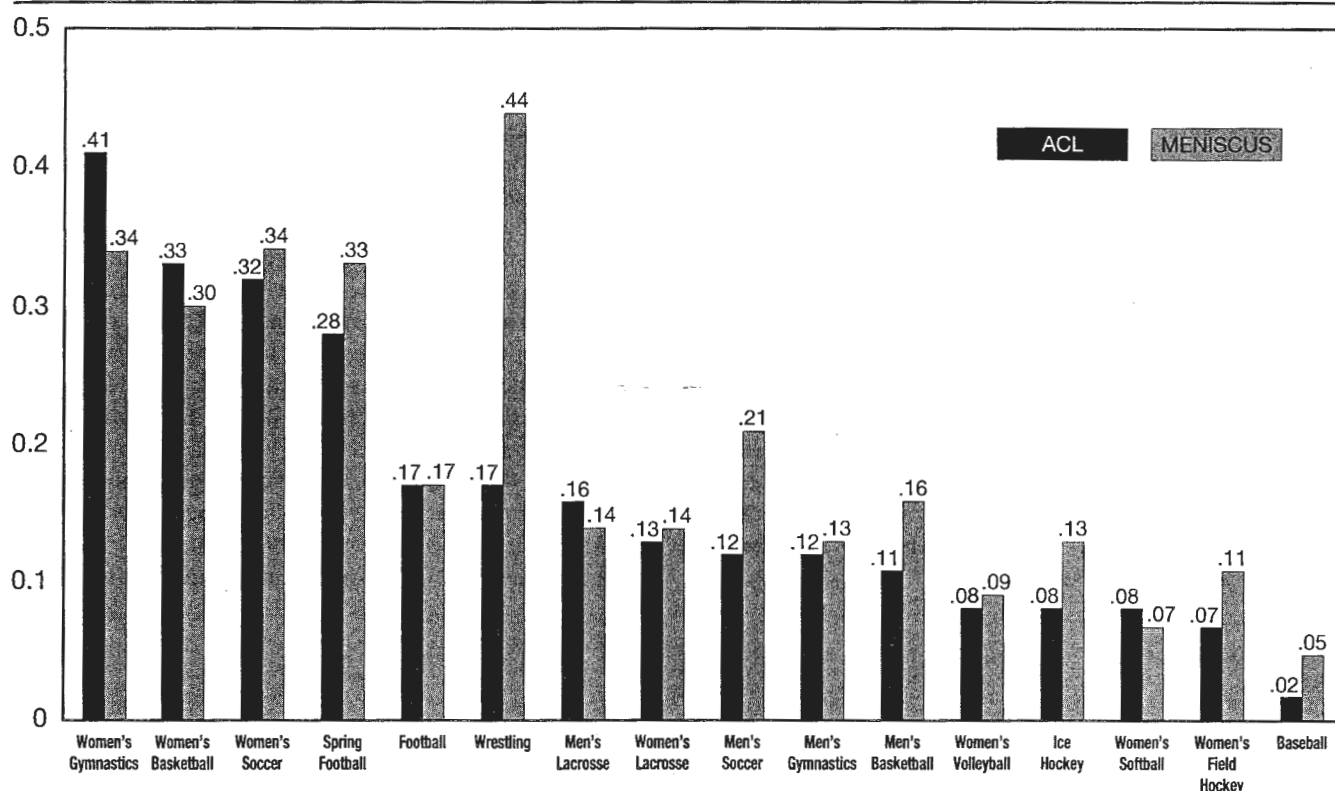
**TABLE 15.1** NCAA injury rates: knee



Average injury rates per 1,000 athletic exposures, 1993–1994 through 1995–1996 seasons.  
Data from NCAA Injury Surveillance System. Graphic © 1997, Mary Lloyd Ireland, M.D.



TABLE 15.2 NCAA injury rates: ACL, meniscus



Average injury rates per 1,000 athletic exposures, 1993–1994 through 1995–1996 seasons. Data from NCAA Injury Surveillance System. Graphic © 1997, Mary Lloyd Ireland, M.D.

women's gymnastics (.41), women's basketball (.33), women's soccer (.32), spring football (.28), football (.17), and wrestling (.17). The top five sports rates for meniscal injury were wrestling (.44), women's gymnastics (.34), women's soccer (.34), spring football (.33), women's basketball (.30) (176). An NCAA study comparing men's and women's soccer and basketball divided the mechanism of contact, noncontact, collision of ACL injuries over five years, 1989 to 1993. The ACL injury rate in women was 4.1 times greater in basketball and 2.4 times greater in soccer compared with men (11).

Three high school level epidemiology studies from the San Antonio area have been done for the three sports of girls' basketball, boys' basketball, and boys' football. The need for knee surgery was greater and injury rates greater in girls' basketball than boys' football or boys' basketball (26,56,82,83,109,116,265) (personal communication—DeLee J).

An assessment of knee injuries was performed at the Olympic Trials in 1988 (109). Eighty male and 64 female elite athletes tried out for the U.S. team. Female athletes had a statistically significant increase in both knee injuries and the need for surgery in comparison to their male counterparts. Twenty female athletes underwent 25 knee surgeries with 13 of the surgeries be-

ing for the ACL. Six male athletes underwent six knee surgeries with three of the surgeries being for the ACL. Other operative findings are shown (Table 15.3). Male and female injury rates in the military are equalizing (47). Injury rates of the knee comparing genders have been published for flag football (42), basketball (11,82,

TABLE 15.3. Injuries sustained during 1988 Olympic basketball trial

Parameter	Males	Females	Total
Number of participants	80	64	144
Athletes with knee injuries	11 <sup>a</sup>	34	45
ACL injuries	3	13	16
Number of athletes requiring surgery	6 <sup>b</sup>	20	26
Number of procedures	6	25	31
Type of procedure			
Arthroscopy	3	17	20
ACL reconstruction	3	8	11

<sup>a</sup> Statistically significant  $p < 0.0001$ .

<sup>b</sup> Statistically significant  $p < 0.0007$ .

Abbreviations and symbols: ACL, anterior cruciate ligament; <sup>a,b</sup> indicate a statistically significant difference between male and female athletes (<sup>a</sup> =  $p < 0.0001$ , <sup>b</sup>  $p < 0.0007$ ).

Reprinted with permission from Adis International Limited, Auckland, New Zealand.

83,91,116,156,176,266), and other sports (56,252). Comparisons of many sports with regard to injuries and contributing factors have been explored (55,87,107,117,205) (Fig. 15.40).

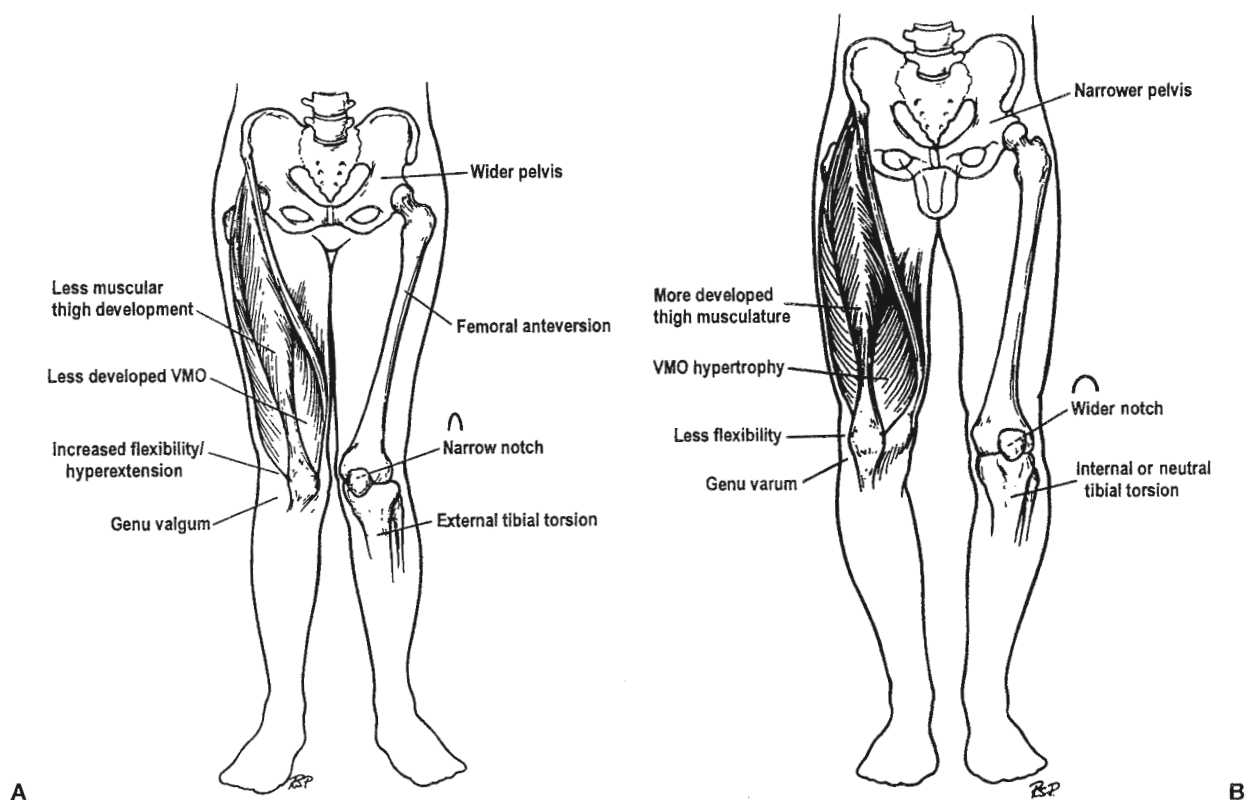
Anatomical differences between males and females may contribute to increased ACL injury rates. Differences can be divided into intrinsic–nonchangeable, extrinsic–changeable, or combinations of both. Alignment factors are intrinsic and not significantly changeable. The female lower extremity alignment typically has a wider pelvis, increased femoral anteversion, genu valgus, narrower notch, and external tibial torsion relative to the increased femoral internal rotation, and pronation (see Fig. 15.40A). This compares to the male alignment typically shown with a narrow pelvis, wider notch, neutral or varus knee, and internal or neutral tibial torsion (see Fig. 15.40B). From the muscular standpoint, the female has less muscular development, less developed vastus medialis obliquus, increased flexibility and hyperextension in valgus (see Fig.

15.40A) compared to the male with more developed thigh musculature, tight hamstrings, less overall flexibility and genu varum (see Fig. 15.40B). With malalignment, injury to the retinacular nerve has been documented histologically (72).

Intrinsic or not changeable differences are physiologic rotatory laxity, the size of the ACL, alignment, and hormonal influences. Extrinsic or potentially controllable factors include strength, conditioning, motivation, and shoe choices. Other factors include skill, coordination, position sense, neuromuscular firing order, and patterns–order of activation (119,120).

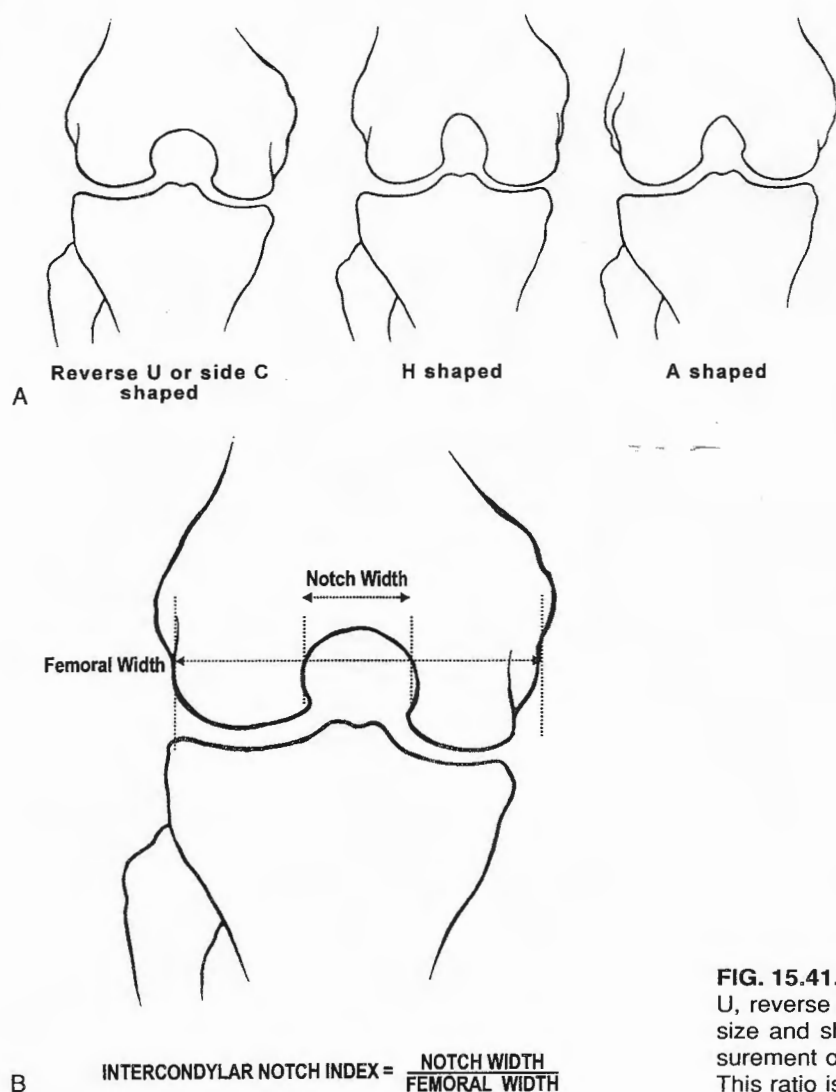
Differences in females that have been reported as a possible contributing factor in ACL injuries include later firing of the hamstrings and a different order of muscle component activation with quadriceps activity (108,109,119,120,149,150,260). Fatigue has also been shown to change the forces across the joints (43,189).

Measurement of the width of the notch is done routinely. The ratio of notch width at the popliteal hiatus



**FIG. 15.40. A:** Lower extremity anatomic alignment in female, showing wider pelvis, femoral anteversion, internal rotation, narrow femoral notch, genu valgum, less muscular development, increased flexibility, hyperextension, external tibial torsion, and pronated foot. **B:** Male lower extremity alignment is diagrammed with narrow pelvis, more developed thigh musculature, vastus medialis obliquus (VMO) hypertrophy, less flexibility, neutral genu varum, a wider femoral notch, and internal or neutral tibial torsion. (Reprinted with permission from ref. 69.)





**FIG. 15.41. A:** The varying shapes of the notch are shown, U, reverse C, H, and A. The notch forms in relation to the size and shape of the anterior cruciate ligament. **B:** Measurement of the distal femoral width to the notch is shown. This ratio is routinely measured.

to the width of the condyles is the notch width ratio (Fig. 15.41B). A ratio of less than 0.2 is indicative of a stenotic notch (237). With a stenotic notch, increased incidence of noncontact ACL injuries has been shown (136,237). The notch develops in relation to the ACL. Differing shapes, like C, or reverse U, H, and A are also seen (69,136,236,237) (see Fig. 15.41A). Absolute measurements of notch width in men show higher risk for ACL tear if less than or equal to 15 mm (228). Assessment by CT scan gives a more three-dimensional view (6). Hormonal influences are also a factor. Estrogen receptors are present on the ACL (149,150). The levels of estrogen vary during the cycle surging from day 6 and peaking at day 12 during the follicular phase. The menses are day 1 to 5. In a study of 28 females, ACL injuries were more likely to occur during days 10 to 14 (262).

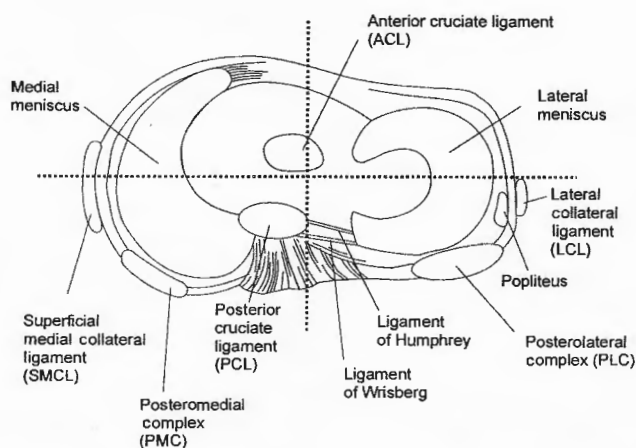
### Classification of Instability

Instability classification patterns have been discussed by many prominent individuals (8,99,138,153,175,182,184,233). Classification of knee instabilities is based on the degree, direction and duration of the injury. The grades are 1 to 4 when estimated by millimeters of opening: 1, less than 5 mm; 2, 5 to 10 mm; 3, 10 to 15 mm; 4, greater than 15 mm (3). Some degree of physiologic rotatory laxity, such as a pivot glide, is a normal variant; therefore, the pivot shift test is more difficult to grade in millimeters. The pivot shift is described as negative or positive. The Lachman test at 30 degrees flexion is graded as negative, positive with a soft end point, or positive with no end point. The medial and lateral joint line opening can be documented more easily with millimeters of joint opening. If one correlates the mechanism of injury with

the involved anatomic structures and the physical findings, it is much easier to describe the instability. The number of months from the time of injury is used to determine chronicity. Acute is less than three months and chronic is greater than three months from injury (183).

The term "ACL deficient knee" describes the ligament's absence; however, the functional disability that results from this injury is anterolateral rotatory instability and better describes the functional complaints. Excellent articles exist correlating the biomechanical principles of injury and anatomic cutting sections with the resultant instability (8,34,89,181).

Classification of knee instability is based on dividing the tibia into four quadrants and describing the motion of the tibia on the femur. For example, a torn ACL is described as anterolateral rotatory instability, meaning the lateral tibial plateau moves anteriorly. Instabilities are best understood when correlated with mechanism of injury, involved anatomic structure, and physical findings (175). The cruciates (ACL and PCL) are more central with axis of rotation more medial. The ligaments of Wrisberg and Humphrey attach the lateral meniscus to the PCL (Fig. 15.42). The knee is divided into quadrants—anteromedial quadrant (medial meniscus); anterolateral quadrant (lateral meniscus); posterolateral quadrant [lateral collateral ligament (LCL), popliteus, posterolateral complex (PLC), ligament of Humphrey, and ligament of Wrisberg]; and posteromedial quadrant [posterior cruciate ligament (PCL), posteromedial complex (PMC), and superficial medial collateral ligament (SMCL)]. The posteromedial complex (PMC) refers to the thickened medial capsular ligament, including the posterior oblique liga-



**FIG. 15.42.** Bird's-eye view of the tibia divides the tibia into four quadrants showing the important structures located in each quadrant: anteromedial (medial meniscus), anterolateral (lateral meniscus), posterolateral (lateral collateral ligament [LCL], popliteus, posterolateral complex [PLC], ligament of Humphrey, and ligament of Wrisberg, and posteromedial (posterior cruciate ligament [PCL]), posteromedial complex [PMC], and superficial medial collateral ligament [SMCL]). (Adapted and reprinted with permission from ref. 175.)

ment, the capsular arm of the semimembranosus, the oblique popliteal ligament and deep medial capsule, meniscotibial, and meniscotibial ligaments. The superficial medial collateral ligament (SMCL) lies anterior and superficial. The posterolateral complex (PLC) includes the arcuate ligament, fabellofibular ligament, popliteus tendon, popliteal fibular ligament, popliteal meniscal vesicles and thinner meniscotibial ligaments (PLC).

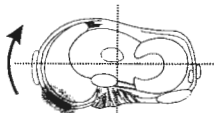
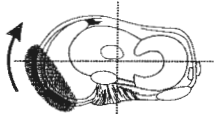
Correlating and understanding the anatomy to the mechanism of injury will give the language of classifying the functional instability of the knee. Instability is rotatory, straight or combined. The direction of movement of the tibia on the femur is anteromedial, anterolateral, straight posterior, posterolateral, straight medial, straight lateral, and straight posteromedial. The direction of the tibia on the femur provides the language of instability (Table 15.4). The shaded areas represent the injured structures. The diagnosis and grade of instability, involved anatomic structure, physical findings and the usual mechanism and direction of forces are shown in columns. Combined instabilities are common. Anteromedial rotatory instability (AMRI) usually occurs from a lateral blow on the tibia with the foot planted. The anterior drawer is positive in external rotation if the meniscotibial attachment is injured but the ACL can be intact. As the valgus force continues in the extended knee, further injury to the posteromedial capsule and involvement of the ACL occurs in the classic triad of O'Donoghue (192) involving tears of the MCL, medial meniscus and ACL. An anterior drawer in external rotation occurs with 2+ AMRI. The pivot shift may not be as significant if the medial stabilizing structures are injured, in that there is no post around which to pivot (see Table 15.4, Section 2).

In noncontact ACL injuries, it is common to see a lateral capsular sprain, usually off of the tibia. Think about the mechanism in noncontact sports of basketball or gymnastics (Fig. 15.43). The lateral tibial plateau shifts anteriorly and rotation occurs (see Table 15.4, Section 3). The position of no return occurs and the ACL fails. The knee buckles, the patient is usually falling forward and toward the opposite side in a rapid distal deceleration mechanism. The usual observed position is body forward-flexed and rotated, hip in internal rotation and adduction, the knee slightly flexed and in valgus and tibia externally rotated and foot pronated. With more severe force, continued internal rotation of the tibia, and increasing medial contact, there will be a more severe instability, which involves the posterolateral complex (Table 15.4, Section 3).

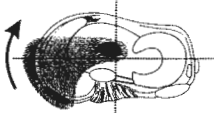
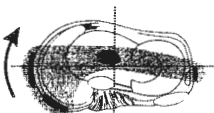
PCL injuries are much less common than ACL injuries (176). Straight posterior instability indicates a tear of the PCL with or without involvement of the ligaments of Humphrey and Wrisberg attaching the posterior horn of the lateral meniscus to the PCL anteriorly and posteriorly respectively (see Table 15.4, Section 4) (175).

The "tetrad" injury and posterolateral instability includes injury to the popliteus corner, PCL, posterior

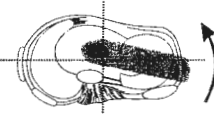
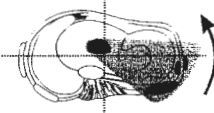
**TABLE 15.4** Classification of knee instabilities: rotatory, straight, or combined**Section 1. Anteromedial rotatory instabilities (AMRI)**

Diagnosis	Diagram	Involved anat. structure	Physical findings	Mechanism and forces
1+		PMC	1+ AD in ER	Contact: Lateral Force: Valgus
2+		PMC SMCL	1+ AD in ER 1+ — 2+ Valgus 30°	Contact: Lateral Anterior Forces: Valgus Extension Tibia ER

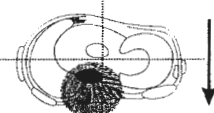
**Section 2. Combined AMRI and ALRI**

3+		PMC SMCL ACL	3+ AD in ER 2+ AD in N 2+ Valgus 30°	Contact: Lateral Forces: Valgus Extension Tibia ER
4+		PMC ACL PLC	3+ AD in ER 2+ AD in NR 2+ Valgus at 30° 1+ Recurvatum 1+ PS	Contact: Lateral Forces: Valgus Rotation Extension

**Section 3. Anterolateral rotatory instabilities (ALRI)**

1+		ACL Lateral Capsule	+ AD in N and Tibial IR PS	Noncontact Forces: Rotation Foot Planted
2+		ACL LCL PLC	+ AD + IR + Lachman + PS 1+ Varus 30°	Noncontact or Contact: Medial Forces: Varus Extension Tibia IR

**Section 4. Straight posterior**

Posterior		PCL ± Humphrey ± Wrisberg	PD 90° Neutral	Contact: Proximal Anterior Tibia Force: Posterior on Tibia Flexed or Hyperextension
-----------	---	---------------------------------	-------------------	--

**Section 5. Posterolateral rotatory instabilities (PLRI)**


1+		LCL PLC	ERR 2—3+ ADD at 30° PD Most 30° PLD 1+ RPS ER at 30° and 90°	Contact: Medial Forces: Varus Extension
----	---	------------	---	---

TABLE 15.4 *Continued.***Section 5. Posterolateral rotatory instabilities (PLRI)**

Diagnosis	Diagram	Involved anat. structure	Physical findings	Mechanism and forces
2+		PCL PLC	PD increased 30° more than 90° Moderate ER at 30° and 90°	Contact: Medial Forces: Varus Extension
3+		LCL PLC PCL PMC	ERR 2—3+ VAR 0° PD in Neutral Severe Hyperextension Rotation at 30° and 90°	Contact: Medial Anterior Forces: Hyperextension Varus

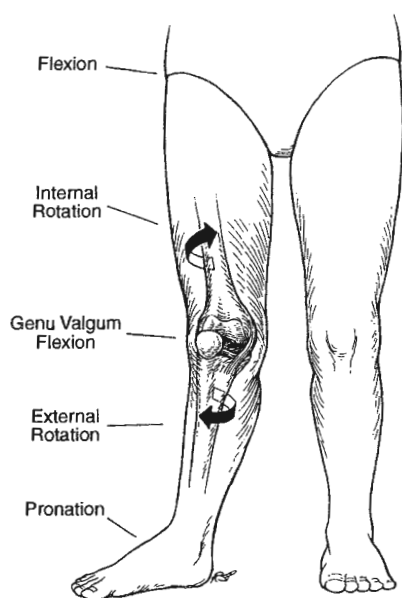
**Section 6. Combined ALRI and PLRI**

	ACL PLC PCL Lateral Capsule	PS RPS Lachman ERR PLD PD Neutral ER at 20° Fx	Contact: Anterior Forces: Valgus Extension or Hyperextension
--	--------------------------------------	---	---

**Section 7. Straight instabilities**

1+ Lateral (rare)		Isolated LCL	1+ ADD 30°	Contact: Medial Force: Varus
3+ Lateral		LCL PLC PCL ±ACL	2—3+ ADD 0° ERR PD in N AD in IR Hyperextension with ACL Injury	Contact: Medial Anteromedial Tibia Forces: Extension Varus
1+ Medial		SMCL	ABDUCTION at 30°	Contact: Lateral Forces: Valgus
Posteromedial Instability (PMI) (rare)		SMCL PMC PCL	ABDUCTION 0° PD IR+ Neutral AD in ER 2+ Valgus at 30° and 0°	Contact: Anterior Forces: Valgus Extension

(Table adapted by ML Ireland from ref. 175.)



**FIG. 15.43.** By videotape analysis this diagram shows the position of no return for the anterior cruciate ligament (ACL). The lower extremity position is one of body forward flexion, hip adduction, internal rotation, 20–30 degrees knee flexion, external rotation of the tibia and forefoot pronation. The knee will buckle, the patient is usually falling forward and toward the opposite side in a rapid distal deceleration mechanism.

oblique ligament, and lateral collateral ligament; this pattern of injury produces severe posterolateral rotatory instability, posterior drawer, and varus instability (see Table 15.4). Combined instabilities, particularly involving a complete tear of the PCL and capsular injury necessitate early surgical intervention, including ACL/PCL reconstructions and capsular repair.

Repeated exams for posterolateral rotatory instability should be meticulously performed (100) (see Table 15.4, Section 5). If the posterolateral corner and PCL are torn, acute repair of the posterolateral complex and PCL reconstruction or repair is indicated (see Table 15.4, Section 5, 2+,3+). Combined anterolateral rotatory instability and posterolateral rotatory instability also occurs (see Table 15.4, Section 6).

Straight instabilities are less common but do occur. With a medial blow severe straight lateral instability involves the lateral structures, ACL, and PCL (Table 15.4, Section 7). One must assess the peroneal nerve function. The posteromedial corner can rarely be injured in an isolated way. Because of the axis of the femur and the anatomy present, there is no true posteromedial rotatory instability (99). A consistent communication language regarding knee injuries by degrees of instability for treatment and follow-up purposes is necessary.

### Ligament Rating Scales/Outcomes

Numerous knee ligament rating scales have been developed by many authors. These have been frequently revised, indicating the lack of overall acceptance of any single rating instrument (4,84,92,116,132,138,153,154,180,182,184,186,199,226,241,250).

Outcome studies to assess knee ligament injuries treated operatively and nonoperatively are done by both subjective and objective measurements and most include a detailed patient questionnaire (unpublished data, N. Mohtadi University of Calgary, Alberta, Canada). Objectively, it is very important to have a standard classification so multicenter studies can be done. Comparisons of these knee-rating scales have been done (7,8,153,154,180,182,225,241). Prospective outcome studies on the ACL-injured patient have been published (53). This study does not support patients with ACL reconstruction having improved activity level and less arthritis. In this study, patients who underwent ACL reconstruction did not increase their activity level and developed arthritis.

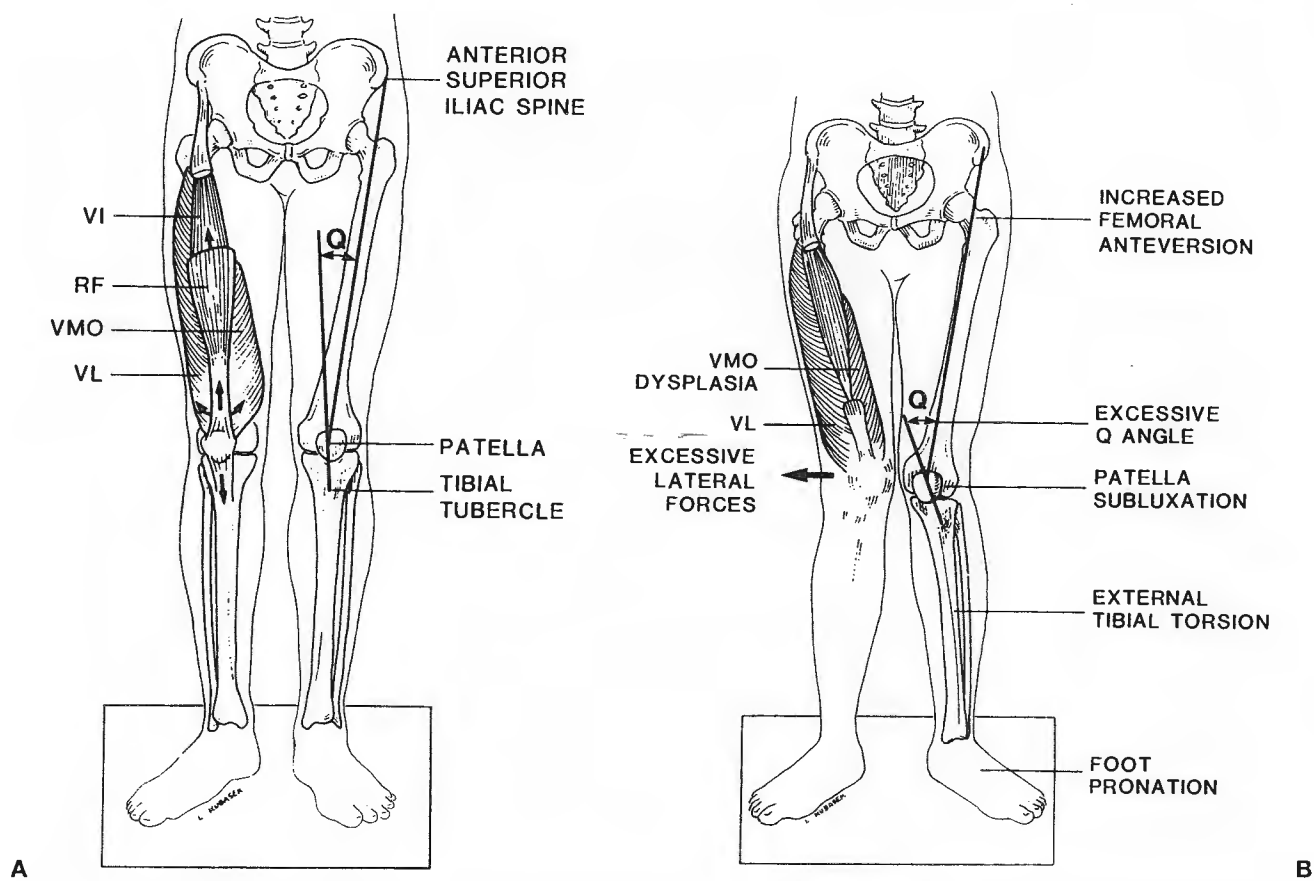
### PHYSICAL EXAMINATION

#### Abnormal Signs

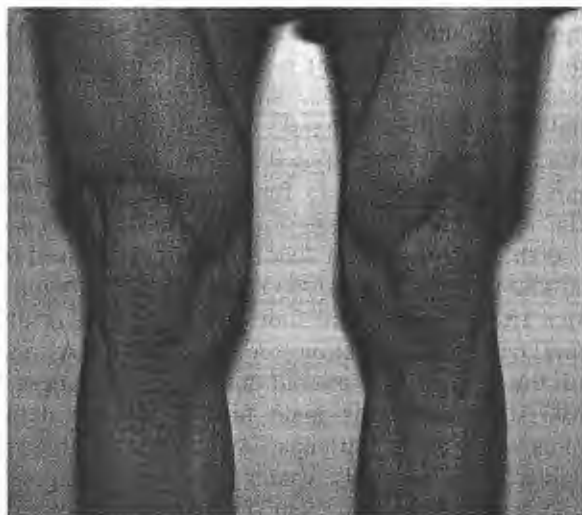A good physical exam should correlate the injured structures to the resultant instability patterns. The most painful test should be performed last. If ligaments are injured distraction forces cause pain. Compression causes pain if there is meniscal or articular surface injury.

#### Alignment

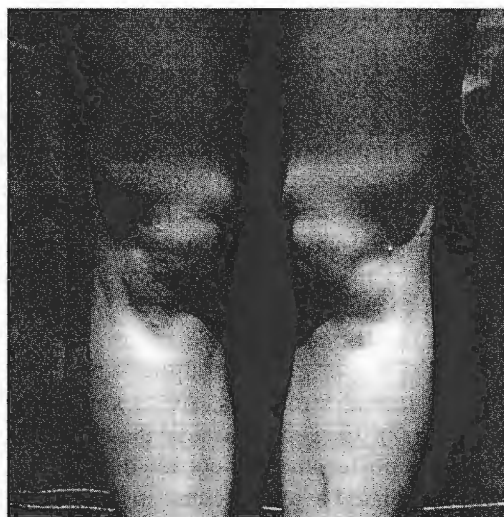The line drawings compare normal (Fig. 15.44A) and “miserable malalignment” (see Fig. 15.44B) (117). Normal patella alignment is a Q angle measured from the anterior superior iliac spine to the center of the patella to the tibial tubercle of less than 15 degrees. Normal muscular activity with a well-developed vastus medialis obliquus creates forces to medialize the patella, resulting in central tracking (see Fig. 15.44A). Miserable malalignment syndrome with increased femoral anteversion, excessive Q angle, genu valgum, external tibial torsion, and foot pronation may result in lateral patellar subluxation (see Fig. 15.44B). Also seen with these patients is overall quadriceps weakness and VMO dysplasia. This male football athlete demonstrates excellent quadriceps development with hypertrophic vastus medialis, vastus lateralis, 10 degrees Q angle and straight alignment (Fig. 15.45). Another example is a cheerleader with rotational malalignment with relatively straight varus/valgus alignment but sig-



**FIG. 15.44. A:** Normal alignment with normal Q angle measured from anterosuperior iliac spine central portion of the patella, patella to tibial tubercle of less than 15 degrees, normal musculature of developed vastus medialis obliquus, create forces, which centralize the patella, resulting in normal patellofemoral tracking. **B:** Miserable malalignment syndrome consists of increased femoral anteversion, excessive Q angle, external tibial torsion, and foot pronation. All of these factors cause lateral patellar subluxation. This miserable malalignment syndrome is frequently seen in females (43B). (Reprinted with permission from ref. 69.)



**FIG. 15.45.** Excellent normal alignment with legs essentially straight. Excellent quadriceps development including vastus medialis obliquus in male football athlete.



**FIG. 15.46.** Excessive femoral anteversion with patella pointed toward each other, hyperextension and internal rotation of the tibias. This cheerleader had anterior knee pain due to patellar tilt, rotation problems. She does have excellent vastus medialis obliquus development; however, her femoral anteversion is significantly causing abnormal patellofemoral biomechanics.

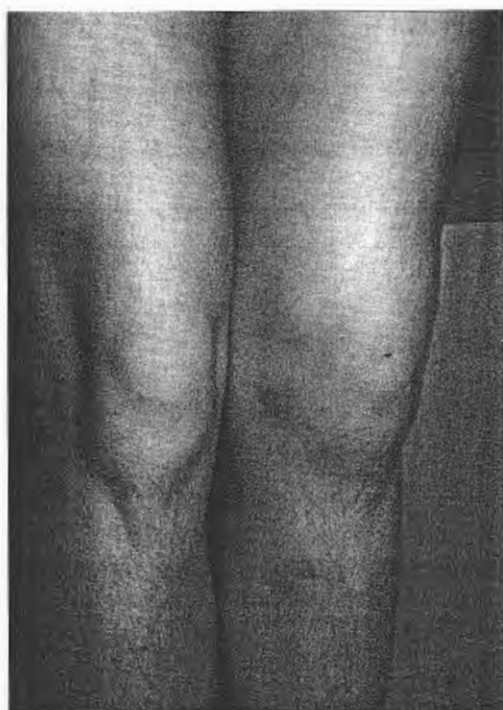

nificant femoral anteversion with internally rotated femur resulting in a patellar tilt and anterior knee pain (Fig. 15.46). The patellae pointing toward one another have been coined "squinting" or "grasshopper" eye patellae (Fig. 15.46). Note the excellent VMO development and overall quadriceps health in this female. This runner has had chronic problems with her left knee because of recurrent lateral patellar subluxation (Fig. 15.47). The normal right knee exhibits classic miserable malalignment signs of VMO dysplasia, external tibial torsion, genu valgum (see Fig. 15.47).

### Differential Diagnosis

Anterior knee pain has been termed the "low back pain" of sports medicine (4). Differential diagnosis can be classified into three categories—mechanical, inflammatory, and other (Table 15.5). To help accurately monitor these problems, pain diagrams are helpful (203). In the adolescent athlete, hip problems such as Legg-Calvé-Perthes disease or slipped capital femoral epiphysis may cause pain referred to the knee. This football athlete noticed a different appearance of his left thigh but did not remember a specific injury. Note the asymmetry of the vastus lateralis (Fig. 15.48). Femoral nerve palsy was confirmed by EMG and spontaneous resolution occurred after six months.

If the origin of the pain is the patella, is it the soft



**FIG. 15.47.** Vastus medialis obliquus (VMO) dysplasia, left recurrent patellar subluxation with effusion. Absent vastus medialis obliquus (VMO).

tissue, articular surface, or subchondral bone? Can the pain be localized by clinical exam? Physical exam signs include pain on direct palpation, positive apprehension test, and a J sign with a jump as the knee is extended and the patella jumps laterally. One must not forget the importance of quadriceps flexibility as well as hamstring flexibility. Tight hamstrings tend to exacerbate anterior knee pain by accentuating the compressive joint reaction forces.

The correct diagnosis must be determined in the athlete who complains of pain in the anterior aspect of the knee (75,76). The classification of PF disorders has been well described (72,170). An algorithm for anterior knee pain is being developed by the American Academy of Orthopaedic Surgeons (AAOS) based on physical examination and plain radiographs (4).

### Radiographic Assessment

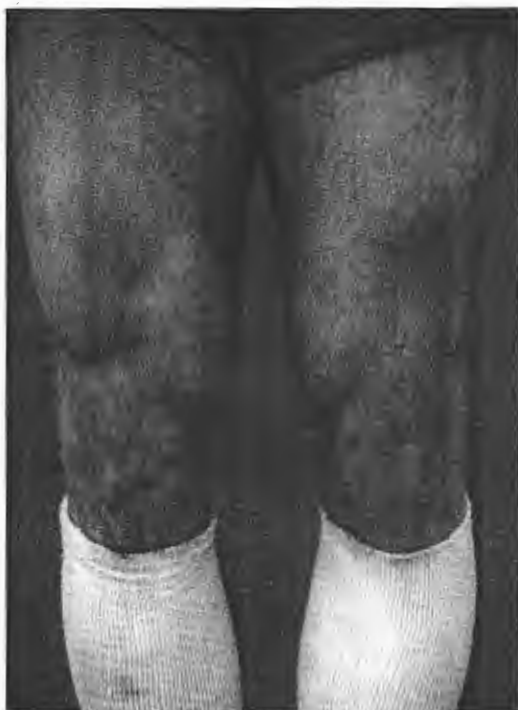Standard radiographic studies of the knee should always include an AP, lateral, and patellar sunrise view. The sunrise view provides a tangential view of the patella with its relationship to the femoral groove, and may show radiopaque loose bodies laterally or medial patella avulsion fractures. Views should be routinely done in a similar manner, bilateral, and consistent degree of flexion. Greater flexion may not show the subluxation. Cine CT and Cine MRI have been advocated to elucidate tracking in an active fashion. To date, these studies are quite expensive and may not provide additional information beyond standard radiography and a good clinical exam.

Many measurements can be made of different angles, tilts, or ratios for assessment of patellar height to tendon height (2,4,22,33,58,65,149,155,164,225). The plain radiographic measurements of angles for instability and the potential problematic patella are reported in detail (2,33,36,36a,44,57a,74,113,142,169). Testing with CT scan (158) MR (164) and bone scan (60) has been outlined. The patella at risk for having excessive lateral pressure syndrome is the one with a relatively flat trochlear groove, long lateral patellar facet and acutely angled medial patellar facet. Radiographs of sunrise view show this painfully subluxed patella (Fig. 15.49). The length ratio of the patella to the patellar tendon height is also important to note on the lateral view. A ratio greater than 1:1 means the patella is low-riding or patella infera (Fig. 15.50A). A ratio less than 1:1 means the patella is high-riding or patella alta (see Fig. 15.50B). The infera or low-riding position increases risk of articular cartilage damage from excessive contact pressure. The patient with patella alta is at risk for patellar instability and tracking problems.




TABLE 15.5. *Differential diagnosis: anterior knee pain*

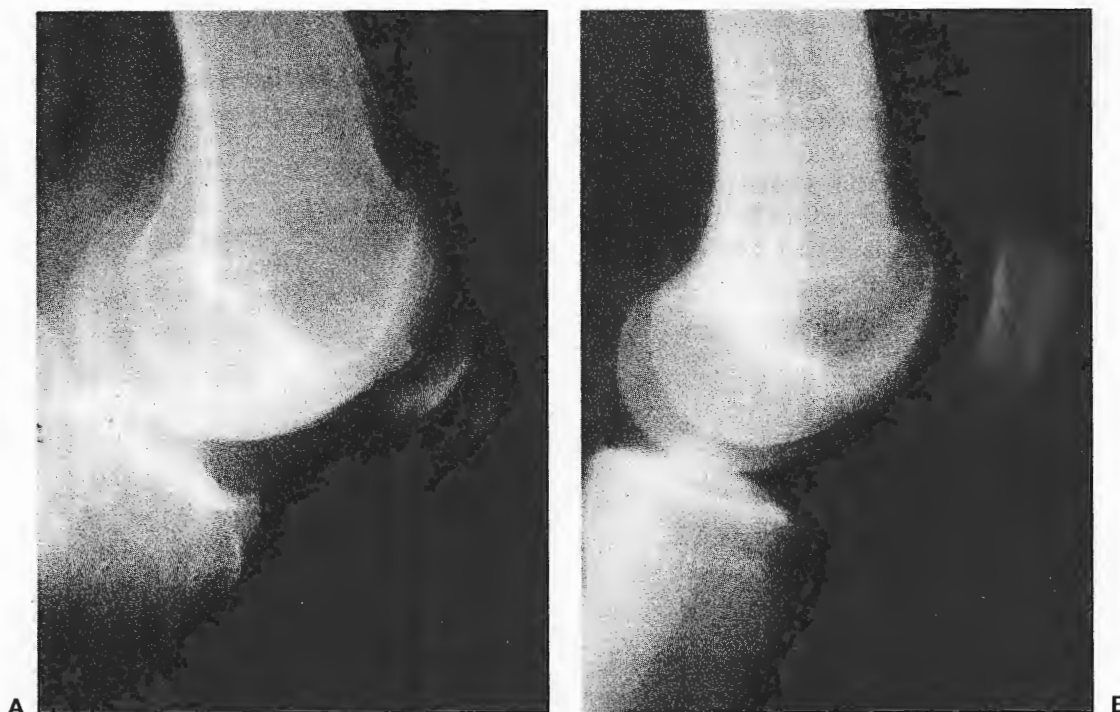
Mechanical	Inflammatory	Other
Repetitive Microtraumatic <ul style="list-style-type: none"> <li>• Patella               <ul style="list-style-type: none"> <li>Stability</li> <li>Subluxation</li> <li>Dislocation</li> <li>Tilt</li> <li>Rotation</li> <li>Malalignment</li> <li>Fracture</li> <li>Stress</li> <li>Bipartite</li> <li>Fibrous Union</li> <li>Acute Fracture</li> </ul> </li> <li>• Pathologic Medial Plica</li> <li>• Patellofemoral Stress Syndrome</li> <li>• Osteochondral Fracture               <ul style="list-style-type: none"> <li>Trochlear Groove</li> <li>Patella</li> </ul> </li> <li>• Loose Bodies               <ul style="list-style-type: none"> <li>Cartilaginous</li> <li>Osteochondral</li> </ul> </li> <li>• Osteochondritis Dissecans               <ul style="list-style-type: none"> <li>Patella</li> <li>Trochlear Groove</li> </ul> </li> <li>• Skeletally Immature               <ul style="list-style-type: none"> <li>Osgood-Schlatter's Disease</li> <li>Sinding-Larsen-Johansson Syndrome</li> </ul> </li> </ul> Acute Macrotraumatic Injury <ul style="list-style-type: none"> <li>• Extensor Mechanism Disruption               <ul style="list-style-type: none"> <li>Quadriceps Rupture</li> <li>Patellar Tendon Rupture</li> <li>Inferior Avulsion Fracture</li> <li>Interstitial</li> <li>Skeletally Immature</li> <li>Tibial Tubercle Fracture</li> </ul> </li> <li>• Patellar Fracture               <ul style="list-style-type: none"> <li>Transverse</li> <li>Displaced/Nondisplaced</li> <li>Comminuted</li> <li>Status Post ACL Reconstruction with Central Third Patellar Tendon Bone</li> </ul> </li> </ul>	Bursitis <ul style="list-style-type: none"> <li>• Prepatellar</li> <li>• Retropatellar               <ul style="list-style-type: none"> <li>Semimembranosus</li> <li>Pes Anserinus</li> </ul> </li> </ul> Tendinitis <ul style="list-style-type: none"> <li>• Quadriceps Patella</li> <li>• Pes Anserinus</li> <li>• Semimembranosus</li> </ul> Pigmented Villonodular Synovitis           Neuromata/Retinacular Pain           Arthritis <ul style="list-style-type: none"> <li>• Osteo</li> <li>• Rheumatoid</li> <li>• Psoriatic</li> <li>• Others</li> </ul> Syndromes <ul style="list-style-type: none"> <li>• Reiter's</li> </ul>	Referred Pain <ul style="list-style-type: none"> <li>• Lumbar Disk Herniation</li> <li>• Others</li> </ul> Reflex Sympathetic Dystrophy           Tumors <ul style="list-style-type: none"> <li>• Benign</li> <li>• Malignant</li> </ul>



**FIG. 15.48.** Athlete with vastus lateralis atrophy from femoral nerve stretch or contusion.



**FIG. 15.49.** The patella at risk for being painful and for chondromalacic change and excessive lateral pressure syndrome is the one with a relatively flat trochlear groove, long lateral patellar facet and acutely angled medial patellar facet. Radiographs of sunrise view show this problem patella.



**FIG. 15.50. A, B:** These two lateral knee radiographs show very different orientations of the patella. In **A**, the patella is low-riding patella or patella infera. **B** shows a high-riding patella or patella alta, associated with hypermobility and instability. The patella infera is associated with patellar compression and pressure problems.

## OVERUSE CONDITIONS

These entities to be discussed include patellar tendinitis, disruption of the extensor mechanism, quadriceps and patellar tendon ruptures, tibial tubercle avulsion, patellar fractures, bipartite patella, patellar instability, patellar subluxation, and patellar dislocation. A variety of overuse conditions from repetitive microtrauma can cause localized anterior knee pain.

### Patellar Tendinitis

The patellar tendon transmits the combined forces of the ground reaction force proximally and the quadriceps muscle force distally. Repetitive loads can lead to inflammation and irritation at the proximal insertion of the tendon onto the patella (jumper's knee) or inflammation or degeneration of the tendon in its mid-substance. An association between patellar height and patellar tendinitis has been debated (65,264). Magnetic resonance imaging (MRI), however, can show focal inflammation and degeneration and provide a more complete delineation of the extent of the pathologic process.

Treatment is generally conservative but may be prolonged because of the resistant nature of the condition. The extent of treatment can be based on the level and degree of the patient's complaints (25). Does the athlete have pain during and/or following performance of his or her sport? Does it affect his or her ability to perform at a satisfactory level? The earliest phase can respond to eccentric quadriceps rehabilitation, hamstring stretching, ice massage, deep friction massage, antiinflammatory medications and a knee support with patellar tendon strapping or taping. If complaints have existed for an extended period of time or the athlete is having pain during the performance of his or her sport, reduced activity, extended rehabilitation, and additional therapeutic modalities are in order. Altering the athlete's activity to decrease the axial loading while maintaining cardiovascular fitness can be very beneficial during the period of therapeutic intervention (50). Others have emphasized the importance of rehabilitating the entire lower extremity, including hip muscles and the ankle dorsiflexors and invertors (24,238).

A steroid injection is not performed in most cases because of the risk of partial or complete rupture of the patellar tendon. In athletes not responding to a lengthy course of conservative treatment, surgical debridement of the necrotic site of the tendon with drilling of the patella to increase vascularity to the area can provide relief. Other authors would suggest a diagnostic arthroscopy prior to proceeding with patellar tendon debridement (249).

In the skeletally immature athlete, the transmitted loads can lead to a traction apophysitis of the distal pole of the patella (Sinding-Larsen-Johannson syndrome) or the tibial tubercle (Osgood-Schlatter's syndrome) (194).

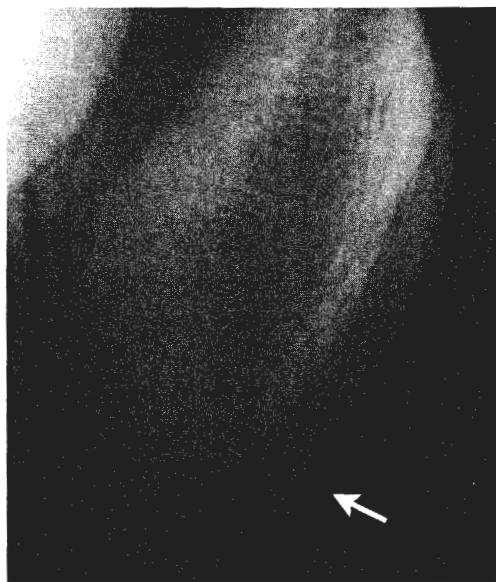
This gymnast had point tenderness at the inferior pole of the patella. Lateral radiograph shows elongation of the periosteal sleeve and sclerosis indicating Sinding-Larsen-Johannson syndrome (Fig. 15.51). Radiographically, in Osgood-Schlatter's disease there is fragmentation or separation of the tibial tubercle apophysis. Clinically, OSD is seen with a prominence of the bursa and tibial tubercle (Fig. 15.52). These conditions represent a growth imbalance—not a true disease. Rapid femoral growth results in hamstring tightness, relative quadriceps weakness and increasing distraction pressures on the extensor mechanism. Most of these patients are male and may have had Sever's disease (calcaneal apophysitis). Hamstring tightness is measured by the degree of knee flexion with the hip flexed to 90 degrees. Treatment begins with avoiding the repetitive eccentric quadriceps loading maneuvers that cause pain. Treatment may include patellar tendon taping, knee sleeves, closed chain strengthening and hamstring stretching, and quadriceps strengthening (194).

### Disruption of the Extensor Mechanism

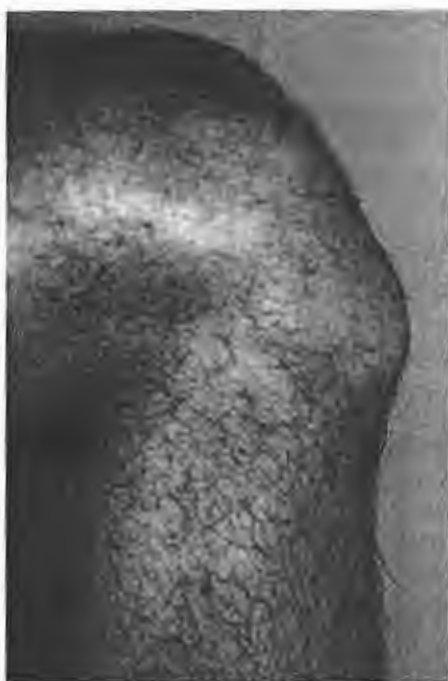Displaced patella fracture, quadriceps tendon rupture, patellar tendon rupture, and tibial tubercle avulsion each interrupt the continuity of the extensor mechanism. The diagnosis is made by a palpable defect in the tendon or deformity from the fracture and inability to actively extend the knee.

### Quadriceps and Patellar Tendon Ruptures

Extensor mechanism tendon disruption can occur at the quadriceps or patellar tendon level. Most authors believe



**FIG. 15.51.** This lateral radiograph shows elongation and periosteal sleeve and sclerosis indicating Sinding-Larsen-Johannson syndrome (arrow).



**FIG. 15.52.** Clinically, Osgood-Schlatter's disease (OSD) is shown with prominence of the bursa and tibial tubercle.

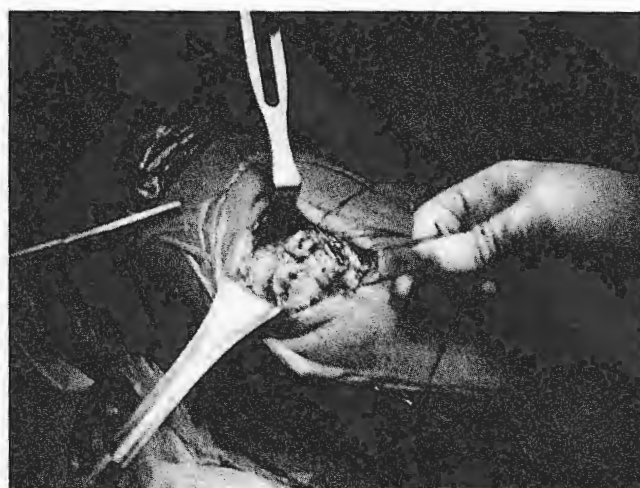
that normal tendons rarely rupture (50,130,167,238). There may be a previous history of chronic inflammatory complaints, systemic disease such as autoimmune disorders, or previous steroid injection into the tendon.

All displaced tendon ruptures should be urgently repaired. This individual with overdeveloped quadriceps slipped on a wet spot while walking and fell backwards (Fig. 15.53A). He felt a rip in his quadriceps and was

unable to extend his knee. He ruptured his quadriceps tendon from a violent eccentric quadriceps contraction in an off-balance position while flexing the knee. His surgical findings were an avulsion of the quadriceps mechanism from the patella extending into the VMO and lateral retinaculum (see Fig. 15.53B).

#### *Rehabilitation of Quadriceps Tendon and Patella Tendon Ruptures*

The two tenets of successful rehabilitation of quadriceps and patella tendon repairs are to minimize the effects of scarring and to maximize flexion. The period of immobilization and early range of motion is dictated by the surgeon. Ice, electrical stimulation, compression stockinette, and elevation are employed to reduce swelling. Transverse friction massage is initiated approximately 5 to 7 days postoperatively. The degree of pressure is dependent on the status of the incision and repair. Patella mobilizations are performed in the medial, lateral, inferior, and superior directions. Typically, this is done prior to stretching into flexion to facilitate the inferior patella glide. Stretching the quadriceps while holding the hip in an extended position assists in maximizing the quadriceps stretch and minimizing anterior knee discomfort (Fig. 15.54). Proprioceptive neuromuscular facilitation (PNF) techniques such as hold/relax and contract/relax are usually very beneficial therapeutic tools in gaining flexion. However, initially the patient must be instructed to provide a very minimal contraction so as not to stress the repair. Hold/relax is an isometric technique in all planes of motion applied to a restricted muscle and is most beneficial when there is a fair amount of pain present. Contract/relax is an isometric technique of the flexion/exten-



**FIG. 15.53. A,B.** This individual with overdeveloped quadriceps slipped on a wet spot in front of his washer/dryer and fell backwards. Repair is done by reattaching the quadriceps tendon back down to the patella, which can be done with suture anchors or through drill holes in the patella itself.



**FIG. 15.54.** Quadriceps stretch. Stretching the quadriceps while holding the hip in an extended position assists in maximizing the quadriceps stretch and minimizing anterior knee discomfort.

sion and abduction/adduction components but active in the rotation of the agonistic component. This technique is not as appropriate with pain. These techniques should only be employed when the clinician trusts that the patient understands the concepts and purpose for using them. Strengthening can begin in one week with three-way straight leg raises (abduction, adduction, extension). By week three, submaximal quadriceps setting, straight leg raises (flex) with immobilizer on, and terminal knee extension (both open and closed chain, with the amount of weight bearing dependent on the status of the repair) can be added (Figs. 15.55 and 15.56). The bicycle is an excellent exercise to promote quadriceps contraction and knee flexion. Generally, it takes approximately 95 degrees of knee flexion to perform a good revolution. As the strength of the repair improves, typical strengthening exercises are added, such as leg presses, hamstring curls, short arc

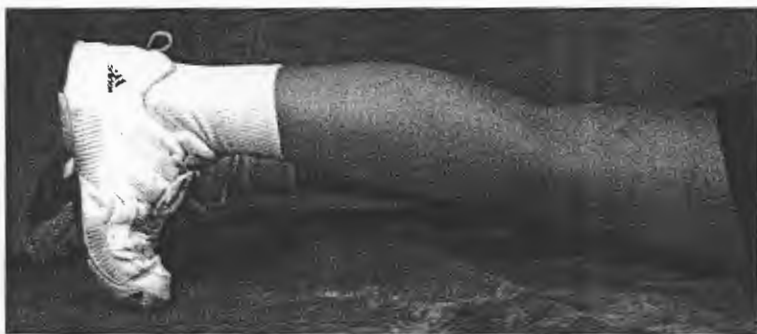
lunges, mini squats, step-ups/downs, and calf raises. Gait training exercises such as carioca, high knee, and line walking are also initiated once the patient is full weight-bearing (Fig. 15.57 to 15.59). It is important to emphasize eccentric control of the hip musculature, quadriceps, and gastroc, as deficits in these areas are often contributing factors in the initial injury.

### *Tibial Tubercle Avulsion*


In the skeletally immature athlete, a violent eccentric quadriceps contraction during jumping is the typical mechanism resulting in tibial tubercle avulsion (204). There is no conclusive association between Osgood-Schlatter's disease (OSD) and tibial tubercle avulsion. One report stated 40% of athletes may have had preexistent OSD (257).

Classification is based on displacement and orientation of the avulsed fragment of the tibial tubercle (194). If displacement is minimal or reduction can be obtained with the knee in extension, the knee is casted in extension for 4 to 6 weeks. If the fragment is displaced or there is any physal or articular surface offset, open reduction and internal fixation is indicated (194,204,257).

This 15-year-old came down from a jump playing basketball and felt severe pain and was unable to extend his knee. Clinical exam shows significant ecchymosis and swelling (Fig. 15.60A). Lateral radiograph shows the displaced fracture of the tibial tuberosity with extension intraarticularly posterior to the ACL attachment (see Fig. 15.60B). A CT scan was helpful to demonstrate the orientation of the fragment and to document only two pieces (see Fig. 15.60C). For this Ogden type 3A, arthroscopy and then open reduction internal fixation was performed. The lateral view shows anatomic reduction fixed with three screws (see Fig. 15.60D). He had a good result with eventual return to all activities, including basketball, by one year post-surgery. Rehabilitation of tibial tubercle avulsions mimics that of patella fractures. Typically, range of motion can be restored more quickly and exercises can progress more rapidly, particularly if internal fixation is used.



**FIG. 15.55.** Terminal knee extension. The foot is maintained in dorsiflexion to provide approximately 20 degrees of terminal knee extension range.



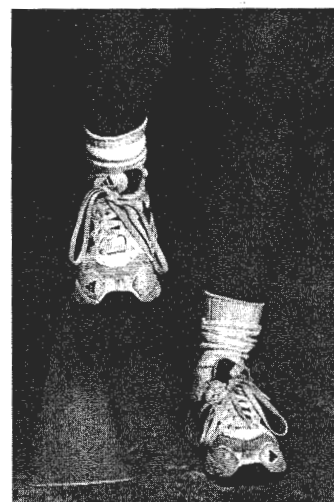
**FIG. 15.56.** Closed kinetic chain terminal knee extension. Weight-bearing stance, Theraband, or Theratubing providing resistance to terminal knee extension.



**FIG. 15.57.** Carioca or cross-over walks assist in improving balance and neuromuscular control.

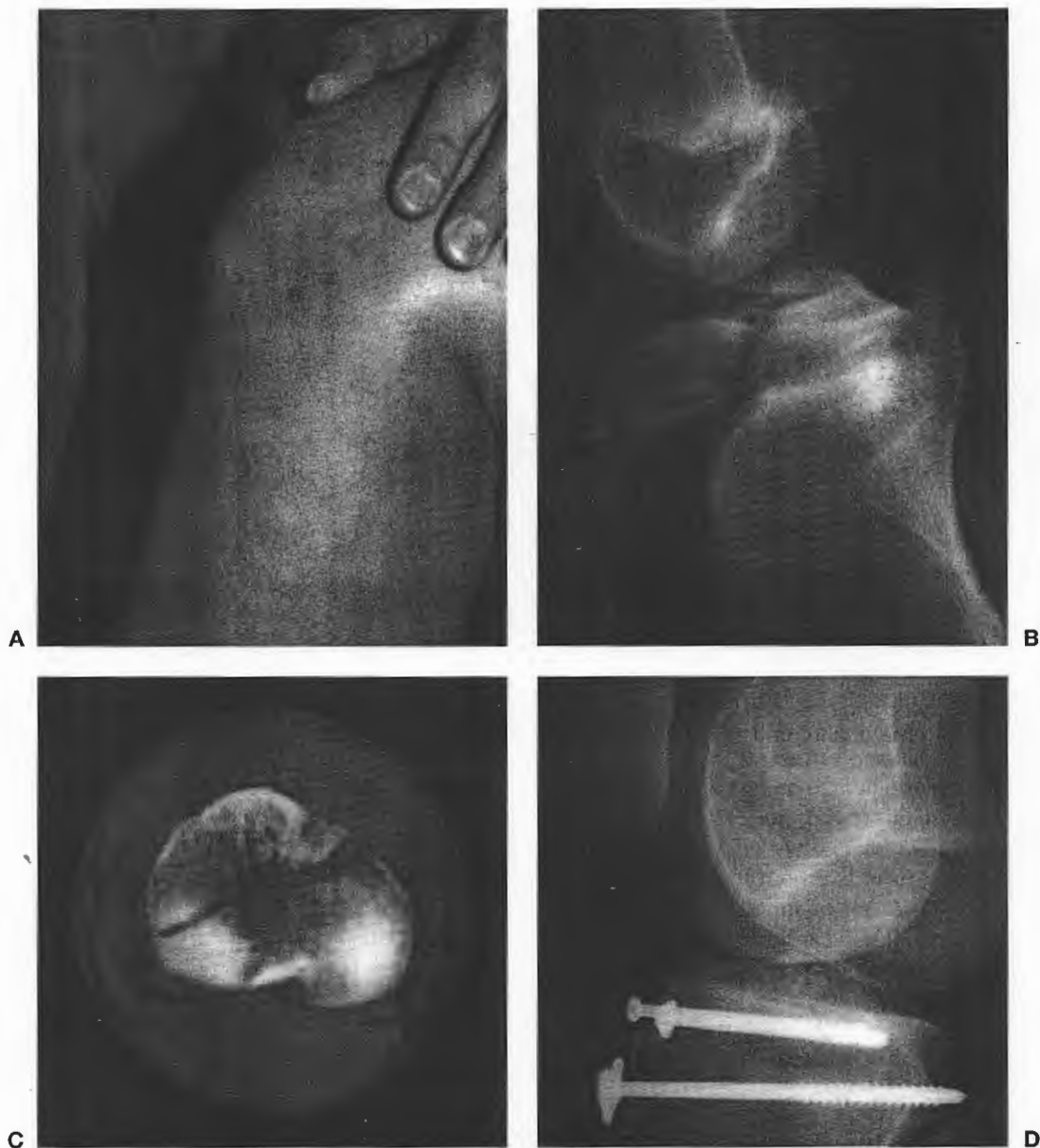


**FIG. 15.58.** Forward high-step walking. The patient ambulates over cones or other objects to accentuate normal knee bend.



**FIG. 15.59.** Lateral high-step walks. Accentuates normal knee bend during gait and contributes lateral function of push-off and stance legs.





**FIG. 15.60.** **A:** This 15-year-old came down from a jump playing basketball and felt severe pain and was unable to extend his knee. Clinical exam shows significant ecchymosis consistent with a probable fracture and inability to extend his knee. **B:** Radiographs show the displaced fracture of the tibial tuberosity with involvement intraarticularly posterior to the anterior cruciate ligament (ACL) attachment. This is best seen on lateral view. **C:** A computed tomography (CT) scan was helpful to demonstrate the orientation of the fragment and the fact that there was a nondisplaced posterior portion. **D:** For this Ogden type III-A, arthroscopy and then open reduction, internal fixation was performed.



### Patella Fractures

In athletes, fractures of the patella commonly occur from direct contact. The fracture pattern is generally stellate and rarely displaced (200). If nondisplaced, the fracture can be treated in knee extension and immobilized for 4 weeks with early weight bearing.

Transverse fractures of the patella occur more frequently in an older population from a direct blow or a fall onto the knee, hyperextension or violent quadriceps contraction. If there is displacement of the fragment with articular surface, angulation or step-off, then open reduction (151,218) with cerclage wiring is performed. If there is significant comminution, a partial or complete patellectomy is done. Rehabilitation begins with patella mobilizations and range of motion exercises. Strengthening exercises are advanced based on healing of the patella fracture. Open chain strengthening exercises are avoided because of the high patellofemoral forces they cause. Return to activity depends on the nature of the fracture, healing and sport.

Complication of a patellar fracture following bone-patellar tendon-bone (BPTB) can occur. There is temporary weakness and osteopenia of the patella following harvesting of the graft. A fracture at the patella harvest site is often in the orientation of a Mercedes emblem. This potential complication is of concern, particularly in patients who have early return to their sport prior to adequate bone healing. Taking a smaller patellar fragment bone and bone-grafting the patellar defect with cancellous bone reduces the risk of fracture.

### Bipartite Patella

A bipartite patella has one or more unfused ossification centers. Bipartite patellas exist in 2% to 3% of the population. The finding will be unilateral in 57% and bilateral in 43% (85). Seventy-five percent of the fragments are in the superolateral quadrant, 10% in a vertical lateral position and 5% are at the inferior pole (121,219). Most bipartite patellae are incidental findings and are asymptomatic. Symptomatic patients typically are in a stop/cut repetitive load sport such as soccer. A stress fracture through the bipartite fibrous union can occur. This classically presents as pain directly over the bipartite area of the patella. Radiographs may show displacement but more commonly show only the bipartite patella. A bone scan can be done if there is confusion regarding the diagnosis. However, if there is pain directly over the patella and a bipartite is present, surgical excision of this is usually necessary. Displaced fractures of bipartite patella have been reported (62,118). This football place kicker had pain over his plant knee. He underwent arthroscopy and open excision of the fragment with reattachment of the quadriceps anterior posterior knee mechanism. Radiograph with the ex-

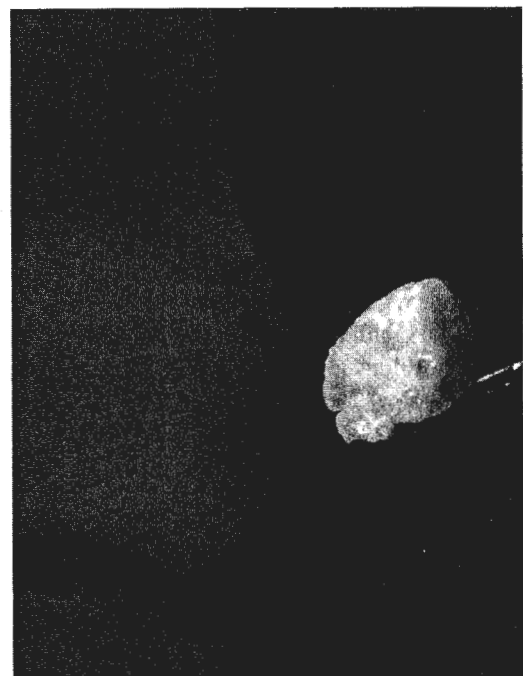
cised fragment is shown (Fig. 15.61). Postoperatively, after his rehabilitation program, he returned to kicking activities at three months.

### Patellar Instability

Patellofemoral stability is a result of a complex series of interactions involving joint congruity, alignment, and static and dynamic patellar stabilizers (74,202). Bony factors that predispose to patellar instability include; a small, short lateral femoral condyle, a shallow femoral groove, a flat patella, femoral internal rotation or anteversion of the hip, and an increased valgus or Q angle. The most common direction of patellar instability is lateral. The previous factors can magnify the forces or reduce the resistance to lateral displacement of the patella. Medial instability is more commonly iatrogenically because of surgical overcorrection of lateral subluxation (103,209).

Surgical intervention for recurrent patella dislocation and instability is open realignment, which can include distal tibial tubercle transfer, proximal reefing, and lateral release (77,102,231). In the skeletally immature unstable patella, only soft tissue procedures are done.

Additional factors that can contribute include generalized ligamentous laxity, previous trauma, tight lateral retinaculum, and motor imbalance or weakness. Generalized ligamentous laxity implies that all static restraining forces about the knee including the medial retinaculum are loose



**FIG. 15.61.** This football place kicker had pain over his plant knee. He underwent arthroscopy and open excision of the fragment with reattachment of the quadriceps knee mechanism. Radiograph with excised fragment is shown.

and will not provide adequate resistance to patellar subluxation. Previous trauma with patellar dislocation is associated with tearing of the medial soft tissue structures including the patellofemoral and patellotibial ligaments, retinaculum and insertion of the vastus medialis obliquus (VMO). If these heal in a lengthened position, they will provide less resistance to lateral displacement. A tight or contracted lateral retinaculum can lead to patellar tilt or lateral subluxation. Finally, since the VMO is the only dynamic structure preventing lateral displacement, weakness or imbalance will lead to lateral instability.

Female athletes are at particular risk of patellofemoral problems including instabilities. The causes are multifactorial and include slight increased ligamentous laxity compared to males, a naturally increased valgus angle at the knee, dysplasia and VMO weakness, and muscular imbalance of the entire lower extremity. All female athletes should be aware of these risks as well as the techniques and exercises that can minimize their risk by maximizing the strength and neuromuscular control of their lower extremity, particularly the VMO.

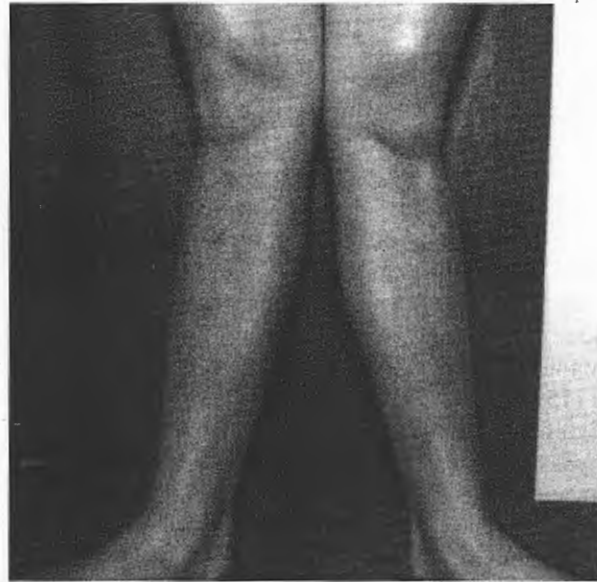### Patellar Subluxation

The athlete with patellar subluxation will complain of anterior knee pain and may note a feeling of "giving way." In general, no true patellar dislocation has occurred. In moderate to severe cases, it may be apparent by inspection in the standing or seated position that the patellae point laterally. As the knee is passed through a range of motion against resistance, the patella may quickly shift from a medial position in flexion to laterally subluxed around 30 degrees of flexion. This is called "the J-sign." The examiner must consider the contributing causes including miserable malalignment syndrome, valgus alignment, genu valgum, femoral anteversion, generalized ligamentous laxity, VMO dysplasia, external tibial torsion and pes planus and pronation (Fig. 15.62). Similar complaints may be seen in other knee conditions such as plica syndrome, loose body, or osteochondral defect.

Treatment of patellar subluxation ranges from exercises, taping, orthotics, and braces to operative releases and reconstructions. Most athletes respond to conservative, nonoperative treatment. Careful identification of contributing factors guide the choice of treatment. Children may improve their VMO strength, reduce their valgus alignment angle, and increase the size of the lateral femoral condyle, thereby deepening their femoral groove—literally outgrowing the problem.

### Patellar Dislocation

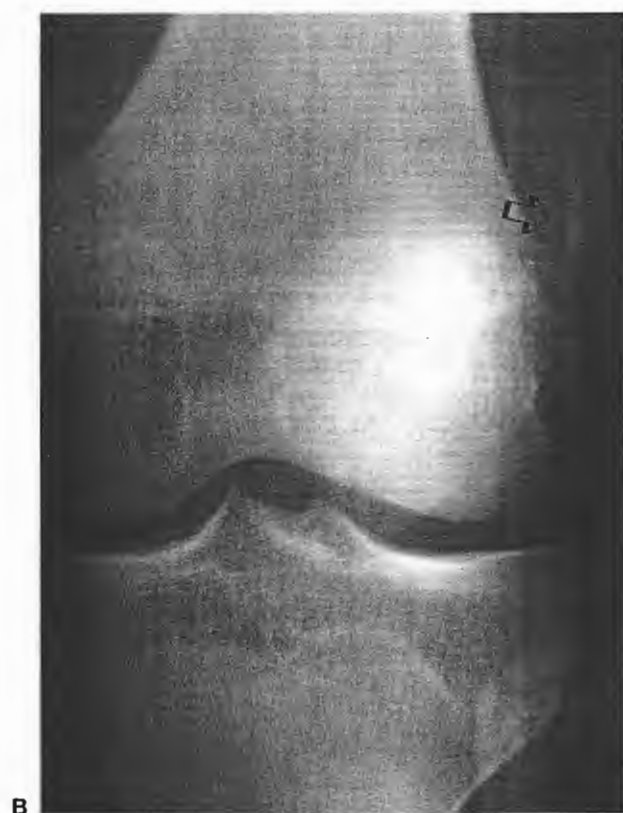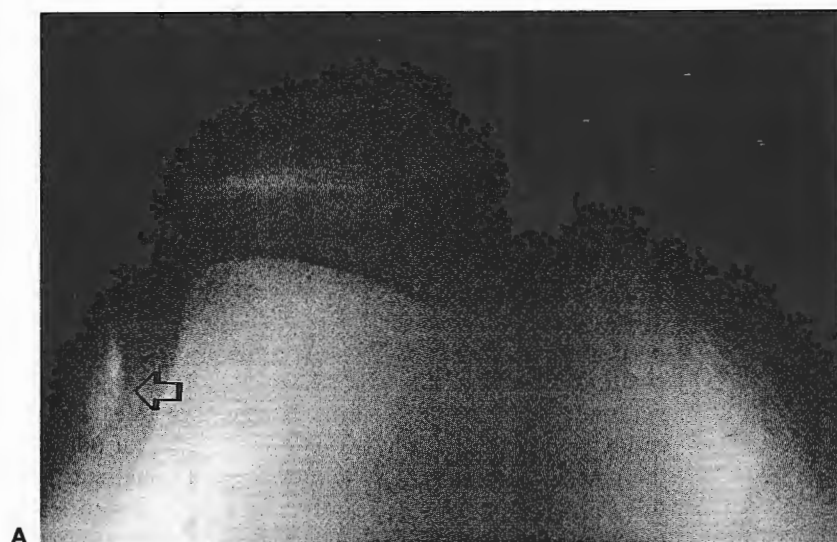Patellar dislocations may be preceded by a prodrome of patellar subluxation. More frequently, the dislocation occurs because of a single isolated event. The mechanism



**FIG. 15.62.** Miserable malalignment syndrome is shown in this female patient. Valgus alignment of genu valgum, femoral anteversion, generalized ligamentous laxity, vastus medialis obliquus (VMO) dysplasia, external tibial torsion and pes planus and pronation are components of miserable malalignment syndrome.

of dislocation is from a twisting/cutting knee motion while the knee is in a valgus and flexed position. It may be associated with a particularly violent contraction of the quadriceps. Less common is a direct blow to the medial patella. The patella usually spontaneously reduces as the knee extends. An acute, tense hemarthrosis is common. Localized tenderness is at the VMO and medial retinaculum of the patella. Pain on the lateral aspect of the lateral femoral condyle indicates a lateral femoral impaction lesion. Osteochondral fractures and loose bodies complicate approximately 5% to 30% of acute patellar dislocations and frequently require surgical removal if present (110).

The sunrise or merchant patellar view is best to see a loose fragment, seen laterally, usually originating from the medial aspect of the patella (110) (Fig. 15.63A). Views of the radiographs of patellar view shows the fragment lying in the lateral gutter (see Fig. 15.63B). This 17-year-old sustained a lateral patellar dislocation during a baseball game. The most common location of osteochondral loose body is the medial patellar facet shown by diagram and arthroscopy. The loose fragment was found in the notch, located anterior to the ACL. A lateral impaction lesion is also seen correlated by diagram and arthroscopic finding. Diagrammatically, the fragment usually comes off at the area labeled *IC* and there is a lateral impaction lesion where the patella abuts on the lateral non-weight-bearing area of the femoral condyle (2C) (169) (Fig. 15.64). Diagrammatically, the patellar dislocation dislodged the medial patellar facet and the loose



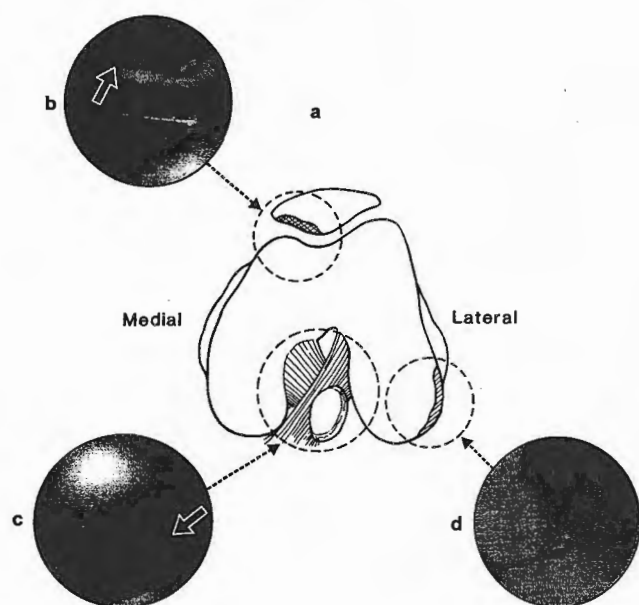
**FIG. 15.63. A:** Sunrise view showing location of the radiopaque loose body in the lateral compartment the source of the medial patella corresponds to the a and d, in Fig. 2 from ref. 110. **B:** Anteroposterior (AP) view with arrow showing radiopaque loose body. (Reprinted with permission from ref. 110.)

body was found lying just anterior to the ACL. The loose body was removed, and the patella and lateral femoral gutter were debrided. If the fragment has enough cancellous bone to successfully internally fix, this should be done.

Treatment in the case of an acute patella dislocation with no associated osteochondral fragments should be based on the presence or absence of predisposing factors for recurrent dislocation. Without predisposing factors, a conservative approach may be attempted with the knee

immobilized in extension with a lateral knee pad or taping to maintain reduction of the patella for 4 to 6 weeks. Institution of range of motion activities with the knee taped to medialize the patella can begin even earlier in compliant patients. The rehabilitation program addresses the trunk, hip, knee, and lower leg to assure that normal lower extremity kinetic chain function and balance is restored.

Some authors advocate surgical repair in most patients



**FIG. 15.64.** This 17-year-old male sustained lateral dislocated patella with osteochondral loose body. Correlation of arthroscopic findings with diagram puts the mechanism of injury with arthroscopic findings. The patellar fracture and origin of loose body is usually the medial patellar facet, diagrammatically (a), and arthroscopically (b) (arrow). The fragment can be knocked off during dislocation or relocation. When the patella is dislocated, a lateral impaction lesion occurs (d). The loose body is seen diagrammatically lying anterior to the anterior cruciate ligament and the articular cartilage with underlying cancellous bone is shown (c) (arrow). (Reprinted with permission from ref. 110.)

and all athletes with an acute patellar dislocation regardless of predisposing factors (27,28,51,244). One series noted that the preoperative examination yielded the correct diagnosis of an osteochondral fracture in only 17% of patients (193). If osteochondral loose bodies are present, surgery is indicated. If the osteochondral fracture is large enough it can be fixed. Usually the fragment is articular cartilage only and requires removal. Arthroscopic debridement of the donor base is done. Arthroscopy is an excellent adjunct in identifying all loose fragments. A primary repair of the torn medial retinaculum and VMO can be performed through a small medial parapatellar approach. Postoperatively, surgically repaired patients are treated similarly to the nonoperative approach to protect the repair.


#### Rehabilitation of Excessive Lateral Facet Pressure/ Patella Subluxations/Dislocations

Intrinsic rehabilitation of a patellofemoral problem is directed toward the identified causative factors. Control of the lower extremity starts with having a stable "core" or trunk. Once that has been established, muscles control-

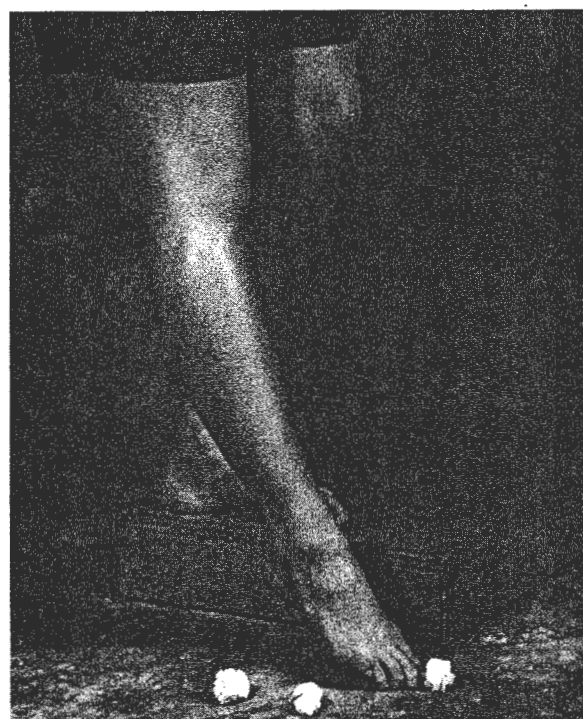
ling the lower extremity can effectively do their job. Weakness in the hip can lead to too much internal rotation of the lower extremity with resultant excessive lateral pressure, subluxation, or dislocation of the patella. The hip extensors, abductors, and external rotators need to be rehabilitated with adequate strengthening and neuromuscular reeducation (Figs. 15.65 to 15.70) (263). The iliotibial band and lateral retinaculum should be aggressively stretched to prevent a lateral pull (Fig. 15.71 and 15.72). Stretching tight hamstrings will decrease patellofemoral joint compression (Fig. 15.73). Both open and closed chain exercises are effective in developing strength and neuromuscular control. A weak or dystrophic VMO will result in a muscular imbalance favoring a lateral pull of the patella. Strengthening the quadriceps throughout the full range of motion (or at least through the functional range relative to the sport) while emphasizing an isometric adduction of the hip can often be more effective in rehabilitating the dystrophic VMO because of the dual innervation from the femoral and obturator nerves (Fig. 15.74). Electromyographic biofeedback has been helpful in training the athlete to fire the VMO appropriately (258). The foot and ankle need to be assessed from a structural and functional standpoint. Structurally, excessive rearfoot



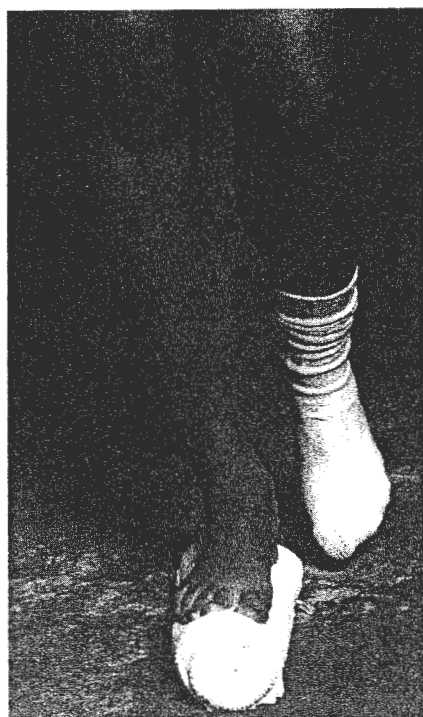**FIG. 15.65.** Unilateral ball squats. Leaning against a ball allows for easy rolling down a wall when performing unilateral ball squats. Emphasis is placed on depth of squat and in lower extremity control during the squat.



**FIG. 15.66.** Unilateral squat with contralateral hip abduction. The patient performs unilateral squat while abducting the contralateral hip into a wall to increase ipsilateral gluteus medius activity.



**FIG. 15.67.** Mini-squat with ball pick-up. The patient performs mini-squat at a variety of depths while performing ball pick-up with contralateral toes to provide challenge in balance and stability.




**FIG. 15.68.** Balance exercises. The patient performs a variety of activities while in unilateral stance on a towel roll to provide an unstable base.




**FIG. 15.69.** Unilateral stance ball toss. The patient performs ball-catching activities at a variety of speeds and positions while in unilateral stance to challenge the balance and neuromuscular function of the lower extremity.

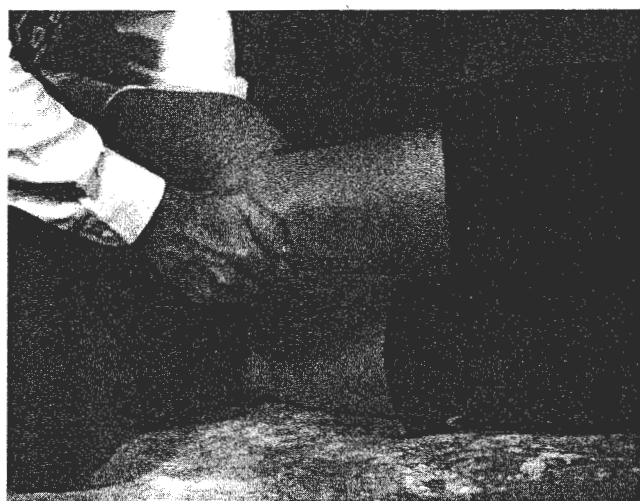



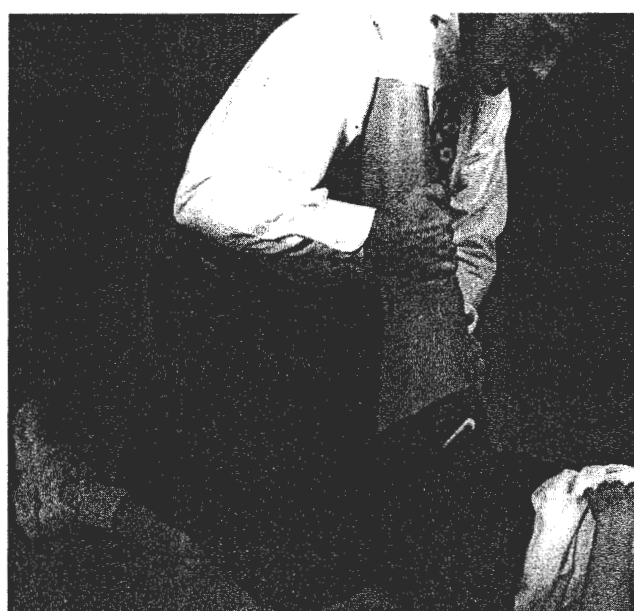
**FIG. 15.70.** Wobble board. Work on balance, not letting the rim of the board touch the floor. Can also work on full range of motion, riding the entire rim of the board around, touching the floor at all times.



**FIG. 15.71.** ITB stretch. Place involved limb behind stance leg while going through a side stretch to the opposite side.



**FIG. 15.72.** Medial glide. With patient in side-lying, involved side up, clinician maintains a fixed knee angle while performing medial glides of the patella. Knee angle should correspond to the angle at which the patient experiences pain. This mobilization should not be painful.



**FIG. 15.73.** Hamstring stretch. Maintain knee extension and stabilize the contralateral limb against the floor. It is helpful to utilize an active phase of resistance and perform the stretch during the relaxation phase.

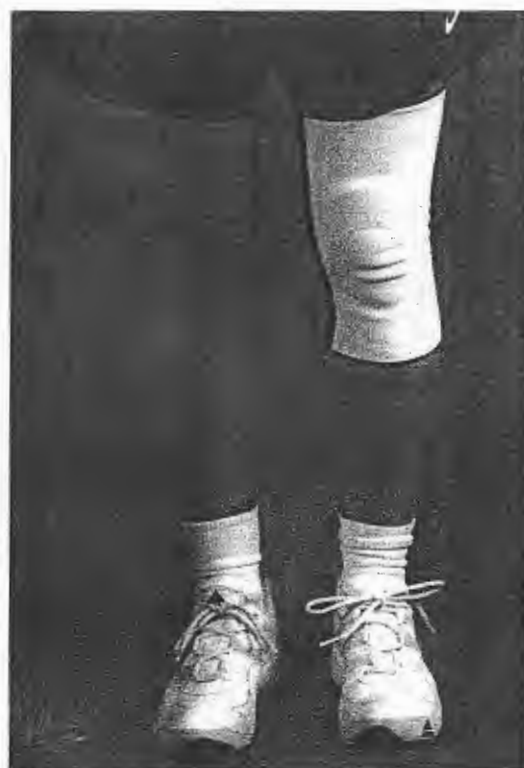



**FIG. 15.74.** Ball squats with adduction squeeze. The patient performs a ball squat in bilateral stance with adduction squeeze against a ball for resistance. Works to improve VMO activity through the origin of the vastus medialis obliquus (VMO) on the adductor magnus.

or forefoot varus can cause excessive pronation with resultant lower extremity internal rotation, again causing a lateral tracking, subluxation, or dislocation. Functionally, decreased strength and neuromuscular control of the anterior and posterior tibialis muscles can also lead to an excessive amount and speed of pronation and lower extremity internal rotation. Whether a structural or functional problem, orthotics that are properly measured and fitted can be a great benefit in the rehabilitation program. All of the previous areas need to be addressed in order to minimize the chance of recurrence.

Extrinsically, bracing and/or taping can be utilized to control the patella. Bracing ranges from a donut pad to a lateral buttress, depending on the severity of the symptoms (Fig. 15.75 to 15.77). Taping attempts to provide external control of the patella for lateral glide, lateral tilt, and rotational dysfunctions (Fig. 15.78). The soft tissue is stretched and the patella is taped to relieve the pain and further relax the offending pathology. The technique can work very well as a long-term solution if the patient actively works on VMO strengthening with the tape in place (165). A dynamic patellar stabilizing brace can serve a similar function (196). The brace consists of an elastic neoprene sleeve with a patella cutout, a lateral pad, and two circumferentially wrapped rubber arms that can



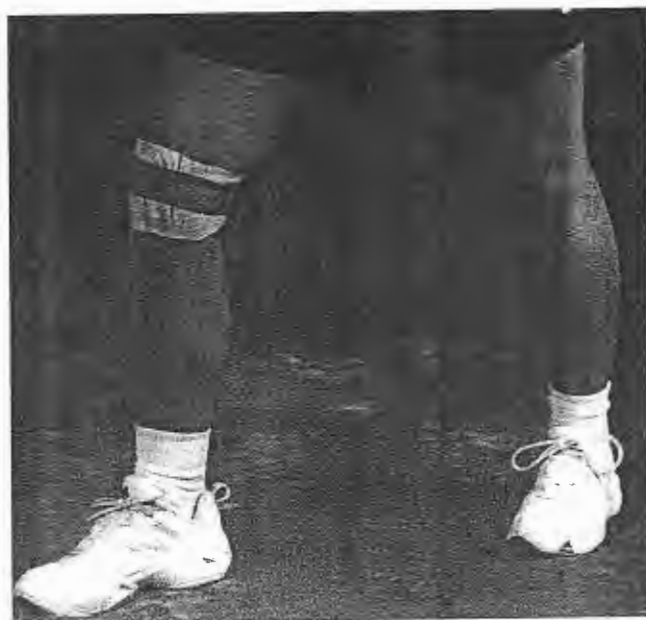**FIG. 15.75.** Elastic support with a donut gel pad.



**FIG. 15.76.** Lateral buttress brace to prevent lateral subluxation/dislocation.



**FIG. 15.77.** On track patellofemoral brace to control patellofemoral malalignment and subluxation.



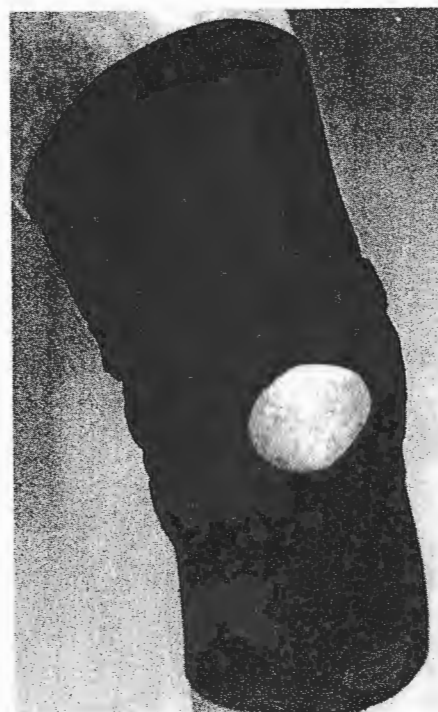**FIG. 15.78.** McConnell taping technique is utilized to medially glide and tilt the patella. Also works with rotational components. Note the bunched-up skin under the tape to provide sufficient tension against the patella.

provide dynamic resistance to lateral patellar displacement (Fig. 15.79).

For resistant or severe cases, operative intervention may be indicated. Athletes with significant lateral patellar tilt and who cannot be rotated past a neutral position are excellent candidates for isolated lateral retinacular release arthroscopically or through a mini-open approach (77,133). All other athletes will probably require a more extensive realignment procedure.

### Rehabilitation After a Lateral Retinacular Release

The immediate postoperative goal is to reduce swelling and limit the scarring of the lateral retinaculum. A foam or felt compression pad is used over the lateral aspect of the knee with overlying ace wrap or compression stockinette. This acts to force swelling out of the immediate wound area and decrease hypertrophic scarring. The use of electrical stimulation for its antiinflammatory effects and also for muscle reeducation after surgery can assist greatly in the rehabilitation process. The application of cold combined with elevation periodically throughout the day can help keep swelling to a minimum. Ice should be used no more than 20 minutes at a time, leaving enough time in between applications for the skin to warm to room temperature. Care should be taken to keep the ice more



**FIG. 15.79.** The Palumbo patella stabilizer places medially directed force on the lateral border of the patella to resist patellar displacement.

proximal and avoid resting it on the common peroneal nerve.

The patient is allowed full weight bearing and is weaned off the immobilizer over a 1- to 2-week period. Active range of motion is begun on postoperative day 1 with heel slides and standing knee flexion. Quadriceps setting and four-way straight leg raises are also initiated at this time. Passively, knee flexion is gently pushed toward full flexion over the first two to three weeks.

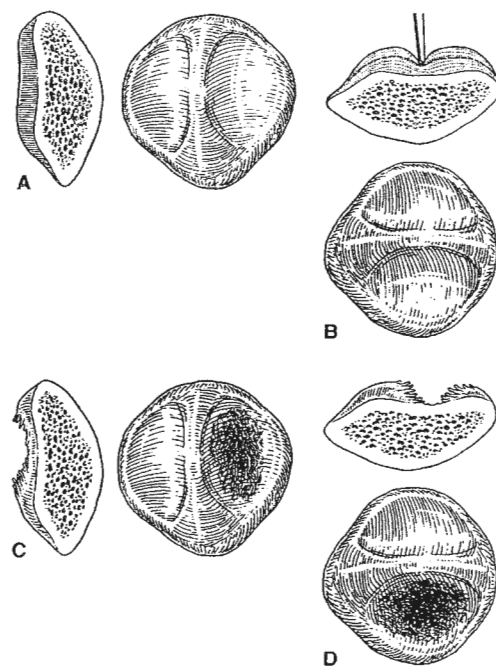
Caution should be taken with stretching too aggressively when significant swelling is still present as repetitive tearing at the surgical site will perpetuate scar tissue formation. Once approximately 95 degrees of flexion has been obtained, the bicycle is added to the program, as are closed kinetic chain lower-extremity, strengthening exercises. The trunk, hip, knee, and lower leg are all included in the rehabilitation program to assure that normal mechanics have been restored and to maximize the chances for surgical success. A brace that has a lateral buttress can serve two functions. First, it can maintain compression over the release and, second, it can provide lateral stability and a medial glide to the patella.

Many authors have discussed a myriad of techniques to address recurrent patellar instability including soft tissue procedures proximal and distal to the patella, and distal bony realignment procedures with successes ranging from 30% to 90% (39,46,71,158,196,212). A successful result depends on proper diagnosis, identification of associated pathologies such as arthritis, meticulous surgical technique, and appropriate postoperative rehabilitation. For skeletally immature athletes, it is best to attempt to use a brace or taping until skeletal maturity is achieved. If necessary, a soft tissue only procedure is indicated with lateral retinacular release, VMO advancement, and occasionally a distal realignment as described by Roux-Goldthwaite (77). For mature athletes all procedures are preceded by diagnostic arthroscopy to assess the presence of degenerative changes of the patella. If the athlete has normal Q angles (less than 20 degrees), mild to no degenerative changes, and no ligamentous laxity, a proximal soft tissue realignment is indicated with lateral release and VMO advancement. If moderate to severe arthritic changes are present a tibial tubercle elevation may be indicated. For athletes with elevated Q angles or increased ligamentous laxity, distal bony realignment should be included with the proximal soft tissue reconstruction. The technique developed by Fulkerson (71,73,114,201) of anteromedialization of the tibial tubercle via an oblique osteotomy has distinct advantages. After diagnostic arthroscopy, the surgeon can adjust the amount of anterior displacement of the tibial tubercle required in relation to the amount of arthritic changes by changing the obliquity of the osteotomy and medialization to unload the damaged cartilage. A significant potential complication following realignment is medial instability (66,99,103).

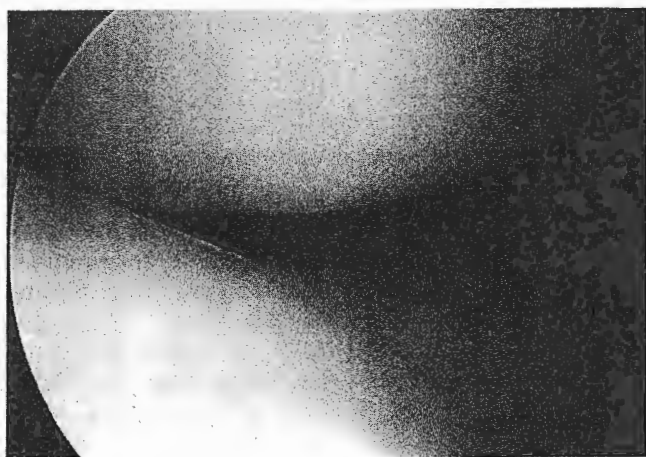
### Patellofemoral Articular Cartilage Involvement

The articular surface of the patella is the thickest in the body and is divided into medial and lateral facets by the median ridge or crest. With repeated wear or contact, the cartilage will begin to soften and progress through a sequence of degeneration that includes fibrillation, fissuring, thinning, fragmentation and finally complete cartilage loss. The athlete will frequently complain of pain when going up stairs or when sitting with the knees flexed for an extended period of time. There will be pain on palpation of the facets and crepitus with range of motion of the knee. Quadriceps atrophy and hamstring tendon tightness are commonly seen.

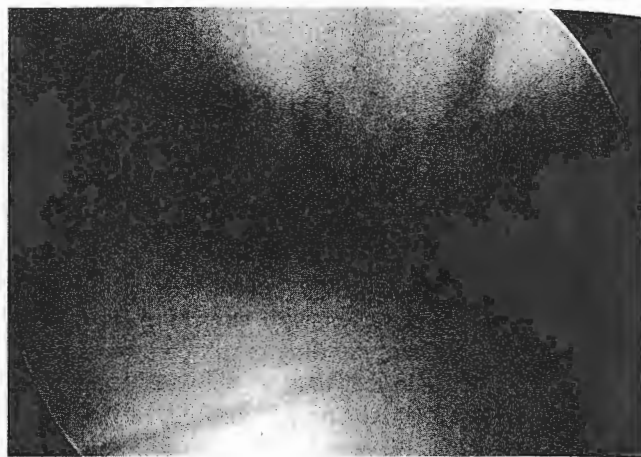
There can be chondral defects, osteochondral fractures, or varying grades of degeneration of the articular cartilage of the patella or trochlear groove. In the past, chondromalacia patella has been used as a "wastebasket" term for most anterior knee pain (21,195,197). The diagnosis is based on the pathology of articular cartilage involvement, and should be made only with visual inspection of the articular surface by open or arthroscopic means. Clinical



**FIG. 15.80.** The Outerbridge classification of chondromalacic change is shown diagrammatically. **A:** Normal articular cartilage of the patella is depicted. **B:** Grade I is softening only, without fragmentation or fissuring. **C:** Grades II and III are fissuring and fragmentation, with II being less than 1 inch and III being more than 1 inch. There is no exposed subchondral bone. **D:** Grade IV is down to subchondral bone. Documentation of the grade and size of the arthritic change is helpful, particularly in the patellofemoral articulation, in predicting success and outlining a rehabilitation program. (Reprinted with permission from ref. 9.)



**FIG. 15.81.** Normal patellofemoral articulation is shown in patient undergoing anterior cruciate ligament (ACL) reconstruction with normal articular surface and tracking.

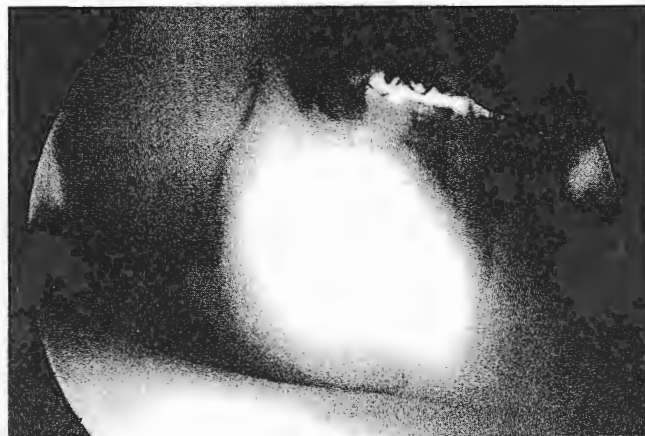
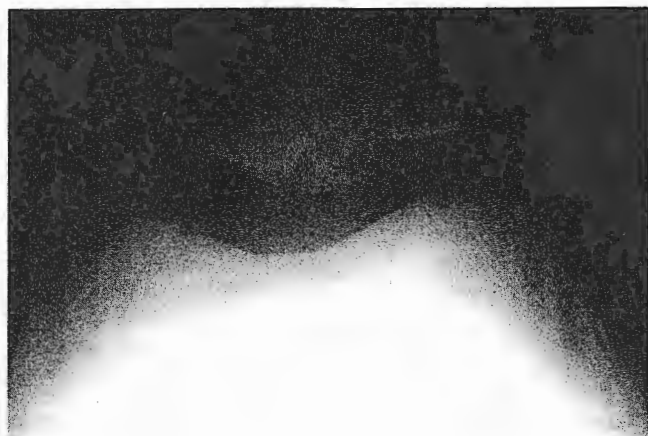


**FIG. 15.82.** Grade III lesion, chondromalacia patella shown arthroscopically.

descriptions should be used for the diagnosis, not the pathologic term "chondromalacia."

The grades (I to IV) of articular cartilage damage have been described by Outerbridge (Fig. 15.80). Grade I is softening. Grade II is fissuring and fragmentation with II being less than 1/2 inch, III being greater than 1/2 inch, and IV to exposed bone. Classification includes size and depth (185). Comparisons of classifications of chondral lesions exist (121). Normal patellofemoral articulation is shown in patient undergoing ACL reconstruction with normal articular surface and tracking (Fig. 15.81). Grade III lesion, chondromalacia patella is shown arthroscopically (Fig. 15.82). This patient had osteochondritis dissecans (OCD) of the patella. Sunrise views show lesion (Fig. 15.82) area measured 1 × 2 cm. These lesions are particularly troublesome for healing. Treatment for focal grade III and IV lesions arthroscopically include micropick, drilling, or abrasion (see Fig. 15.83B). These take a long time to heal, up to a year, and can significantly delay

functional return. Chondrocyte transplantation and allograft reconstruction have not been done long enough or in this age group to be performed routinely. Initially, treatment for articular cartilage problems is conservative and a majority of athletes will respond well. Treatment is focused on optimizing the knee function by improving the muscular balance from a strength and flexibility standpoint. Quadriceps strengthening improves patellar tracking and provides an active shock absorber to share the load of landing. Exercises should be performed in a pain-free arc of motion based on the angle at which the involved area comes in contact with the trochlear groove. Hungerford (105) has shown that contact stresses of different regions of the patella vary with the angle of knee flexion. Hamstring stretching reduces the forces that the quadriceps must overcome to attain extension, thereby reducing the patellofemoral joint reaction force. Occasionally, cushioned shoe inserts or encouraging the use of cushioned running shoes will further share the load of impact and reduce the patient's complaints. Adjuvant



**FIG. 15.83. A,B:** This patient had OCD of the patella. Sunrise views show lesion area measured 1 × 2 cm. Arthroscopic debridement of the loose osteochondral patellar fragment is shown.

treatment including ice and antiinflammatories can reduce pain to allow the athlete to participate in rehabilitation.

Resistant cases may require surgical intervention. Arthroscopy is an excellent tool that can confirm the diagnosis and provide initial treatment. Unstable cartilaginous fragments or loose bodies can be removed with excellent results. The cartilaginous defects are debrided and saucerized. Abrasion chondroplasty, microfracture with arthroscopic awls, or drilling has shown limited success on the femoral condyles but has had uniformly poorer results when used on the patellofemoral joint. Debridement of the lesion can reduce the chance for occurrence of loose bodies. Tibial tubercle transfer or elevation can be performed to reduce the stress on articular cartilage and improve tracking. In the most resistant and severe cases, patellectomy can be performed; however, significant functional weakness will invariably occur and complete pain relief is rare.

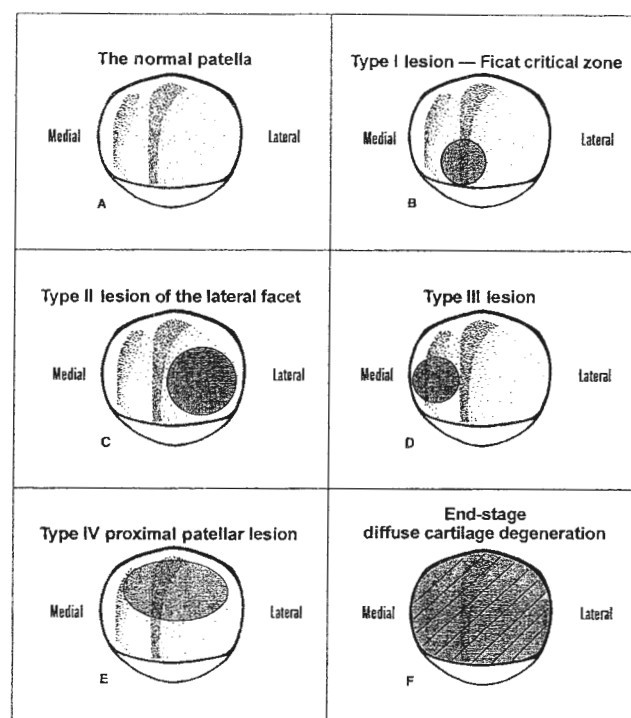
At the time of arthroscopy, documentation of the patella or trochlear groove articular surface defects with size and depth and contact areas by degrees of flexion should be performed (77) (Fig. 15.84). A rehabilitation program can then be outlined in the arc of motion that does not cause direct pressure and is not under the greatest contact. If surgical intervention is required, the surgeon must transfer the forces from the damaged tissues and also restore stability of the patellofemoral articulation. The PF articulation will deteriorate at an accelerated pace if pressure is increased (4).

### Plicae

A synovial plica is a fold in the synovium, which is a residual of an embryologic synovial septum. The knee may have up to four plicae named by location—the suprapatellar, infrapatellar, lateral, and medial. Most synovial plicae are asymptomatic but occasionally a plica can become inflamed from direct contact or overuse. The medial plica can be associated with chondral injury to the medial patella or defect in the nonarticulating medial femur.

The athlete complains of pain aggravated by activity or prolonged sitting. Some athletes complain of snapping, clicking, or the sensation of giving way on physical exam. Repetitive squatting and deep flexion often exacerbate the athlete's complaints. Symptomatic plica syndrome is more common in females and sports like gymnastics, cheerleading, and running. The thickened band is painful just superior to the medial femoral condyle and medial patellar facet.

Initial treatment is aimed at decreasing inflammation by using ice, local modalities, topical nonsteroidals, oral antiinflammatories and activity modification. Rehabilitation includes quadriceps strengthening, hamstring stretching, and correcting any weakness at the trunk, hip, and ankle that may be affecting normal knee function. Rovere



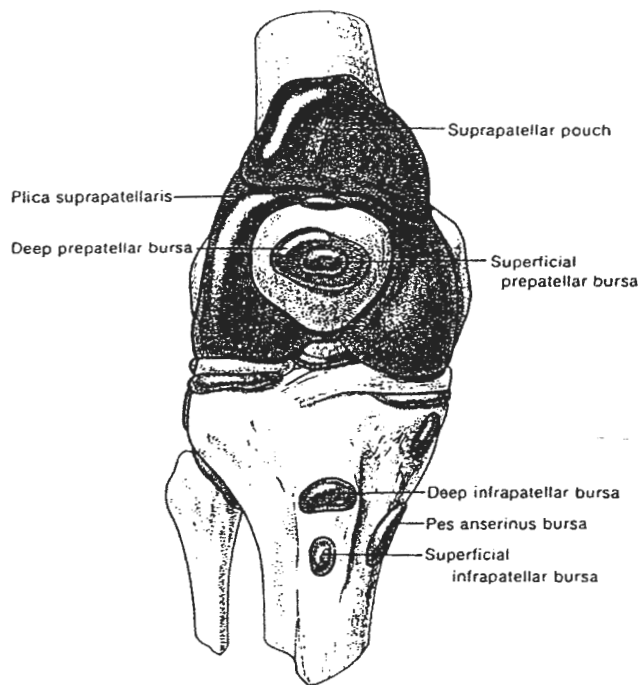
**FIG. 15.84.** A. A representation of the normal patella (medial left; lateral right). B. A type I lesion (Ficat critical zone) at the distal central ridge. C. A type II lesion of the lateral facet is usually related to excessive lateral pressure with tilt. This lesion is often associated with a type I lesion, and the two lesions may connect, particularly in a patient with long-standing lateral patellar tilt and subluxation. D. A type III lesion will occur related to relocation of a patella following dislocation, with shearing off of the medial facet. Lesions of the medial facet also occur from excessive medial overload (overzealous medial imbrication or Hauser transfer of the tibial tubercle). E. The proximal patellar lesion (type IV) that spans the facets is most often related to a crush, knee flexion injury (dashboard type) in which the proximal patella is articulating (knee flexed) at the time of impact. F. End-stage diffuse patella articular cartilage degeneration. (Adapted from and reprinted with permission from ref. 16.)

and Adar (213) suggested intraplica steroid and lidocaine injection. In 73% of patients lasting relief and return to sport was achieved. In cases not responding to rehabilitation and activity modification, arthroscopic resection of the symptomatic plica is indicated. At the time of arthroscopy, associated disorders such as chondral injuries or meniscal tears can be addressed.

### Bursitis

Bursae are fluid-filled sacs that function to reduce friction and protect structures from pressure. The subcutaneous locations are shown (257) (Fig. 15.85). Bursal tissue becomes thicker and painful with increased blood flow from inflammation or contusion. Irritation and accompanying bursitis can result from acute or chronic trauma,





**FIG. 15.85.** Bursae in the front of the knee can mimic many knee disorders. These bursae should be examined in the evaluation of patients with anterior knee pain. (Reprinted with permission from ref. 77.)

inflammatory processes with metabolic deposits, or acute or chronic infection (48). Wrestlers, gymnasts, and football players are at increased risk of bursitis, particularly in the prepatellar bursa, from repeated contact. Acute hemorrhagic bursitis caused by small vessel rupture should be differentiated from inflammatory bursitis. The pes anserine bursa lies proximal to the insertion of the sartorius, gracilis, and semitendinosus tendons (the pes anserinus). The bursa lies between the aponeurosis of these tendons and the medial collateral ligament about 2 inches below the anteromedial joint line. Pes bursitis is more commonly caused by repeated friction rather than direct contusion (193).

Treatment is symptomatic with ice therapy, compression wraps, and antiinflammatories. Early motion, strengthening exercises, and even muscle stimulation can prevent muscle atrophy and enhance the athlete's early return to sport. Steroid injections in the pes anserine bursa can relieve the inflammatory process. Aspiration of the prepatellar bursa without steroid injection has also been recommended. Indications for surgical excision in athletes include multiple recurrences or an extremely large, chronically inflamed bursa extending beyond the diameter of the patella (193). Septic bursitis is treated by aspiration, culture, and appropriate surgical debridement.

### Iliotibial Band Syndrome (ITB)

The iliotibial band originates from the gluteus maximus and tensor fascia latae. ITB syndrome is especially preva-

lent in joggers and cyclists. In jogging, there is a flight phase with no support. Upon impact, the hip and thigh must provide a significant contraction to stabilize the pelvis in a horizontal fashion against the ground reaction force. These strong, repetitive contractions typically result in decreased flexibility in the hip abductors and iliotibial band. The ITB moves over the femoral epicondyle anteriorly in extension and posteriorly in flexion. Direct tenderness over the ITB band is common. The patient's knee is flexed to 90 degrees and supported. Palpation of the ITB on the femur just proximal to the epicondyle is done and the knee is slowly extended. At 30 degrees of flexion, the patient complains of pain as the inflamed portion of the ITB is compressed between the examiner's thumb and the femoral epicondyle.

Primary treatment should be directed toward improving flexibility in the shortened tissues of the gluteus maximus, tensor fascia latae, and iliotibial band. The ITB can be stretched in standing or kneeling. In the kneeling position, one can often get a medial glide of the patella as well. Bringing in hip extension and adduction with the lean of the body allows for a good proximal quadriceps, gluteus medius, tensor fascia latae, and ITB stretch (Fig. 15.86).



**FIG. 15.86.** Combined ITB band and quadriceps stretch. With patellofemoral pain, something soft may need to be placed under the knee. Keeping the stomach tight, forward lean to gain stretch in the quadriceps proximally followed by a slight lateral shift to change the emphasis to the superior lateral thigh.



Gaining flexibility in these tissues takes time and can be aided by the use of ultrasound and moist heat to improve tissue extensibility prior to stretching and iontophoresis, electrical stimulation, and ice to decrease inflammation after treatment. A thorough biomechanical evaluation should be completed to address any causative factors present at the hip, knee, and ankle. Taking a detailed history to determine training-factor influence such as road surface, mileage, and shoe wear is also helpful. Addressing weakness in the trunk, hip, knee, and lower leg can improve mechanics and efficiency as well as prevent further injury.

## MENISCAL TEARS

### Meniscal Tear Patterns

The classification of the tear pattern is described by location within the substance of the meniscus and the tear pattern. Types include radial, horizontal, longitudinal, degenerative, flap, or combinations of these (70) (Fig. 15.87). Meniscal tears are one of the most common knee injuries in the athletic population. Typically, the athlete presents with swelling, pain along the medial or lateral joint line, locking, and/or popping. Locking and inability to extend the knee after rising from a crouched position is present in 81% of patients with a bucket handle tear of the meniscus (229).

The most common finding on physical examination is pain with palpation or associated with provocative maneuvers. Bounce home, McMurray's, Apley's grind (10), and pain with varus or valgus stress all attempt to trap the torn meniscus between the tibial plateau and ipsilateral femoral condyle to elicit a diagnostic pain and pop. If pain alone is present, degenerative articular changes may also be the source of pain. Clinical squatting maneuvers with weight bearing or "standing McMurray's" are ex-

cellent added tests to discover subtle tears that may have evaded diagnosis with the other exams (5).

Routine radiographs include anterior-posterior, lateral, notch view, and bilateral patellar sunrise views. If the athlete is greater than age 50, standing 30 degrees flexed posteroanterior (PA) views are done to assess the joint space for degenerative arthritis. Magnetic resonance imaging is indicated if there are other intraarticular problems, associated ligament problems or confusion about the diagnosis (80,137,211). The majority of meniscus tears can be diagnosed by history and physical exam (80,95,124,173). Accuracy, sensitivity and specificity are extremely high for meniscal tears, better with the medial than lateral meniscus. A discoid lateral meniscus is a congenitally large meniscus that may occupy the entire articulating surface between the lateral femoral condyle and tibia. Symptoms of pain and clunking in the lateral compartment in adolescents is the common presentation. MRI scans can visualize these nicely aiding in the decision between surgical or nonsurgical treatment.

### Treatment

Initial conservative management of relative rest, strengthening, compression, and decreasing joint effusion is performed. If recurrent mechanical signs and symptoms are present, arthroscopic intervention is indicated. At the time of surgery, a decision must be made regarding removal or repair of the torn meniscus. Attempt is made to repair menisci in the peripheral third or vascular zone. Central tears are avascular and have little ability to heal. If partial meniscectomy is required, removing as little of the meniscus as needed is the rule. Meniscus repair has a greater success rate in association with ligamentous reconstruction than in the cases of isolated meniscal surgery. There have been advances in meniscal transplantation with allografts. Initial reports of cryopreserved allograft transplantation in dogs were published in 1984 (13).

Meniscal tear patterns vary but principles of removal of the unstable fragments and restoring a balanced rim are followed routinely. A bucket handle tear of the meniscus or vertical pattern in orientation can displace into the notch (Fig. 15.88). Partial meniscectomy was performed.

The posterior horn flap tear was displacing in the medial gutter causing symptoms and mimicking a loose body (Fig. 15.89). This complex tear of the medial meniscus was resected with a handheld punch (Fig. 15.90).

Meniscal repair is done when the tear is in the red-white zone or peripheral third, usually vertical, and in a younger patient. Probing of the tear and repair with inside to outside techniques placing sutures arthroscopically is performed (Fig. 15.91A). The sutures are placed with a long needle, which can also be used for trephination to increase blood supply (see Fig. 15.91B).

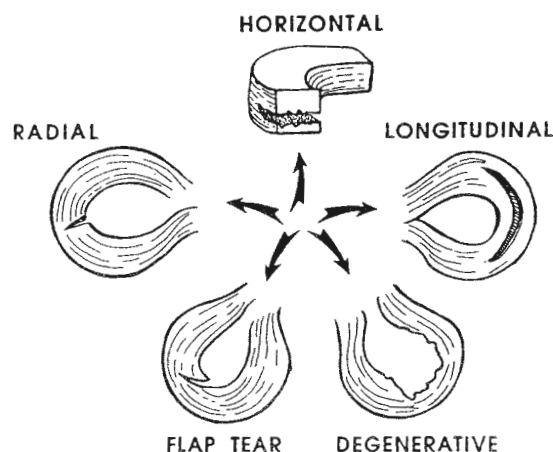
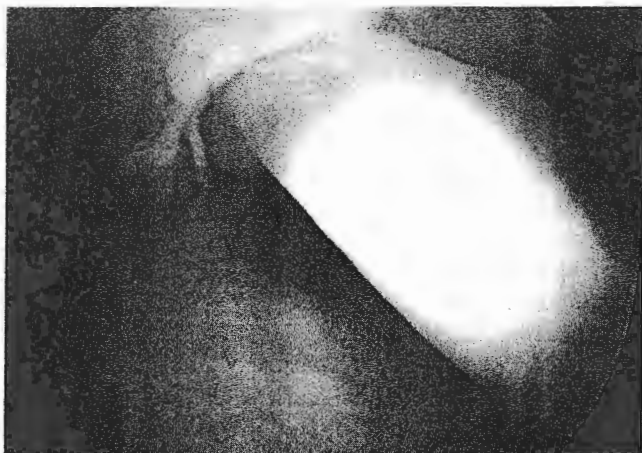


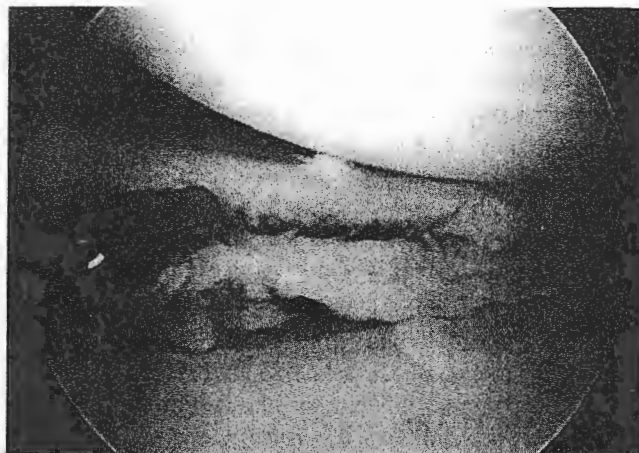FIG. 15.87. Schematic illustration of the five main types of meniscal tears. (Reprinted with permission from ref. 57.)



**FIG. 15.88.** In this left knee, arthroscopically, a vertical bucket handle tear is shown displaced into the notch. The anterior cruciate ligament is absent in the notch in this chronically injured anterior cruciate ligament (ACL) patient.

### Rehabilitation of Meniscal Repairs

Communication between the surgeon and the rehabilitation team is critical with meniscal repairs (see Fig. 15.91). The site of the repair makes a big difference in the course of rehabilitation. If the tear is in the vascular zone, healing is better and the patient may be allowed to progress to touch down weight bearing earlier. If the

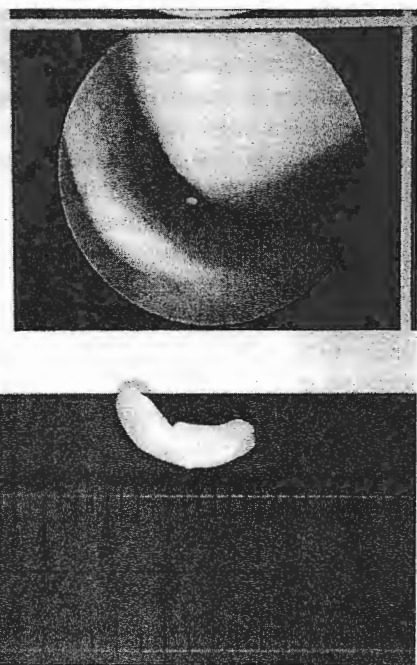


**FIG. 15.90.** A complex tear of the medial meniscus with more unstable tibial side is resected using a handheld punch.

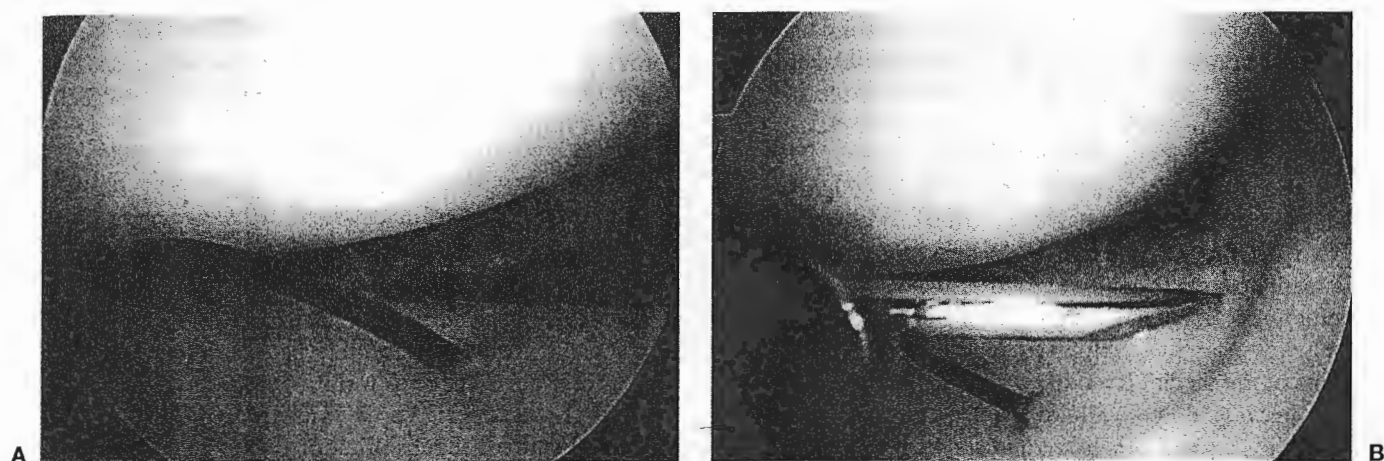
vascularity of the repaired tissue is in question, the repair must be protected for a longer period of time. The patient should be toe touch to foot flat at 10% to 20% weight bearing for 2 to 4 weeks with range of motion limited to avoid hyperextension and flexion greater than 90 degrees. Extreme range of motion may cause increased strain on the repair. Isometrics and mid-range exercises in an open kinetic chain are initiated along with active range of motion in the prescribed range. Utilization of a stationary bicycle with no resistance can be effective for range of motion and to stimulate healing of the meniscus. The bicycle should be used in a rocking fashion; that is, forward and backward without a complete revolution, unless the complete revolution can be accomplished pain-free and with ease. When weight bearing is allowed, the exercise regimen is adjusted to include closed kinetic chain exercises, avoiding motions that bring the knee into greater than 90 degrees of flexion. Once again, the rehabilitation includes strengthening the trunk, hip, knee, and lower leg to control abnormal forces.

### Articular Surface Injuries

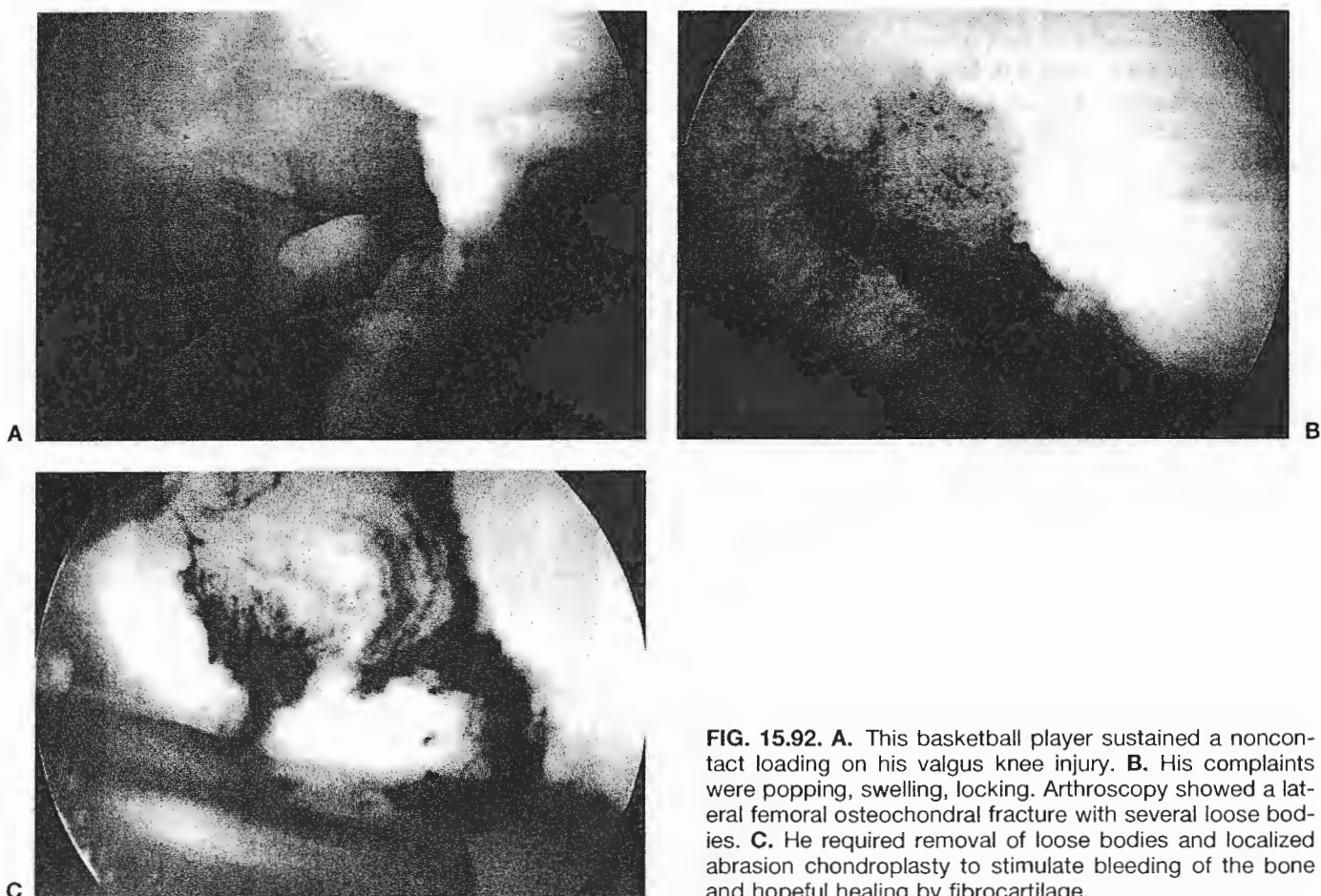
Historically articular cartilage defects have been difficult to treat and an ulcerated cartilage will not heal (106). Genetics, alignment and the nature of the sport are contributing factors to articular cartilage health. Chondral and osteochondral fractures can occur and can be confused with meniscal injuries. If there is an effusion, increased crepitus on exam, history of axial loading in an adolescent with possible osteochondritis dissecans, articular surface injury should be highly considered (222). In soccer athletes, articular cartilage delamination has been reported (145). This basketball player sustained a noncontact knee injury landing from a rebound. His complaints were popping, swelling, locking. Arthroscopy showed a lateral femoral osteochondral fracture measuring  $2 \times 2$  cm (Fig. 15.92A). He



**FIG. 15.89.** View of posterior horn flap tear, view of anterior horn flap tear of the meniscus medially. The flap was in the medial gutter causing symptoms and mimicking a loose body. Shown is the medial femoral condyle, the displaced meniscal fragment and excised piece itself.



**FIG. 15.91. A:** Peripheral tear of the medial meniscus shown in the red/white zone with one suture placed and probe in tear. **B:** The needle through a cannula will introduce more anterior sutures to anchor the meniscus back to the capsule.



**FIG. 15.92. A:** This basketball player sustained a noncontact loading on his valgus knee injury. **B:** His complaints were popping, swelling, locking. Arthroscopy showed a lateral femoral osteochondral fracture with several loose bodies. **C:** He required removal of loose bodies and localized abrasion chondroplasty to stimulate bleeding of the bone and hopeful healing by fibrocartilage.

required removal of loose bodies, and unstable articular cartilage abrasion chondroplasty, to stimulate bleeding of the bone (see Fig. 15.92B). Documentation of bleeding is done by reducing inflow of fluid (see Fig. 15.92C). The hopeful result is fibrocartilage ingrowth.

This 16-year-old baseball and football athlete complained of pain, swelling, and occasional locking of his left knee. Clinically, he had tenderness on palpation over the medial femoral condyle, mild effusion, no medial or lateral joint line tenderness and stable ligaments. The notch view was most helpful to show osteochondritis dissecans of the medial femoral condyle (Fig. 15.93A). MRI scan after injection of gadolinium dye in the joint demonstrates the depth of the lesion and shows the defect in the medial femoral condyle in its typical location just lateral to the attachment of the PCL (see Fig. 15.93B, *arrow*). He underwent abrasion chondroplasty and at one year returned to football activities.

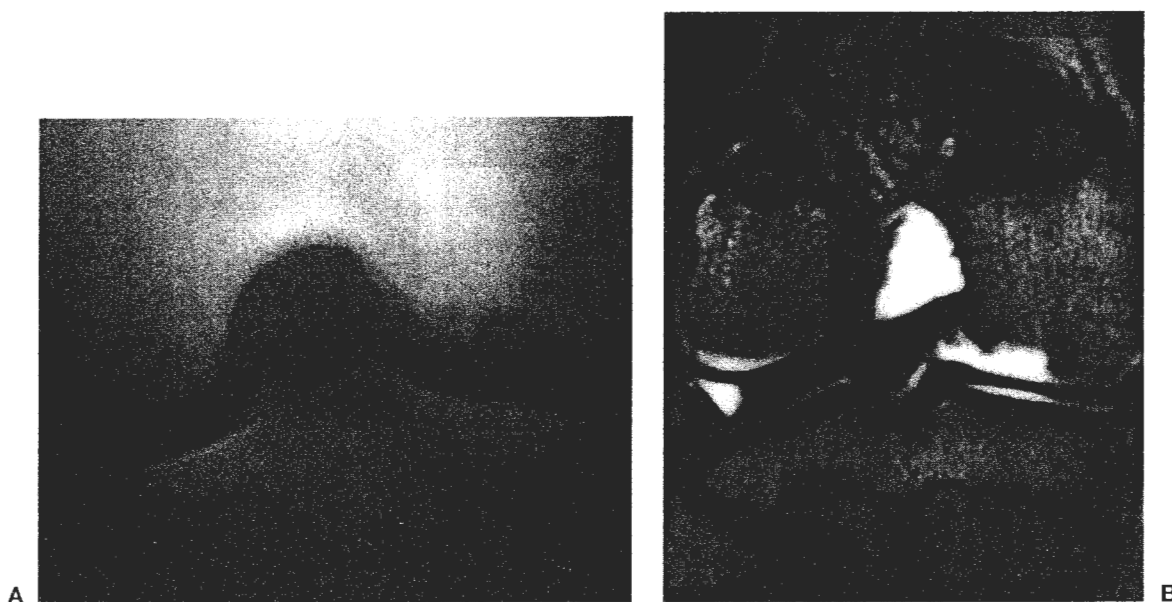
Counseling of athletes, particularly with lateral compartment involvement must be done early on. The likelihood of being able to play professional sports with a past history of arthroscopy and articular surface damage in the lateral compartment in a valgus knee is very small. Changing cardiovascular activities to reduce axial load is routinely discussed with the patient.

The future for treatment of articular surface defects is bright. Various techniques to stimulate blood supply exist. These include abrasion chondroplasty, microfracture techniques and drilling. Taking plugs of bone from a non-weight-bearing surface of the knee peripherally in the trochlear groove and transplanting this to the prepared

condyle defect is now being done with the early results proving effective. Harvesting and culturing of articular cartilage and reimplantation of the cartilage is also being done in limited settings (30).

### Rehabilitation of Injuries with Articular Surface Damage

Injuries involving damage to the articular surface can be very difficult to rehabilitate because of the nature of the injury: the damage to weight-bearing surface that has no inherent ability to "protect itself." The surgeon must communicate to the rehabilitation team where the damage was found and the range of motion that has been affected by the damage. The rehabilitation professional then has the information to develop a plan of care that will effectively strengthen the lower extremity while avoiding any undue stress on the damaged articular surface. In general, bicycling is beneficial as it is a non-weight-bearing activity that promotes regrowth of articular cartilage. Use of modalities, particularly electrical stimulation for muscle contraction and work on decreasing inflammation, can be used effectively with ice to keep swelling down. Exercises that are isometric in nature, non-weight-bearing, or done through a limited, pain-free arc are most beneficial in the beginning stages of rehabilitation. After abrasion chondroplasty, the articular surface must be protected from repetitive axial loading. Patient education and activity modification are mandatory for the long-term success of these patients.



**FIG. 15.93. A:** Osteochondral dissecans of the medial femoral condyle shown on the right knee. Notch view is best to demonstrate this. The radiolucent area involving the entire medial femoral condyle is shown. Magnetic resonance imaging (MRI) scan (**B**) shows the extent of the lesion involvement into cancellous bone and location adjacent to the posterior cruciate ligament. Ligament of Wrisberg is also shown attaching the posterior cruciate ligament to the lateral meniscus (*arrow*).

## Medial Collateral Ligament Injuries

Medial collateral ligament (MCL) sprains are very common in sports. MCL injuries typically occur when the foot is planted and the athlete sustains a blow to the lateral aspect of the knee. The treatment has evolved with increased knowledge obtained by arthroscopy and MRI. Grade I and II sprains and most isolated grade III MCL injuries can be treated nonoperatively. The more severe grade III MCL sprain is often associated with other ligamentous injuries. It is unusual to have an associated meniscal injury with an isolated MCL sprain since the mechanism is usually contact distracting the MCL. The pain is usually over the femoral attachment of the MCL. The "degree" of valgus opening should be established based on comparison with the other side and the knee should be stable and symmetrical in extension and different in 30 degrees of flexion.

In the 1980s surgical management of grade III MCL was commonplace (101,175,192). Now clinical diagnosis and nonoperative management is the rule for MCL sprains. We have seen treatment of medial injuries significantly change. There can be some problem from medial instability in ice hockey athletes (112,128), and these may require repair for an isolated grade III sprain. However, the current standard is nonoperative treatment and aggressive return to play. Grade I injuries involve initial rest and return to sport within a couple of weeks. Grade II may be slightly longer and grade III may require immobilization or protected weight bearing slowing their return for 6 to 8 weeks. Initial immobilization and non-weight-bearing may tighten up the medial structures more and result in less instability. However, healing generally occurs best with controlled mobility. Since isolated medial instability has not been shown to increase articular surface injury or knee problems, aggressive return to play and nonoperative treatment is presently the rule. Lateral knee braces have been used in hopes of preventing knee injuries, particularly in higher-risk positions in contact sports. These prophylactic or preventive braces attempt to protect the primary medial restraint that is the MCL. However, most scientific studies have yet to prove that lateral knee braces reduce the incidence of knee ligament injury (14,15,79,88,93,172,214,215,259,261). In controlled studies in the military, some reduction in the severity of injury with the brace has been shown (261). Indeed, in a survey of athletic traumas, a potential increase in injury, particularly fibular fracture and peroneal nerve injury secondary to the use of prophylactic braces has been reported (240). There are also questions as to whether braces preload the ligament. Certain criteria were set forward at the knee brace seminar report (59). A position statement from the AAOS states that "the routine use of prophylactic knee braces has not been proven effective in reducing the number or severity of knee injuries." In some circumstances, such braces may even potentially be a contributing factor to injury. Requiring players to

use knee braces "just in case they might help" is not supported by the studies that have examined the effectiveness of such "braces."

If a brace is requested and the athlete is in a higher risk position, such as a football lineman, a thorough discussion with the athlete, his family, and his coach should be undertaken to assure the risks and benefits are understood. It should be stressed that there is still a chance for injury while wearing these braces.

## Rehabilitation of Medial Collateral Ligament

Conservative treatment of medial collateral ligament (MCL) sprains has become more aggressive in recent years. Excellent results can be achieved if the rehabilitation program is approached in an aggressive, systematic manner, predicated on the attainment of milestones and healing time frames.

### Grade I MCL Sprains

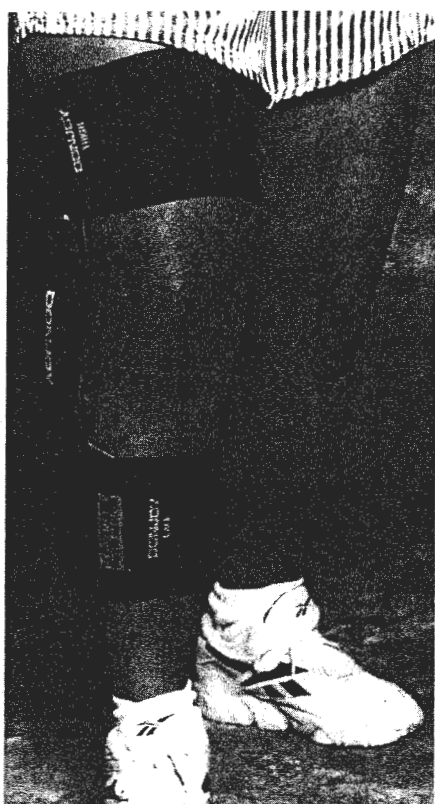
Grade I MCL sprains are treated with the knee immobilized for 1 week. Ice is used daily until pain and inflammation are under control. Quadriceps and hamstrings setting exercises (isometrics) may need to be done in 10 to 20 degrees of flexion to avoid pain in the end range of extension. Both open and closed chain exercises can be progressed as tolerated, as can range of motion. Achieving extension past 0 degrees extension (recurvatum) or 90 degrees flexion should be delayed until week two if still painful. Functional exercises and activities can be progressed aggressively as strength, neuromuscular control, and pain allow.

### Grade II and III MCL Sprains

Grade II and III MCL sprains are treated in the initial 2 days with an emphasis on reducing pain and inflammation and protecting the MCL with an immobilizer or range of motion brace, limited to the pain-free range. The athlete will remain in a weight-bearing as tolerated status for 10 to 14 days. The doctor may order non-weight-bearing, depending on the severity of the sprain. Isometric quad sets and ham sets, straight leg raises in flexion, abduction and extension (avoiding the adduction motion), and PROM/AAROM to maintain range of motion are performed. Electrical stimulation for pain control, edema control, and muscle stimulation is utilized throughout the first week or two. Frequent application of ice will help reduce pain and swelling.

The tissue should warm and return to normal color before reapplying the ice. After the first 2 or 3 days, pain will be the limiting factor for weight bearing, range of motion, and exercise. The bicycle is used for gentle range





**FIG. 15.94.** Lateral knee bracing. Prophylactic knee bracing, primarily used for collision sports to prevent knee injury.

of motion in a comfortable range. "Rocking" back and forth may be needed until a sufficient pain-free range is obtained. Swimming can begin with a gentle straight flutter kick only. Isometrics are performed at multiple angles, and gentle quadriceps exercises are begun through a pain-free range of motion. The brace is worn all the time at night and during the day as needed. Activity is immediately modified with any increase in pain, swelling, or instability. Well-leg exercises are performed during this period to maintain strength and endurance.

Once swelling and pain have stabilized with phase one activities and the athlete has a relatively pain-free range of motion from 100 degrees to 10 degrees, then they are ready to begin phase II. Goals for phase II include full, pain-free range of motion, normal gait, and restoring full lower extremity strength.

The focus of the second week is to progress strength and range of motion (ROM). Pool exercises can be advanced to weight bearing and jogging as tolerated. Bicycle work is increased for both time and resistance. Stretching exercises for the quads, hamstrings, ITB, and gastrocnemius are begun as long as the athlete remains pain-free. Proprioception exercises are advanced to facilitate full return of neuromuscular control. Closed kinetic chain exercises such as lunges, lateral step-ups, retro-walking, and stairmaster are advanced in duration and range of motion. When full pain-free flexion and extension have been achieved and strength and neuromuscular control are nearing 75% of the uninvolved side, a running progression can begin. The last step before a return to play is sports specific drills that are progressed slowly to allow the healing MCL to adapt to the new stresses. Lateral bracing may be needed to reduce medial stress and protect the healed tissue (Fig. 15.94). These types of braces can also be used prophylactically.

## GROWTH PLATE INJURIES

In the skeletally immature athlete, the fracture about the knee with the most potential for complication is in the distal femur (31,167,177,198). The absolute number and percentage of all epiphyseal fractures for the distal femur, tibial tuberosity, proximal tibia, and proximal fibula are reported as shown (Table 15.6). In three series reporting the relative incidence of all physeal injuries, distal femur accounted for 5.0% (167), 5.5% (198), and 1.2% (177); proximal tibia 1.9% (167), 1.8% (198), and 0.7% (177); tibial tuberosity 3.1% (167), 0% (198), and 0% (177).

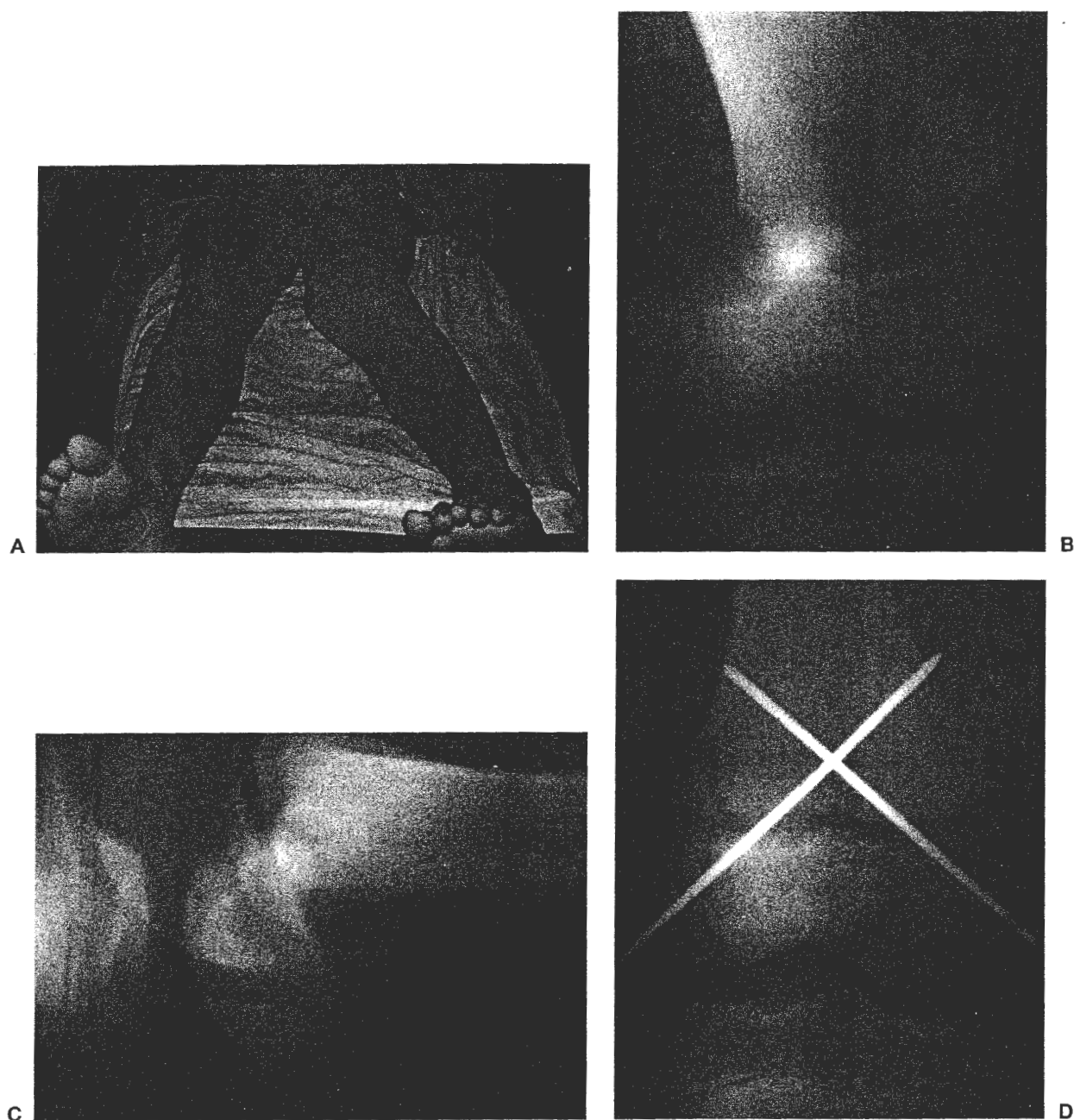
In 2,137 reported cases of athletic injuries in children, epiphyseal fractures involving the knee numbered 58 and the majority were Osgood-Schlatter's (41). There does not appear to be greater risk of growth plate injuries during competitive athletics than in other activities (139,140). If the athlete is hit about the knee and has pain over an epiphyseal plate, plain radiographs and stress views are indicated.

This skeletally immature football athlete sustained a blow to the outside of his left knee. The valgus, internal rotation deformity is shown (Fig. 15.95A). He sustained

**TABLE 15.6.** Lower extremity epiphyseal fractures

	Ogden 721		Peterson 330		Neer 2500	
Total # in Study:	Number	Percent	Number	Percent	Number	Percent
Distal femur	36	5.0%	18	5.5%	28	1.1%
Proximal tibia	14	1.9%	6	1.8%	17	0.7%
Proximal fibula	4	0.6%			2	0.1%
Tibial tuberosity	22	3.1%				
Combined knee	76	10.5%	24	7.3%	47	1.9%





**FIG. 15.95. A:** This 14-year-old male was playing football, foot was planted, he was hit from the outside of his knee and had a Salter II fracture of the distal femur. **B,C:** Radiographs are shown. Emergency treatment is splinting the leg as it lies and transport to hospital. Treatment is with gentle reduction and internal fixation (**D**).

a Salter II fracture of the distal femur. Plain radiographs of AP (see Fig. 15.95B) and lateral views show the displaced distal femur fracture (see Fig. 15.95C). Emergency treatment includes splinting the leg as it lies and transport to hospital. Treatment is with gentle reduction and, in appropriate cases, internal fixation (see Fig. 15.95D). Potential complications from this fracture include leg-length discrepancy and angular deformity, usually in a progressive varus of the knee.

## ANTERIOR CRUCIATE LIGAMENT (ACL) INJURIES

### Skeletally Immature

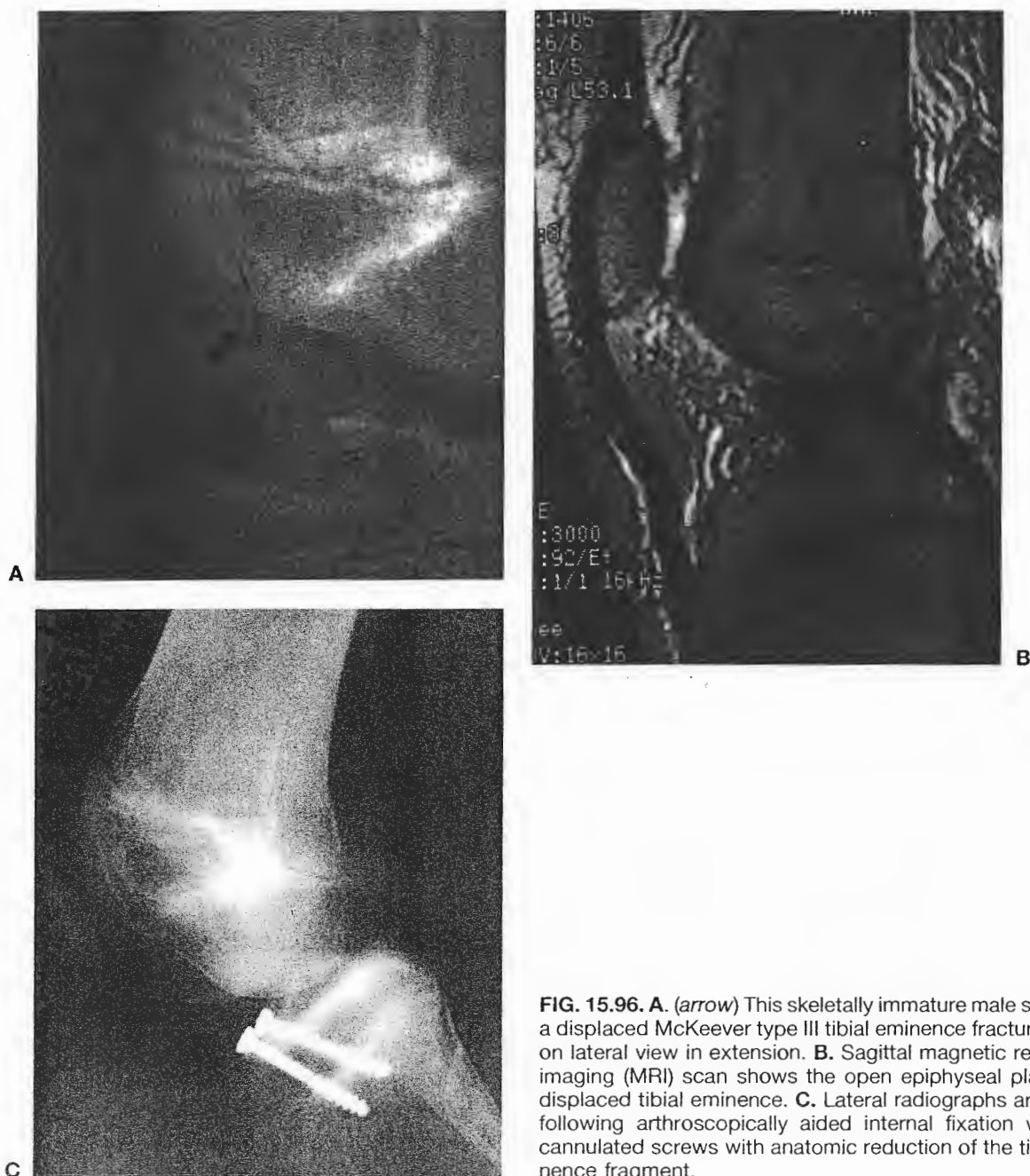In the skeletally immature patient, a tibial eminence avulsion fracture can occur rather than the typical mop end mid-substance tear of the ACL (162,167). A dis-

placed McKeever type III tibial eminence fracture is shown in AP and lateral view (Fig. 15.96A, *arrow*). If the fragment does not reduce on extension, reduction and fixation is indicated.

An MRI scan was obtained (see Fig. 15.96B). On the lateral view the ACL can be seen to attach to the tibial eminence fragment, which is displaced. Oftentimes, the anterior horns of the medial and lateral menisci, or the intermeniscal ligament, can become interposed and pre-

vent reduction. Arthroscopically aided internal fixation was done with two cannulated screws as shown in the lateral view (see Fig. 15.96C).

With a mop end ACL tear an extraarticular reconstruction, using iliotibial band to avoid the epiphyseal plates, can be performed. With central plate closure, ACL reconstruction can be done with intraarticular reconstruction by femoral over the top and on the tibial above the epiphyseal plate (139,163,227).



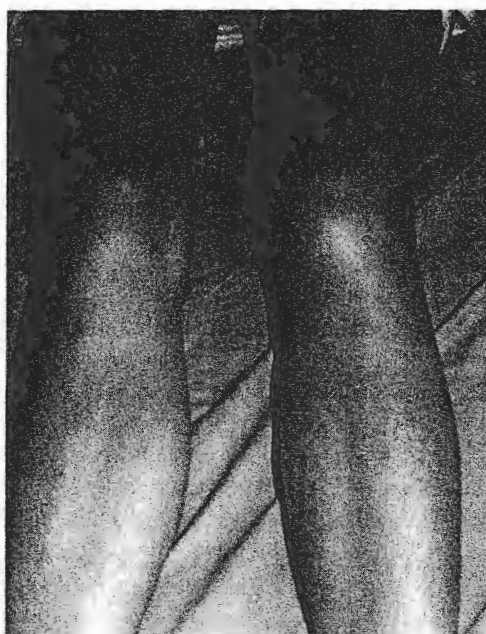**FIG. 15.96.** **A.** (*arrow*) This skeletally immature male sustained a displaced McKeever type III tibial eminence fracture shown on lateral view in extension. **B.** Sagittal magnetic resonance imaging (MRI) scan shows the open epiphyseal plates and displaced tibial eminence. **C.** Lateral radiographs are shown following arthroscopically aided internal fixation with two cannulated screws with anatomic reduction of the tibial eminence fragment.

### Skeletally Mature

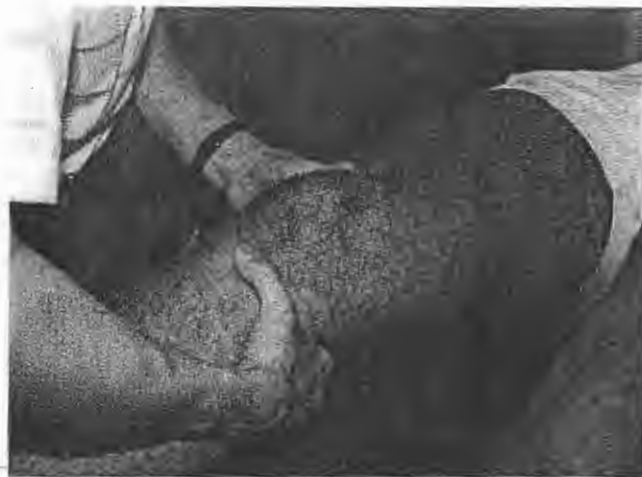The typical history for an ACL tear includes a noncontact mechanism, changing direction, feeling a shifting and "pop," followed by swelling within a couple of hours. This left knee shows an acute hemarthrosis that occurred two hours after knee injury (Fig. 15.97).

Tests performed to diagnose an ACL tear include the Lachman, anterior drawer, and pivot shift. In the Lachman test, an anterior force is applied with the knee 30 degrees flexed and the proximal calf is supported by examiner's leg, pillow, or table (Fig. 15.98). The pivot shift maneuver has been described by various authors as going from flexion to extension and subluxating, or going from extension to flexion and relocating. A pivot shift is shown in the 30 degrees flexion position, applying internal rotation and anterior translation, a coupled movement of the tibia, with a clunk or shifting sensation being felt as the tibia subluxes. An MRI scan is performed if the diagnosis is unclear. There is need to document meniscal injury or bone bruise if surgery is not going to be performed. MRI scan shows a bone bruise in the middle portion of the distal femur and the posterior aspect of the tibia. When the tibial subluxation is in anterolateral rotatory direction, the bone bruise pattern can be easily understood (Fig. 15.99).

The treatment of ACL tears is by reconstruction, rather than primary repair. The complete midsubstance failure makes the ligament tissue abnormal and nonrepairable.



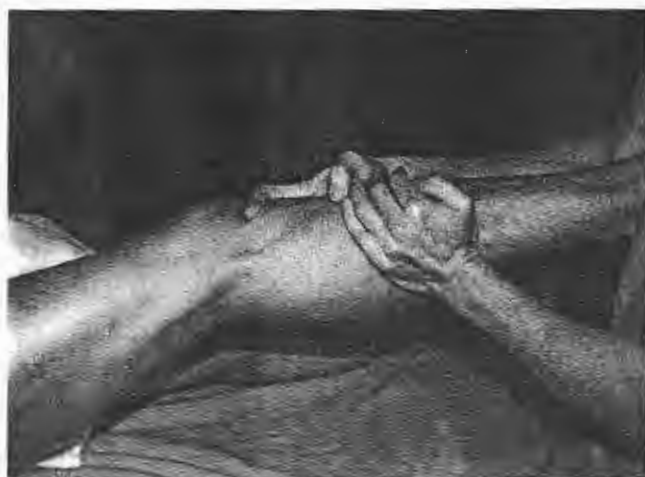**FIG 15.97.** Acute anterior cruciate ligament injury caused this tense hemarthrosis from a mop end tear of this left anterior cruciate ligament. Note the normal patellar contour on the right and absence of patellar definition from the tense hemarthrosis.



**FIG. 15.98.** Lachman test is performed with the knee at 30 degrees flexion, stabilizing the femur pulling forward on the tibia as the leg rests comfortably on a leg or pillow.

The choice of graft depends on availability, surgeon, and patient preference. Graft choices include the patellar tendon, hamstrings tendon, and allograft (57a,64,123,141, 188,245). Potential complications do exist from each procedure including graft failure, and are discussed in detail with the patient and family (188). Females and males do equally well following ACL reconstruction with bone-central third patellar tendon-bone (17,190). In the ACL deficient knee with severe varus alignment, combined or staged high tibial osteotomy may be necessary (187). Prosthetic ligaments have been tried but results have not been acceptable (129).

The typical tear pattern of the ACL is complete and midsubstance. A mop end tear (arrow) is seen superiorly



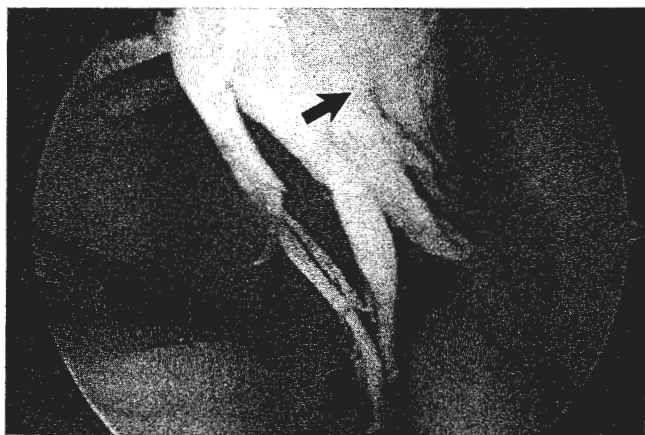**FIG. 15.99.** Pivot shift test is shown in exam under anesthesia at the time of subluxation of the lateral tibial plateau anteriorly in this dislocation test going from flexion to extension. Anatomically, the IT band and hamstring spasticity in the acutely injured knee make this test more difficult to obtain and reproduce.

with the scope looking at the posterior horn of the medial meniscus (Fig. 15.100). In a chronic ACL tear, there is often associated meniscal injury (20,38,220) and articular surface injury. In the chronic ACL injury, one may see an empty notch sign, meaning that no ACL is present in the intercondylar notch (Fig. 15.101A). After tearing away from its origin, the ACL may scar down to the PCL but not back to the posterior femur. A meniscal tear can be repaired if it is in the vascular or red-white region in the peripheral third. A displaced bucket handle tear of the lateral meniscus is shown (see Fig. 15.101B). Sutures are being inserted in a modified inside-out technique to repair a peripheral tear of the lateral meniscus (see Figs. 15.101C and 15.101D). A bone-central third patellar tendon-bone ACL reconstruction is shown being inserted into the femur where a hole has been reamed (see Fig. 15.101E) and then the finished graft filling the notch (see Fig. 15.101F) with an interference screw in the femoral hole (see Fig. 15.101G) is shown.

The natural history of unreconstructed ACL injuries is such that there is progressive arthrosis, particularly in the lateral compartment in certain patients. This patient underwent partial lateral meniscectomy of his right knee in high school and elected not to have his knee reconstructed. Five years after his injury in his mid-20s, the lateral compartment narrowing is seen compared to his opposite normal side. Standing 30 degrees flexed PA views show narrowed lateral compartment (Fig. 15.102).

### Rehabilitation of the Anterior Cruciate Ligament Reconstruction

Accelerated ACL rehabilitation programs have been well documented (54,111,122,157,256) as have injury



**FIG. 15.100.** The usual tear pattern for the anterior cruciate ligament is a mop-end complete failure as shown here. The scope is directed posteriorly in the posterior compartment at the posterior horn of the medial meniscus and the mop end tear is superior (arrow).

prevention programs in skiing (160,216), basketball (87,119,120), and soccer (35).

There are two tenets upon which ACL rehabilitation is based: (1) the healing time of the graft and (2) reaching established performance goals.

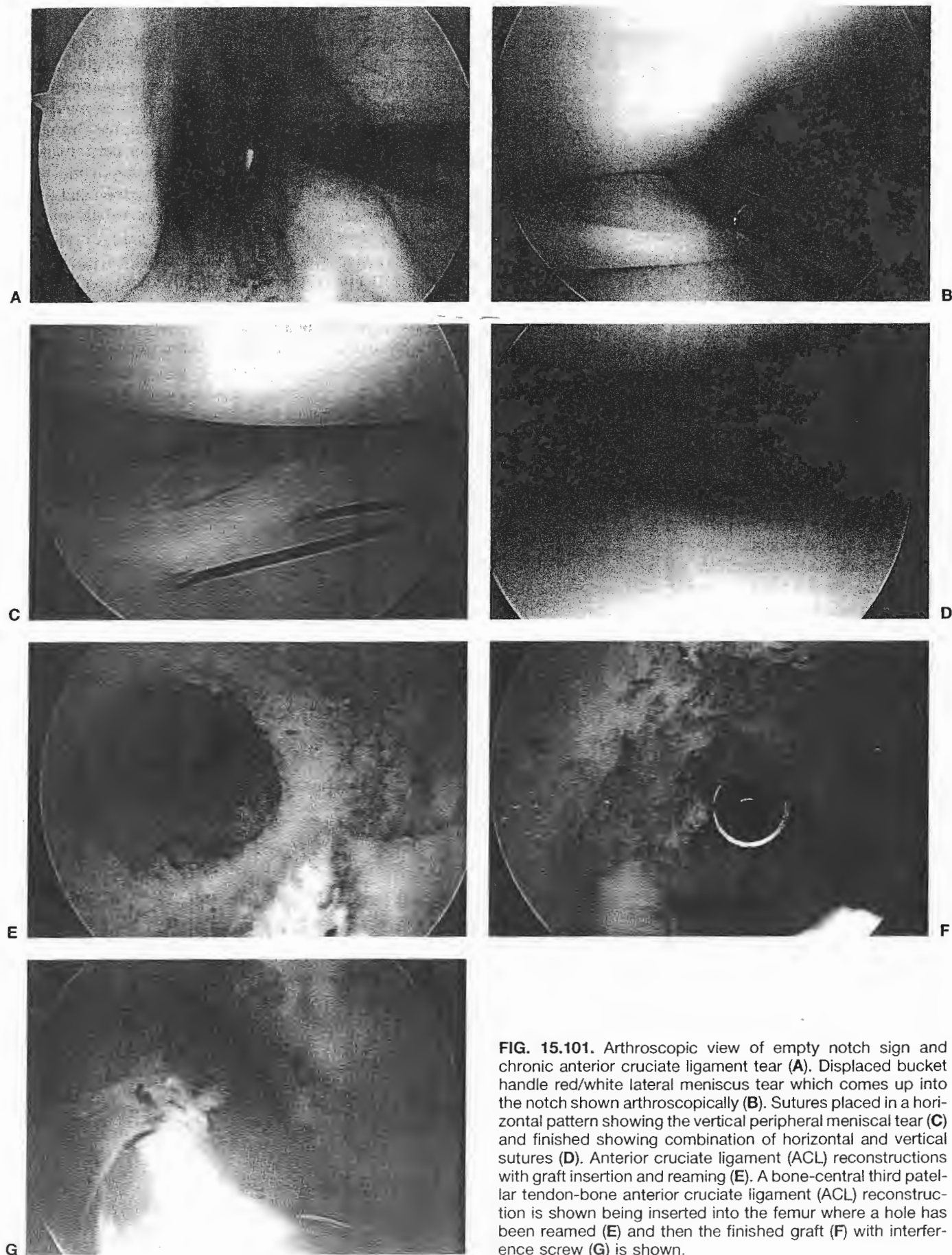
Decisions about progression of rehabilitation rest mainly on these tenets. Other factors taken into account are pain, swelling, and increased laxity. Controlled stress acts as a physical stimulus to the formation and organization of collagen during the healing phase. Uncontrolled stress could lead to a strain and permanent mechanical deformation, or laxity, in the healing ligament.

The first postoperative 7 to 10 days comprise phase I. This phase includes attaining 90 degrees of flexion and having an independent straight leg raise with no extensor lag. Patella mobilizations are initiated to limit iatrogenic scarring in the patella tendon and bursae. Full passive range of the extension motion is critical in the early phase to ensure that the graft will sit fully in the intercondylar notch. Otherwise, notch stenosis will prevent the graft from seating properly and scar tissue will fill the notch. Pushing terminal extension after scar tissue has developed may stretch out the graft. The goal for extension is for the involved side to equal the uninvolved side or to be at least 0 degrees.

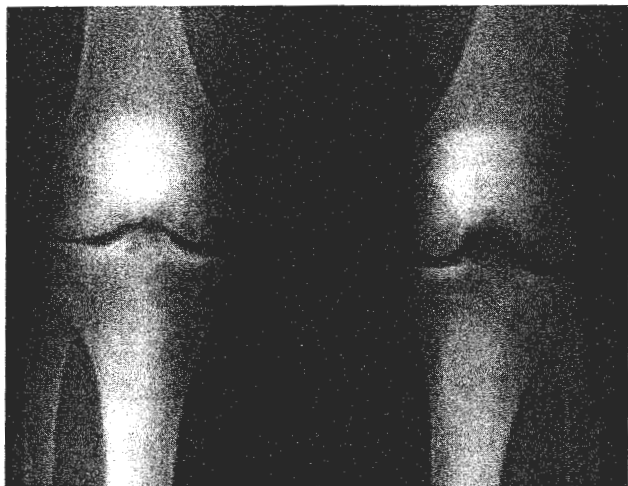Weight bearing is increased until full weight bearing is achieved by one week postoperatively, depending on swelling and pain. The program includes full weight-bearing mini-squat exercises. Flexion range of motion activities should gradually address attaining 95 to 100 degrees of flexion by the end of phase I. Wall slides can gradually assist in increasing knee range of motion. Isometric quadriceps and hamstring setting exercises and resistive hamstring exercise can be performed throughout a comfortable range of motion and in high repetitions. Straight leg raise exercises are done in the abduction, adduction, and extension motions. The athlete maintains a stretching program for the hamstring, quadriceps, and gastrocnemius. Prone hangs help achieve terminal passive extension if the patient is having trouble with end range.

Phase II begins at about 2 weeks. The emphasis here is to resume a normal gait and to start increasing lower extremity strength. Exercises focus on strength and neuromuscular control of the lower extremity and are designed to be very functional. Knee extensions are avoided because of the anterior shear of the tibia on the femur, particularly in the terminal 30 degrees of extension. Phase II exercises are added on to Phase I exercises. Straight leg raise is added in the flexion motion. Calf raises are done with both a straight knee and in a seated, flexed knee position. Partial range of motion box lunges are limited to a comfortable range of motion. Proprioceptive exercises and balance training are begun in a weight-bearing as tolerated fashion. The degree of challenge with these exercises starts out relatively small and gradually increases as strength and ability allow. If a pool is avail-





**FIG. 15.101.** Arthroscopic view of empty notch sign and chronic anterior cruciate ligament tear (A). Displaced bucket handle red/white lateral meniscus tear which comes up into the notch shown arthroscopically (B). Sutures placed in a horizontal pattern showing the vertical peripheral meniscal tear (C) and finished showing combination of horizontal and vertical sutures (D). Anterior cruciate ligament (ACL) reconstructions with graft insertion and reaming (E). A bone-central third patellar tendon-bone anterior cruciate ligament (ACL) reconstruction is shown being inserted into the femur where a hole has been reamed (E) and then the finished graft (F) with interference screw (G) is shown.



**FIG. 15.102.** Standing radiographs show degenerative joint disease of the lateral compartment and increased valgus in this patient who tore his anterior cruciate ligament in high school. Radiographs were obtained eight years later. He underwent partial lateral meniscectomy in high school and elected not to have his knee reconstructed.


able, walking and straight flutter kicking can begin. The Nordic Track and stair stepper are helpful as range of motion can be limited to a comfortable arc while still addressing whole lower kinetic chain function. Utilizing the bicycle to help maintain an increased range of motion and decreased stiffness and swelling will help in the athlete's progression. Criteria to advance to phase III are the ability to perform a 6-inch forward step-up, 0 degrees extension to 120 degrees flexion, and a normal gait.

Phase III lasts approximately 6 to 8 weeks. The emphasis at this stage is on progressive strengthening and neuromuscular reeducation exercises by repetition and time. The number and variety of closed chain exercises are increased as the patient tolerates. The graft is at its weakest point structurally at 8 to 10 weeks after surgery. Therefore, caution must be used in advancing the rehabilitation program only when the athlete demonstrates the appropriate strength and motor control to handle it. Goals for graduation from phase III include: bilateral quarter squat with 30% body weight, ten single leg quarter squats with good balance, controlled lateral step-up to a 6-inch height, single leg standing for 10 seconds with eyes closed, minimal swelling, and maintaining full passive knee extension.

Phase IV is a progression of phase III activities and leads up to testing the athlete's functional status. Emphasis is on easy plyometrics, control of jumping and soft landing as well as preparation for running. Depending on the patient's functional level, a functional assessment test is given during phase IV. This can be given anywhere from week 13 through week 16. The importance of functional testing is twofold: (1) to check the athlete's ability to initiate and control forces, and (2) obtain objective data regarding functional activities.

Functional tests are scored on two levels. Objective measures are taken for absolute values of weight lifted and centimeters jumped. More importantly, an observation of the activity is done to determine the neuromuscular control during landing activities, directional changes, and stopping. Points are assessed for poor performance in regards to quality of movement. An isokinetic test may be performed at 180 degrees per second and 300 degrees per second at 14 to 16 weeks to determine strength comparison of the involved to uninvolved leg. Once the athlete can perform 15 independent single leg squats, full bilateral squats with 50% body weight on each leg, and control the landing on jumps up to 12, they are ready for phase V.

The basic functional assessment performed in our clinic includes a balance assessment, a single leg squat at 45 degrees of knee flexion, a 1 rep maximum leg press from 60 degrees flexion to 0 degrees extension, and lastly, controlled landings up to both a 6-inch height and a 12-inch height. Three variations are tested for each height: the athlete starts with equal weight on both lower extremities, jumps up and lands on both feet; the athlete starts on both lower extremities, jumps up, and lands on the



**FIG. 15.103.** Anterior cruciate ligament (ACL) derotational brace. Brace is used for anterior cruciate ligament (ACL) deficient and reconstructed athletes working primarily to decrease rotational instability, as well as anterior translation of the tibia on the femur.



uninvolved foot; the athlete starts on the involved foot, jumps up, and lands on the involved foot. After an assessment is made about his or her abilities with these four tests, the clinician can then more accurately assess the ability to perform advanced levels of exercise (143,206,255).

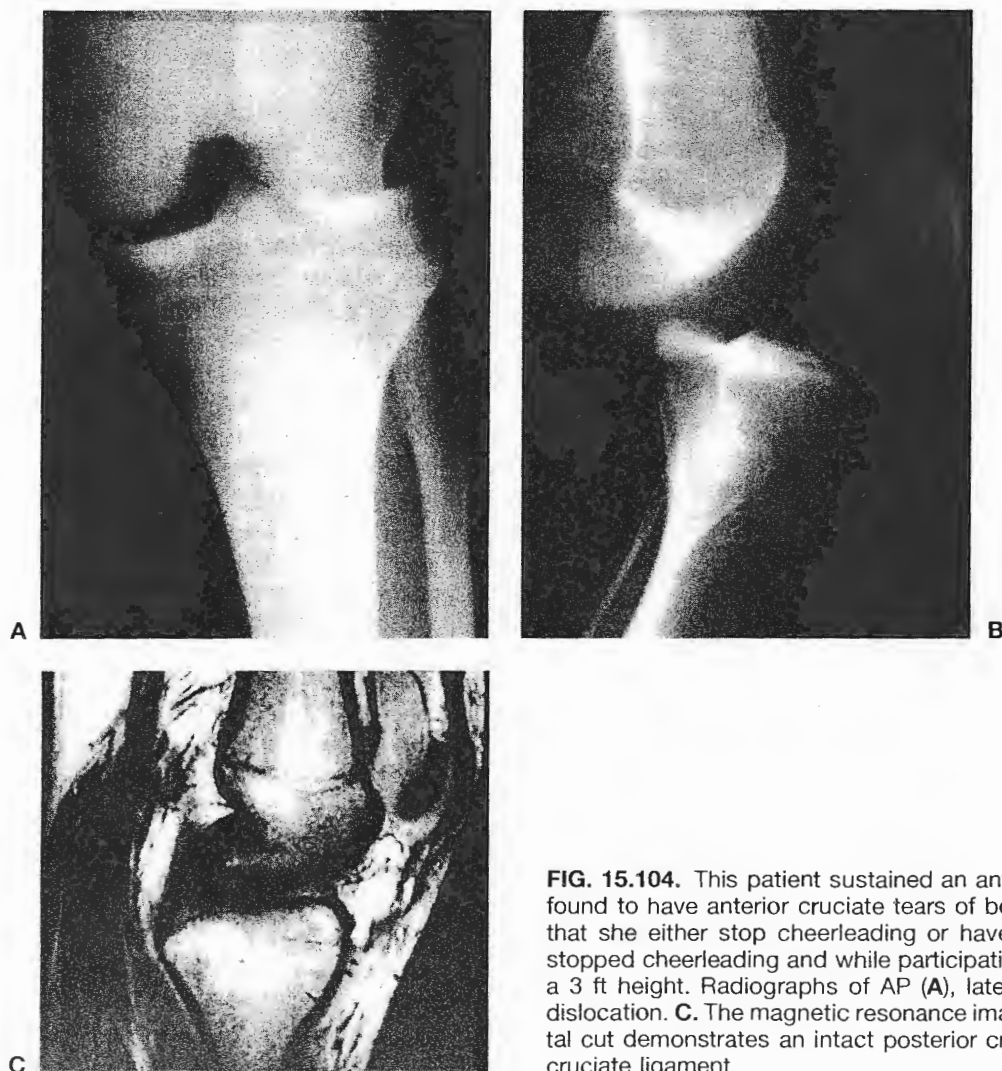
During phase V, the athlete's program is advanced in both the variety and difficulty of exercises through the four weeks following their achievement of a score on passing the basic functional assessment. Exercise incorporates lateral and turning movements with gradual increase to sport activities and forces. An advanced functional assessment is then given that includes a vertical jump test, a single leg long jump, a single leg triple jump, a single leg timed agility test over a 6-meter distance, a lateral shuffle test performed over a 5-meter distance, sports specific tests for stop, start, and cutting, and a 1 rep maximum leg press (143,206,255).

Running, agility training, and plyometric impact activity are progressed throughout phase V as the results of

the functional tests dictate. Independent half speed running, both forward and backward, independent lateral hops, controlled landing down from a 12-inch height, control of rotational jumps and landings, and control of single leg landings during a 6-inch jump up to a mat are the milestones for passing phase V.

Phase VI is the final phase and focuses on a controlled return to actual sports activities at full speed. As the athlete tolerates these increases, plyometrics are increased and cutting motions are performed on the command of the therapist or athletic trainer. An isokinetic retest can be performed with the goal being 80% quadriceps and 100% hamstring strength of the involved side to the uninvolved side (254). Return to full activities is allowed after the athlete passes an advanced functional assessment, done at 4 to 6 months postoperatively.

While bracing following ACL reconstruction remains controversial, the risks and benefits of using the brace must be discussed. There still remain concerns regarding the specific effects of bracing on neuromuscular function

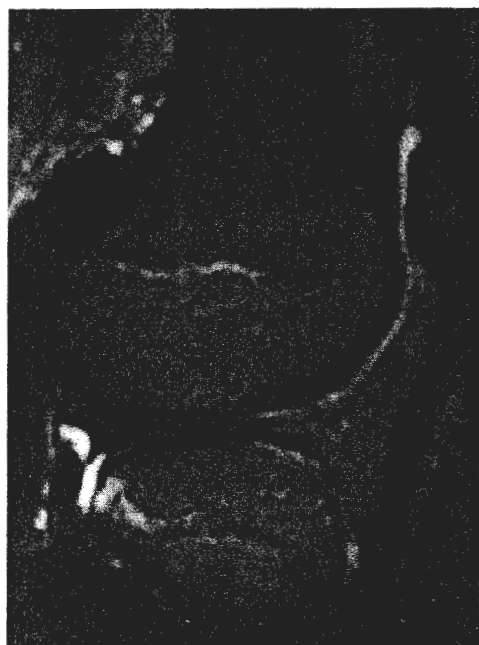

**FIG. 15.104.** This patient sustained an anterior knee dislocation. She was found to have anterior cruciate tears of both knees and it was suggested that she either stop cheerleading or have her knees reconstructed. She stopped cheerleading and while participating in a school play jumped from a 3 ft height. Radiographs of AP (**A**), lateral view (**B**) show anterior knee dislocation. **C.** The magnetic resonance imaging (MRI) scan shown on sagittal cut demonstrates an intact posterior cruciate ligament, absent anterior cruciate ligament.

(72,171,259,261,262) (Fig. 15.103). If an athlete is returning to a high-risk, highly competitive collegiate or high school sport, bracing is usually done the first year from the time of reconstruction. The most important brace is internal, musculoligamentous, and neurologic contribution. Restoration of proprioception and function are key after ACL reconstruction (18).

### Anterior Knee Dislocation

When the tibia anteriorly moves from under the femur, an anterior dislocation can occur and is often associated with multiple ligament tears. In noncontact mechanisms, these injuries usually are self-reduced in the active individual. In a contact injury or unconscious patient, reduction is necessary. This patient with chronic bilateral ACL tears decided to stop cheerleading and did not want a reconstruction. She jumped from a 2-foot height during a play and sustained an anterior knee dislocation shown in radiographs of AP (Fig. 15.104A) and lateral view (see Fig. 15.104B). The MRI scan showed a complete ACL tear but an intact PCL (see Fig. 15.104C). After her dislocation, she developed a deep vein thrombosis. Assessment of vascularity must be done in severe knee injuries to assess arterial or venous injury. After a 4-month course of anticoagulant therapy, she underwent ACL reconstruction.



**FIG. 15.105.** MRI scan showing location of the bone bruise following anterior cruciate ligament (ACL) tear which is mid-third lateral femoral condyle and posterior third lateral tibial plateau in the skeletally immature athlete. Consider the status of the articular cartilage in between with bone bruises documented by MR like this.

Bone bruises are easily seen on MRI and are located on the posterior aspect of the lateral tibial plateau and the anterior aspect of the femur that can be correlated well with anterior knee dislocation (see Fig. 15.104B). The bone bruise location is shown on sagittal MRI (Fig. 15.105). The importance of bone bruises is unknown. A temporary anterior knee dislocation occurs when the ACL is torn. If one thinks about the contact pressures between these locations of the tibia and femur, the articular surface must have significant shear and compressive forces.

### POSTERIOR CRUCIATE LIGAMENT (PCL) INSTABILITY

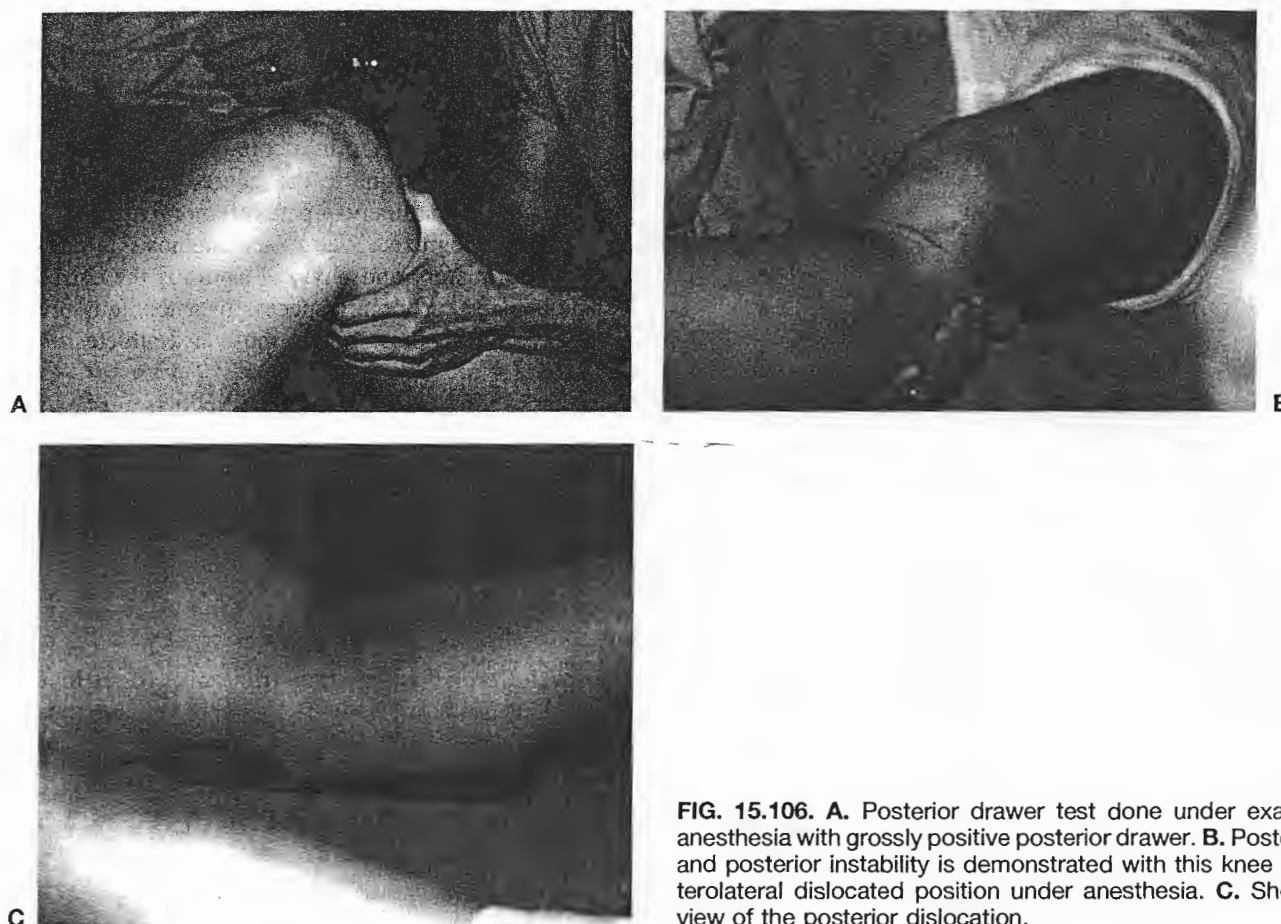Classic mechanism of a PCL injury is a motor vehicle accident with the tibial tubercle hitting the dashboard providing a posterior force. In athletics, when someone falls, the foot classically is in a plantar flexed position so that the force of the fall is on the tibial tubercle. With the foot dorsiflexed, the blow would be to the patella and a patellar contusion or fracture would ensue (40). In the sport of taekwon do, contact mechanisms with the opponent's foot can cause PCL injuries.

The clinical exam should include observation of any ecchymosis or abrasions on the tibial tubercle. The posterior drawer is done pushing the tibia posteriorly in neutral, internal, and external tibia rotation. The quads must be relaxed. With the knee at 90 degrees, the test is performed in neutral and then compared to the opposite side. A drop-back sign occurs when the tibial plateau is in a more posterior position relative to the femur.

This offensive lineman sustained a direct blow to the anterior tibial tubercle. His exam under anesthesia shows 4+ posterior drawer (Fig. 15.106A) with a posterolateral corner injury (see Fig. 15.106B). The injured capsule should be repaired acutely. His knee is also shown posteriorly dislocated (Fig. 15.106C). Vascular work-up was negative for deep venous thrombosis (DVT) or popliteal artery injury. Identification of a posterolateral injury is very important, as acutely, the posterolateral component should be addressed with the repair or reconstruction. Use of intraarticular grafts placed in an anatomic correct position and restoration of two bundles on the femur are done.

### Rehabilitation of the Posterior Cruciate Ligament Reconstruction

Rehabilitation of the posterior cruciate ligament reconstruction presents many of the same problems as with rehabilitation of the ACL reconstruction. Reducing swelling, protecting the graft, and restoring normal strength and motor control are vital. Limitations of range of motion should be outlined by the surgeon. Electrical stimulation is used for muscle contraction of the quadriceps and for



**FIG. 15.106.** A. Posterior drawer test done under exam under anesthesia with grossly positive posterior drawer. B. Posterolateral and posterior instability is demonstrated with this knee in a posterolateral dislocated position under anesthesia. C. Shows side view of the posterior dislocation.

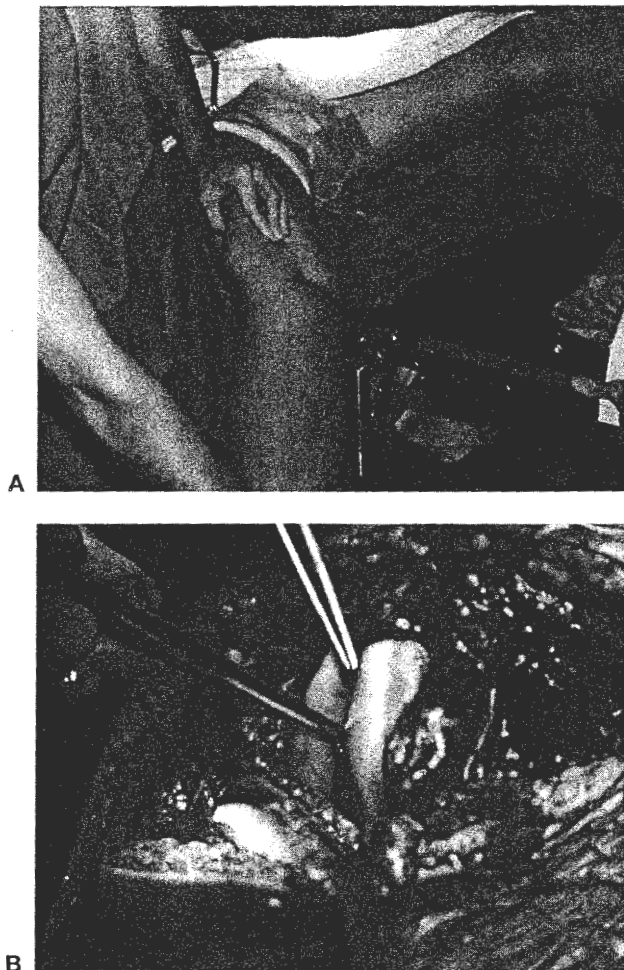
decreasing inflammation in the knee. Ice and elevation are used frequently throughout the day, allowing enough time in between applications for the skin to resume its normal temperature and color. Exercises initiated on post-operative day 1 include ankle pumps with the leg elevated, quadriceps setting, and straight leg raises. Throughout the first week, multiple-angle isometrics, patellar mobilizations, and toe raises are added with the knee in full extension. Throughout the second week, week 1 exercises are continued, knee extension exercises are added from 0 to 60 degrees, proprioceptive training is initiated as tolerated and well-leg exercises are begun on the bicycle. Exercises are increased in the number of sets and repetitions all the way through to week 4. The addition of mini-squats, stationary bicycling, pool exercises, box lunges, and up to a 4-inch forward step-up all occur as the patient can tolerate and adequately perform these.

By week 7, passive range of motion should be approximately 120 to 125 degrees of flexion and 0 degrees of extension. There should be no changes in the KT-1000 arthrometer testing through this point in time. Submaximal hamstring isometrics can progress to short arc hamstring curls with minimal to no weight. A variety of closed chain exercises can be added and progressed all the way through to week 12. Pool exercises can be advanced to

light running. At approximately 3 to 4 months, pool running can advance to land running. Also, from the 3 to 4 months, isokinetic high speed can be initiated in an arc of motion from 40 degrees of flexion to 100 degrees of flexion. A basic functional test is performed in the 3.5- to 4-month time period prior to a formal running program being initiated. The functional test is described in detail under the rehabilitation of the ACL reconstruction section. Return to activity occurs at approximately 5 to 6 months. All the rehabilitation exercises during this phase are geared toward sports-specific activities, agility, balance, and plyometrics. Return to sport typically happens after 6 months postoperatively, once the athlete passes an advanced functional test.

#### ACL/MCL/PCL KNEE DISLOCATION

A knee dislocation requires hospitalization, radiographs, vascular assessment, and observation following reduction. This injury is potentially limb threatening. Exam under anesthesia shows gross 4+ opening on abduction stress testing at 0 and 30 degrees (Fig. 15.107A). The defect in the skin seen below the examiner's hand is the skin tissue that is entering the joint, since there is a



**FIG. 15.107.** Exam under anesthesia shows gross 4+ opening on abduction stress testing at 0 and 30 degrees (A). Reconstruction—open procedure (B) Exam showing instability to valgus stress testing at 0 and 30 degrees flexion, anterior posterior drawer, were grossly positive 4+ (A). The open shot shows the incision only being made (B).

complete tear of all intraarticular structures. This patient essentially had a knee dislocation with a laterally dislocated patella on the field. He had a complete tear of the ACL, PCL, and severe deep capsular injury with complete tears of the meniscomfemoral and meniscotibial ligaments (see Fig. 15.107B). The meniscus is seen between the femur and tibia. Pickups are in the torn ACL that is mop end and above toward the PCL avulsion off of the femur. Although unusual, a knee dislocation with this severe medial instability will require a more open approach rather than the now more common arthroscopically aided approach.

## CONCLUSIONS

Knowledge of knee anatomy is key in understanding diagnosis and treatment of knee injuries. Understanding

basic anatomy allows development of a language that incorporates anatomy, mechanism of injury, and instability patterns. The healthcare providers can formulate the plan for the athlete—treatment, surgery, and rehabilitation. We must communicate in a common language.

Patterns of injury unique to the injured athlete's age, sport, and knee compartment—patellofemoral, medial, or lateral can be recognized. The exact diagnosis is made on the basis of history and physical exam. If the correct diagnosis is made early on, a successful outcome is predictably excellent in these highly motivated athletes. Be thorough and specific in the diagnosis.

Communication among health care providers must exist on a level to ensure the highest-quality care and treatment. Prospective outcome studies must be done. Standardized accepted knee-rating scales must be developed and revised.

## ACKNOWLEDGMENTS

Thanks to Carolyn Large, transcriptionist; Rick Hood, photographer; Tom Adler, Ph.D., computer expert; and Sue Stanley, A.T.C., manuscript reviewer.

## REFERENCES

1. Aglietti P, Insall JN, Walker PS. A new patellar prosthesis. *Clin Ortho* 1975;107:175–187.
2. Aglietti P, Insall J, Cerulli G. Patellar pain and incongruence. I. Measures of incongruence. *Clin Ortho* 1983;176:217–224.
3. American Medical Association. Standard Nomenclature of Athletic Injuries. Chicago: American Medical Association, 1966.
4. American Academy of Orthopaedic Surgeons, Dept. of Scientific and Research Affairs. Draft: knee pain—phase I, II; knee injury—phase I. Rosemont, IL, 1996.
5. Anderson AF, Lipscomb AB. Clinical diagnosis of meniscal tears. Description of a new manipulative test. *Am J Sports Med* 1986;14:291–293.
6. Anderson AF, Lipscomb AB, Liudahl KJ, Adlstone RB. Analysis of the intercondylar notch by computed tomography. *Am J Sports Med* 1987;15(6):547–552.
7. Anderson AF, Snyder RB, Lipscomb AB. Evaluation of knee ligament rating systems. *Am J Knee Surg* 1993;6:67–73.
8. Andrews JR, Axe MJ. The classification of knee ligament instability. *Orthop Clin North Am* 1985;16:69.
9. Andrews JR, Timmerman LA. *Diagnostic and operative arthroscopy*. Philadelphia: WB Saunders, 1997.
10. Apley G. The diagnosis of meniscus injuries. *J Bone Joint Surg* 1947;29:78–84.
11. Arendt E, Dick R. Knee injury patterns among men and women in collegiate basketball and soccer: NCAA data and review of literature. *Am J Sports Med* 1995;23(6):694–701.
12. Arnoczky SP, Warren RF. Microvasculature of the human meniscus. *Am J Sports Med* 1982;10:90–95.
13. Arnoczky SP, Cuzzell JZ, McDevitt CA, Torzilli PA, Warren RF, Kristinicz TI. Meniscal replacement using a cryopreserved allograft—an experimental study in the dog. *Trans Orthop Res Soc* 1984;9:220.
14. Baker BE. The effect of bracing on the collateral ligaments of the knee. *Clin Sports Med* 1990;9(4):843–851.
15. Baker BE. Prevention of ligament injuries to the knee. *Exerc Sport Sci Rev* 1990;18:291–305.
16. Baker CL. *The Hughston Clinic sports medicine book*. Philadelphia: Williams & Wilkins, 1995.

17. Barber-Westin SD, Noyes FR, Andrews M. A rigorous comparison of results and complications between the sexes of results and complications after anterior cruciate ligament reconstruction. *Am J Sports Med* 1997;25(4):514-526.
18. Barrett DS. Proprioception and function after anterior cruciate reconstruction. *J Bone Joint Surg* 1991;73B:833-837.
19. Baumgartl F. *Das Kniegelenk*. Berlin: Springer-Verlag, 1944.
20. Bellabarba C, Bush-Joseph CA, Bach BR Jr. Patterns of meniscal injury in the anterior cruciate-deficient knee: a review of the literature. *Am J Orthop* 1997;26(1):18-23.
21. Bentley G, Dowd G. Current concepts of etiology and treatment of chondromalacia patellae. *Clin Orthop* 1984;189:209-228.
22. Berg EE, Mason SL, Lucas MJ. Patellar height ratios: a comparison of four measurement methods. *Am J Sports Med* 1996;24(2):218-221.
23. Beynon BD, Johnson RJ. Relevant Biomechanics. In: DeLee JC, Drez D, eds. *Orthopaedic sports medicine: principles and practice*, vol. 2. Philadelphia: WB Saunders, 1994:1113-1133.
24. Black JE, Alten SR. How I manage infrapatellar tendinitis. *Phys Sportsmed* 1984;12:86-92.
25. Blazina ME, Kerlan RK, Jobe FW, Carter VS, Carlson GJ. Jumpers knee. *Orthop Clin North Am* 1973;4:665-678.
26. Boden BP, Garrett WE, Jr. Mechanisms of injuries to the anterior cruciate ligament. [Abstract] *Med Sci Sports Exerc Suppl* May, 1996;28(5):S26.
27. Bomberg BC, McGinty JB. Acute hemarthrosis of the knee: indications for diagnostic arthroscopy. *Arthroscopy* 1990;6(3):221-225.
28. Boring TH, O'Donoghue DH. Acute patellar dislocation: results of immediate surgical repair. *Clin Orthop* 1978;136:182.
29. Brantigan OC, Voshell AF. The tibial collateral ligament, its function, its bursae, and its relation to the medial meniscus. *J Bone Joint Surg* 1943;25A:121-131.
30. Brittberg M, Lindahl A, Nilsson A, et al. Treatment of deep cartilage defects in the knee with autologous chondrocyte transplantation. *N Engl J Med* 1994;331:889-895.
31. Buess-Watson E, Exner GU, Illi OE. Fractures about the knee: growth disturbances and problems of stability at long-term follow-up. *Eur J Pediatr Surg* 1994;4(4):218-224.
32. Buff HU, Jones LC, Hungerford DS. Experimental determination of forces transmitted through the patellofemoral joint. *J Biomech* 1988;21(1):17-23.
33. Busch MT, DeHaven KE. Pitfalls of the lateral retinacular release. *Clin Sports Med* 1989;18:279-290.
34. Butler DL, Noyes FR, Grood ES. Ligamentous restraints to anterior-posterior drawer in the human knee. A biomechanical study. *J Bone Joint Surg* 1980;62A:259-270.
35. Carraffa A, Gerulli G, Proietti M. Preview of ACL injuries: a control study or proprioceptive training. *Knee surgery traumatology. Arthroscopy* 1996;4:19-21.
36. Carson WG, James SL, Larson RL, Singer KM, Winternitz WW. Patellofemoral disorders: physical and radiographic evaluation. Part I: physical examination. *Clin Orthop Related Res* 1984;185:165-177.
- 36a. Carson WG, James SL, Larson RL, Singer KM, Winternitz WW. Patellofemoral disorders: physical and radiographic evaluation. Part II: radiographic examination. *Clin Ortho Related Res* 1984;185:178-186.
37. Casscells SW. The torn meniscus, the torn anterior cruciate ligament, and their relationship to degenerative joint disease. *Arthroscopy* 1985;1(1):28-32.
38. Cerabona F, Sherman MF, Bonamo JR, Sklar J. Patterns of meniscal injury with acute anterior cruciate ligament tears. *Am J Sports Med* 1988;16(6):603-609.
39. Chrisman OD, Snook GA, Wilson TC. A long-term prospective study of the Hauser and Roux-Goldthwaite procedures for recurrent patellar dislocation. *Clin Orthop* 1979;144:27.
40. Clancy WG, Shelbourne KD, Zoellner GB, et al. Treatment of knee joint instability secondary to rupture of the posterior cruciate ligament: report of a new procedure. *J Bone Joint Surg* 1983;65A:310-322.
41. Collins HR. Epiphyseal injuries in athletes. *Cleve Clin Q* 1975;42:285.
42. Collins RK. Injury patterns in women's flag football. *Am J Sports Med* 1984;15(3):238-242.
43. Colosimo AJ, Ireland ML, Horn T, Stine R, Shapiro R. Isokinetic peak torque and knee joint laxity comparison in female basketball and volleyball college athletes. (Abstract) *Med Sci Sports Exer* 1991;23(4):S135.
44. Cone RO. Imaging sports-related injuries of the knee. In: DeLee JC, Drez D, eds. *Orthopaedic sports medicine: principles and practice*, vol. 2. Philadelphia: WB Saunders, 1994:1549-1601.
45. Cooper DE, Warren RF, Warner JJP. The posterior cruciate ligament and posterolateral structures of the knee: Anatomy, function, and patterns of injury. In: Tullios HS, ed. *Instructional course lectures*, vol. XL. Rosemont, IL: AAOS, 1991:249-270.
46. Cox JS. An evaluation of the Elmslie-Trillat procedure for management of the patellar dislocations and subluxations. *Am J Sports Med* 1976;4:72.
47. Cox JS, Lenz HW. Women midshipmen in sports. *Am J Sports Med* 1984;12:241-243.
48. Cox JS, Blanda JB. Peripatellar pathologies. In: DeLee JC, Drez D, eds. *Orthopaedic sports medicine: principles and practice*. Philadelphia: WB Saunders, 1994:1249-1260.
49. Crenshaw AH. *Campbell's operative orthopaedics*. St. Louis: Mosby-Year Book, 1992.
50. Corwin S, Stannish WD. *Tendinitis: its etiology and treatment*. Lexington, MA: DC Health, 1984.
51. Dainer RD, Barrack RL, Buckley SL, Alexander AH. Arthroscopic treatment of acute patellar dislocations. *Arthroscopy* 1988;4:267.
52. Daniel DM, Fritschy D. Anterior cruciate ligament injuries. In: DeLee JC, Drez D, eds. *Orthopaedic sports medicine: principles and practice*, vol. 2. Philadelphia: WB Saunders, 1994:1313-1361.
53. Daniel DM, Stone ML, Dobson BE, et al. Fate of the ACL-injured patient: a prospective outcome study. *Am J Sports Med* 1994;22(5):632-644.
54. De Carlo M, Klootwyk TE, Shelbourne KD. ACL surgery and accelerated rehabilitation: revisited. *J Sport Rehab* 1997;6(2):144-156.
55. DeHaven KE, Lintner DM. Athletic injuries: comparison by age sport, and gender. *Am J Sports Med* 1986;14(3):218-224.
56. DeLee JC, Farney WC. Incidence of injury in Texas high school football. *Am J Sports Med* 1992;20(5):575-580.
57. DeLee JC, Drez D, eds. *Orthopaedic sports medicine: principles and practice*, vol. 2. Philadelphia: WB Saunders, 1994.
- 57a. DeLee JC, Bergfeld JA, Drez D, Parker AW. The posterior cruciate ligament. In: DeLee JC, Drez D, eds. *Orthopaedic sports medicine: principles and practice*, vol. 2. Philadelphia: WB Saunders, 1994:1374-1400.
58. Dowd GSE, Bentley G. Radiographic assessment in patellar instability and chondromalacia patellae. *J Bone Joint Surg* 1986;68(2):297-300.
59. Drez D Jr. Symposium on knee braces. Am Acad Orthop Surg Annual Meeting, Las Vegas, January 1985.
60. Dye SF, Chew MH. The use of scintigraphy to detect increased osseous metabolic activity about the knee. *J Bone Joint Surg* 1993;(A) 75:1388.
61. Dye SF. The knee as a biologic transmission with an envelope of function: a theory. *Clin Orthop* 1996;Apr (325):10-18.
62. Echeverria TS, Bersani FA. Acute fracture simulating a symptomatic bipartite patella. *Am J Sports Med* 1980;8:48-50.
63. Fairbanks TJ. Knee joint changes after meniscectomy. *J Bone Joint Surg* 1948;30B:664-670.
64. Feagin JA. *The crucial ligaments*, 2nd ed. New York: Churchill Livingstone, 1994.
65. Feretti A, Ippolito E, Mariani P, Puddu G. Jumper's knee. *Am J Sports Med* 1983;11:58-62.
66. Flandry F, Hughston JC. Complications of extensor mechanism surgery for patellar malalignment. *Am J Orthop* 1995;24(7):534-543.
67. Flandry F. A classification of knee ligament instability. In: Baker CL, ed. *The Hughston Clinic sports medicine book*. Baltimore: Williams & Wilkins, 1995:481-493.
68. Fox JM, Del Pizzo W. *The patellofemoral joint*. New York: McGraw-Hill, 1993.
69. Fu FH, Stone DA, eds. *Sports injuries: mechanism, prevention, and treatment*, 2nd ed. Baltimore: Williams & Wilkins, 1994.
70. Fu FH, Baratz M. Meniscal injuries. In: DeLee JC, Drez D, eds.



- Orthopaedic sports medicine: principles and practice*, vol. 2. Philadelphia: WB Saunders, 1994:1146-1162.
71. Fulkerson JP. Anteromedialization of the tibial tuberosity for patellofemoral malalignment. *Clin Ortho* 1983;177:176-181.
  72. Fulkerson JP, Tennant R, Jaivin JS, Grunnet M. Histologic evidence of retinacular nerve injury associated with patellofemoral malalignment. *Clin Ortho* 1985;187:196.
  73. Fulkerson JP. Anteromedial tibial tubercle transfer without bone graft. *Am J Sports Med* 1990;18:490-497.
  74. Fulkerson JP, Shea K. Current concepts: disorders of patellar alignment. *J Bone Joint Surg* 1990;72A:1424-1429.
  75. Fulkerson JP, Kalenak A, Rosenberg T, Cox JS. Patellofemoral pain. In: *Instructional course lectures*, vol. XLI. Rosemont, IL: AAOS, 1992:57-71.
  76. Fulkerson JP, Buuck DA. Patellofemoral disorders: biomechanics, diagnosis, nonoperative treatment, and arthroscopy. In: McGinty JB, ed. *Operative arthroscopy*. Lippincott-Raven, 2nd ed. 1996:343-360.
  77. Fulkerson JP. *Disorders of the patellofemoral joint*, 3rd ed. Philadelphia: Williams & Wilkins, 1997.
  78. Galway R. Pivot-shift syndrome. *J Bone Joint Surg* 1972;54B:558.
  79. Garrick JG, Requa RK. Prophylactic knee bracing. *Am J Sports Med* 1987;15(5):471-476.
  80. Gelb HJ, Glasgow SG, Sapega AA, Torg RS. Magnetic resonance imaging of knee disorders: clinical value and cost-effectiveness in a sports medicine practice. *Am J Sports Med* 1996;24(1):99-103.
  81. Girgis FG, Marshall JL, Monajem ARS. The cruciate ligaments of the knee joint: anatomical, functional, and experimental analysis. *Clin Ortho Rel Res* 1975;Jan-Feb(105):216-231.
  82. Gomez E, DeLee JC, Farney WC. Incidence of injury in Texas girls' high school basketball. *Am J Sports Med* 1996;24(5):684-687.
  83. Gray J, Taunton JE, McKenzie DC, Clement DB, McConkey JP, Davidson RG. A survey of injuries to the anterior cruciate ligament of the knee in female basketball players. *Int J Sports Med* 1985;6:314-316.
  84. Green S, Clayton ML, Liedholt JD, et al. One-hundred point scale for assessment of knee disability, 1969. In: Smillie I, ed. *Diseases of the knee joint*. Edinburgh: Churchill Livingstone, 1974:28.
  85. Green, WT Jr. Painful bipartite patella: a report of three cases. *Clin Ortho Related Res* 1975;110:177-200.
  86. Greenleaf JE. The anatomy and biomechanics of the lateral aspect of the knee. *Operative Tech Sports Med* 1996;4(3):141-147.
  87. Griffiths ND, Vequist SW, Yearout KM, et al. Injury prevention of the anterior cruciate ligament. [Abstract] In: American Orthopaedic Society for Sports Medicine: meeting abstracts, symposia, and instructional courses, 15th annual meeting. June 19-22, 1989.
  88. Grood SS, Noyes FR, Butler DL, Suntay WJ. Ligamentous and capsular restraints preventing straight medial and lateral laxity in intact human cadaver knees. *J Bone Joint Surg* 1981;63-A:1257-1269.
  89. Grood ES, Noyes FR. Diagnosis of knee ligament injuries: biomechanical precepts. In: Feagin EJ, ed. *The crucial ligaments*. New York: Churchill Livingstone, 1988:245-260.
  90. Harner CD, Xerogeanes JW, Livesay GA, et al. The human posterior cruciate ligament complex: an interdisciplinary study. *Am J Sports Med* 1995;23(6):736-745.
  91. Harner MF, Berson L, Hosea TM, Leddy TP. Lower extremity injuries: females vs. males in the sport of basketball. [Abstract] The AOSSM 22nd Annual Meeting, Lake Buena Vista, FL, June 16-20, 1996.
  92. Hefti F, Muller W. Current state of evaluation of knee ligament lesions. The new IKDC knee evaluation form. *Orthopaed* 1993;22:351-362.
  93. Hewson GF Jr, Mendini RA, Wang JB. Prophylactic knee bracing in college football. *Am J Sports Med* 1986;14(4):262-266.
  94. Hollinshead WH. *Anatomy for surgeons*, vol. 3: the back and limbs. New York: Harper & Row, 1969.
  95. Hoppenfeld S. *Physical exam of the spine and extremities*. Norwalk, CT: Appleton-Century-Crofts, 1976:171-196.
  96. Hoppenfeld S, DeBoer P. *Surgical exposures in orthopaedics: the anatomic approach*. Philadelphia: JB Lippincott, 1984.
  97. Huberti HH, Hayes WC, Stone WL, Shibut GT. Force ratios in quadriceps tendon and ligamentum patella. *J Orthop Res* 1984;2(1):49-54.
  98. Hughston JC, Eilers AF. The role of the POL in repairs of acute MCL tears of the knee. *J Bone Joint Surg* 1973;55A:923-940.
  99. Hughston JC, Andrews JR, Cross MJ, Moschi A. Classification of knee ligament instabilities. Part I. The medial compartment and cruciate ligaments. *J Bone Joint Surg* 1976;58A:159-172, 173-179.
  100. Hughston JC, Norwood LA. The posterolateral drawer test and external rotational recurvatum test for posterolateral rotatory instability of the knee. *Clin Ortho* 1980;147:82-87.
  101. Hughston JC, Barrett GR. Acute anteromedial rotatory instability: long-term results of surgical repair. *J Bone Joint Surg* 1983;65-A(2):145-153.
  102. Hughston JC, Walsh WM, Puddu G. *Patellar subluxation and dislocation*. Philadelphia: WB Saunders, 1984.
  103. Hughston JC, Deese M. Medial subluxation of the patella as a complication of lateral retinacular release. *Am J Sports Med* 1988;16(4):383-388.
  104. Hughston JC. *Knee ligaments: injury and repair*. St. Louis: Mosby-Year Book, 1993.
  105. Hungerford DS, Barry M. Biomechanics of the patellofemoral joint. *Clin Ortho* 1979;144:9.
  106. Hunter W. On the structure and diseases of articulating cartilage. *Philos Trans R Soc Lond [Biol]* 1743;9:267.
  107. Hunter LY, Andrews JR, Clancy WG, Funk JF Jr. Common orthopaedic problems in female athletes. In: *Instructional course lectures*. Rosemont, IL: AAOS 1982;31:126-151.
  108. Huston LJ, Wojtyls EM. Neuromuscular performance characteristics in elite female athletes. *Am J Sports Med* 1996;24:427-436.
  109. Hutchinson MR, Ireland ML. Knee injuries in female athletes. *Sports Med* 1995;19(4):288-302.
  110. Hutchinson MR, Ireland ML. Patella dislocation: Recognizing the injury and its complications. *Phys Sportsmed* 1995;23(10):53-60.
  111. Hutchinson MR, Ireland ML. Special considerations: women. In: Hunter-Griffin LY, ed. *Rehabilitation of the injured knee*. Mosby-Year Book, 1995, 297-312.
  112. Indelicato PA. Non-operative treatment of complete tears of the medial collateral ligament of the knee. *J Bone Joint Surg* 1983;65A(3):323-329.
  113. Insall JN, Aglietti P, Tria AJ. Patellar pain and incongruence. II. Clinical application. *Clin Ortho* 1983;176:225-232.
  114. Insall JN. Anatomy of the knee. In: Insall JN, ed. *Surgery of the knee*. New York: Churchill Livingstone, 1984:1-20.
  115. Insall JN. Disorders of the patella. In: Insall JN, ed. *Surgery of the knee*. New York: Churchill Livingstone, 1984:191-260.
  116. Ireland ML, Wall C. Epidemiology and comparison of knee injuries in elite male and female United States basketball athletes. *Med Sci Sports Exerc* [Abstract] 1990;14:S82.
  117. Ireland ML. Special concerns of the female athlete. In: Fu FH, Stone DA, eds. *Sports injuries: mechanism, prevention, and treatment*, 2nd ed. Baltimore: Williams & Wilkins, 1994:153-187.
  118. Ireland ML, Chang JL. Acute fracture bipartite patella: case report and literature review. *Med Science Sports Exerc* 1995;27(3):299-302.
  119. Ireland ML. Anterior cruciate ligament injuries in young female athletes. *Your patient and fitness* 1996;10(5):26-30.
  120. Ireland ML, Gaudette M, Crook S. ACL injuries in the female athlete. *J Sport Rehab* 1997;6:97-110.
  121. Ireland ML, Williams RI. Degenerative arthritis of the knee. In: Andrews JR, Timmerman LA, eds. *Diagnostic and operative arthroscopy*. Philadelphia: WB Saunders, 1997:325-345.
  122. Irrgang JJ, Harner CD. Recent advances in ACL rehabilitation: clinical factors that influence the program. *J Sport Rehab* 1997;6(2):111-124.
  123. Jackson DW. *The anterior cruciate ligament: current and future concepts*. New York: Raven Press, 1993.
  124. Jackson RW. The painful knee: Arthroscopy or MR imaging? *J Am Acad Orthop Surg* 1996;4(2):93-99.
  125. Jakob RP, Warner JP. Lateral and posterolateral rotatory instability of the knee. In: DeLee JC, Drez D, eds. *Orthopaedic sports medicine: principles and practice*, vol. 2. Philadelphia: WB Saunders, 1994:1275-1312.

126. Johnson LL. *Operative arthroscopy: principles and practice*. St. Louis: Mosby, 1986.
127. Jaureguito JW, Elliott JS, Lietner T, Dixon LB, Reider B. The effects of arthroscopic partial lateral meniscectomy in an otherwise normal knee: a retrospective review of functional, clinical, and radiographic results. *Arthroscopy* 1995;11(1):29-36.
128. Kannus P. Long term results of conservative treated medial collateral ligament injury of the knee joint. *Clin Orthop* 1988;226:103-112.
129. Karzel RP, Friedman MJ, Ferkel RD. Prosthetic ligament reconstruction of the knee. In: DeLee JC, Drez D, eds. *Orthopaedic sports medicine: principles and practice*, vol. 2. Philadelphia: WB Saunders, 1994, 1502-1527.
130. Kelly DW, Carter VS, Jobe FW, Kerlan RK. Patellar and quadriceps tendon ruptures: jumper's knee. *Am J Sports Med* 1984;12:375-380.
131. Kennedy JC, Fowler PJ. Medial and anterior instability of the knee: an anatomical and clinical study using stress machines. *J Bone Joint Surg* 1971;53A:1257-1270.
132. Kettlkamp D, Thompson C. Development of a knee scoring scale. *Clin Orthop* 1975;107:93-99.
133. Kolowich P, Paulos L, Rosenberg T, et al. Lateral release of the patella: indications and contraindications. *Am J Sports Med* 1990;18(4):359-365.
134. Kulund DN. *The injured athlete*. Philadelphia: JB Lippincott, 1982.
135. Kusayama T, Harner CD, Carlin GJ, Xerogeanes JW, Smith BA. Anatomical and biomechanical characteristics of human meniscofemoral ligaments. *Knee Surg Sports Traumatol Arthrosc* 1994;2(4):234-237.
136. LaPrade RF, Burnett QM. Femoral intercondylar notch stenosis and correlation to anterior cruciate ligament injuries: a prospective study. *Am J Sports Med* 1994;22(2):198-203.
137. LaPrade RF, Burnett QM II, Veenstra MA, Hodgman CG. The prevalence of abnormal magnetic resonance imaging findings in asymptomatic knees: with correlation of magnetic resonance imaging to arthroscopic findings in symptomatic knees . . . including commentary by Curl WW. *Am J Sports Med* 1994;22(6):739-745.
138. Larson R. Rating sheet for knee function, 1972. In: Smillie I, ed. *Diseases of the knee joint*. Edinburgh: Churchill Livingstone, 1974:29,30.
139. Larson RL, McMahon RO. The epiphyses in the childhood athlete. *JAMA* 1966;196:607.
140. Larson RL. Epiphyseal injuries in the adolescent athlete. *Orthop Clin North Am* 1973;4:439.
141. Larson RV, Friedman MJ. Anterior cruciate ligament: injuries and treatment. In: Pritchard DJ, ed. *Instructional course lectures*, vol. 45. Rosemont, IL: AAOS, 1996;235-243.
142. Laurin CA, Dussault R, Levesque HP. The tangential x-ray investigation of the patellofemoral joint: x-ray technique, diagnostic criteria and their interpretation. *Clin Orthop* 1979;144:16-26.
143. Lephart SM, Perrin DH, Fu FH, et al. Relationship between physical characteristics and functional capacity in the anterior cruciate ligament insufficient athlete. *JOSPT* 1992;16(4):174-181.
144. Levy IM, Torzilli PA, Warren RF. The effect of medial meniscectomy on anterior-posterior motion of the knee. *J Bone Joint Surg* 1982;64A:883-888.
145. Levy AS, Lohnes J, Sculley S, LeCroy M, Garrett W. Chondral delamination of the knee in soccer players. *Am J Sports Med* 1996;24(5):634-639.
146. Lieb FJ, Perry J. Quadriceps function: Anatomical and mechanical study using amputated limbs. *J Bone Joint Surg* 1968;50A:1535-1548.
147. Lieb FJ, Perry. Quadriceps function: an EMGic study under isometric conditions. *J Bone Joint Surg* 1971;53:749-758.
148. Linton RC, Indelicato PA. Medial ligament injuries. In: DeLee JC, Drez D, eds. *Orthopaedic sports medicine: principles and practice*, vol. 2. Philadelphia: WB Saunders, 1994:1261-1274.
149. Liu SH, Raad A-S, Lane J, Barber-Westin SD, Noyes FR. The estrogen-collagen interaction in the ACL: a potential explanation for female athletic injury. Presented AOSSM 22nd Annual Meeting, June 16-20, 1996, Lake Buena Vista, Florida.
150. Liu SH, Yu W, Hatch J, Panossian V, Finerman GAM. Estrogen affects the cellular metabolism of the female human anterior cruciate ligament: a potential explanation for female athletic injury. Book of abstracts & outlines, American Orthopaedic Society for Sports Medicine, 23rd Annual Meeting, Sun Valley, Idaho, June 22-25, 1997:805.
151. Lobenhoffer P, Tschern H. Fractures of the patella. In: Fu FH, Harner CD, Vince KG, eds. *Knee surgery*. Baltimore: Williams & Wilkins, 1994:1051-1057.
152. Losee RE, Johnson TR, Southwick WO. Anterior subluxation of the lateral tibial plateau. A diagnostic test and operative repair. *J Bone Joint Surg* 1978;60A:1015.
153. Lysholm J, Gillquist J. Evaluation of knee ligament surgery results with special emphasis on use of a scoring scale. *Am J Sports Med* 1982;10:150-154.
154. Lysholm J, Tegner Y, Gillquist J. Functional importance of different clinical findings in the unstable knee. *Acta Orthop Scan* 1984;55:471.
155. Malghem J, Maldague B. Depth insufficiency of the proximal trochlear groove on lateral radiographs of the knee: relation to patellar dislocation. *Radiology* 1989;170(2):507-510.
156. Malone TR, Hardaker WT, Garrett WE, et al. Relationship of gender to anterior cruciate ligament injuries in intercollegiate basketball participants. *J Sou Orth Ass* 1993;2(1):36-39.
157. Mangine RE, Kremchek. Evaluation-based protocol of the anterior cruciate ligament. *J Sport Rehab* 1997;6(2):157-181.
158. Maquet PGJ. Advancement of the tibial tuberosity. *Clin Orthop* 1976;115:225.
159. Mariani PP, Caruso I. An electromyographic investigation of subluxation of the patella. *J Bone Joint Surg* 1979;61B:169-171.
160. Marshall JL, Johnson RJ. Mechanisms of the most common ski injuries. *Phys Sportsmed* 1977;5(12):49-54.
161. Martinez S, Korobkin M, Fondren FB, Hedlund LW, and Goldner JL. Computed tomography of the normal patellofemoral joint. *Invest Radiol* 1983;18(3):249-253.
162. Matelic TM, Aronsson DD, Boyd DW Jr., LaMont RL. Acute hemarthrosis of the knee in children. *Am J Sports Med* 1995;23(6):668-671.
163. McCarroll JR, Shelbourne KD, Patel DV. Anterior cruciate ligament injuries in young athletes: Recommendations for treatment and rehabilitation. *Sports Med* 1995;20(2):117-127.
164. McCauley TR, Kier R, Lynch KJ, Jokl P. Chondromalacia patellae: diagnosis with MR imaging. *AJR* 1992;158(1):101-105.
165. McConnell J. The management of chondromalacia patella: a long term solution. *Aust J Physiother* 1986;2:215-223.
166. McGinty JB. *Operative arthroscopy*. Philadelphia: Lippincott-Raven, 1996.
167. McMaster PE. Tendon and muscle ruptures. Clinical and experimental studies on the causes of subcutaneous ruptures. *J Bone Joint Surg* 1933;15A:705-722.
168. McMurray TP. The semilunar cartilages. *Br J Surg* 1942;29:407-414.
169. Merchant AC, Mercer RL, Jacobsen RH, Cool CR. Roentgenographic analysis of patellofemoral congruence. *J Bone Joint Surg* 1974;56A:1391.
170. Merchant AC. Clinical classification of patellofemoral disorders. *Sports Med Arthroscopy Rev* 1994;2(3).
171. Millet CW, Drez DJ Jr. Principles of bracing for the anterior cruciate ligament-deficient knee. *Clin Sports Med* 1988;7(4):827-833.
172. Millet CW. Knee braces. In: DeLee JC, Drez D, eds. *Orthopaedic sports medicine: principles and practice*, vol. 2. Philadelphia: WB Saunders, 1994:1468-1474.
173. Miller GK. A prospective study comparing the accuracy of the clinical diagnosis of meniscus tear with magnetic resonance imaging and its effect on clinical outcome. *Arthroscopy* 1996;12(4):406-413.
174. Morgan CD, Kalman VR, Grawl DM. The anatomic origin of the posterior cruciate ligament: where is it? Reference landmarks for PCL reconstruction. *Arthroscopy* 1997;13(3):325-331.
175. Muller W. *The knee: form, function, and ligament reconstruction*. New York: Springer-Verlag, 1983.
176. National Collegiate Athletic Association. NCAA injury surveillance system. Overland Park, KS: NCAA, 1990-1996.

177. Neer CS II, Horwitz BS. Fractures of the epiphyseal plate. *Clin Orthop* 1965;41:24.
178. Nicholas JA. *The lower extremity and spine in sports medicine*, vol. 1. St. Louis: Mosby, 1986.
179. Noyes FR, Grood ES, Butler DS, et al. Clinical laxity tests and functional stability of the knee: biomechanical concepts. *Clin Orthop* 1980;146:84.
180. Noyes FR, Matthews DS, Moar PA, et al. The symptomatic anterior cruciate deficient knee. Part II: The results of rehabilitation, activity modification and counseling on functional disability. *J Bone Joint Surg* 1983;65A:163-174.
181. Noyes FR, Grood ES. Diagnosis of knee ligament injuries: clinical concepts. In: Feagin EJ, ed. *The crucial ligaments*. New York: Churchill Livingstone, 1988:261-285.
182. Noyes FR, Barber SD, Moar LA. A rationale for assessing sports activity levels and limitations in knee disorders. *Clin Orthop* 1989;246:238-249.
183. Noyes FR, Grood ES, Torzilli PA. Current concepts review: the definitions of terms for motion and position of the knee and injuries of the ligaments. *J Bone Joint Surg* 1989;71-A:(3)465-472.
184. Noyes FR. *The Noyes knee rating system*. Cincinnati: Cincinnati Sportsmedicine Research and Education Foundation, 1990.
185. Noyes FR, Stabler CL. A system for grading articular cartilage lesions at arthroscopy. *Am J Sports Med* 17(4):1989;505-513.
186. Noyes FR, Barber SD, Mangine RE. Abnormal lower limb symmetry determined by function hop tests after anterior cruciate ligament rupture. *Am J Sports Med* 1991;12:513-518.
187. Noyes RF, Simon R. The role of high tibial osteotomy in the anterior cruciate ligament-deficient knee with varus alignment. In: DeLee JC, Drez D, eds. *Orthopaedic sports medicine: principles and practice*, vol. 2. Philadelphia: WB Saunders, 1994:1401-1443.
188. Noyes FR, Barber-Westin SD. Reconstruction of the anterior cruciate ligament with human allograft: comparison of early and lateral results. *J Bone Joint Surg* 1996;78A(4):524-537.
189. Nyland JA, Shapiro R, Stine RL, Horn TS, Ireland ML. Relationship of fatigued run and rapid stop to ground reaction forces, lower extremity kinematics, and muscle activation. *JOSPT* 1994;20(3):132-137.
190. O'Brien SJ, Warren RF, Pavlov H, Panariello R, Wickiewicz TL. Reconstruction of the chronically insufficient anterior cruciate ligament with the central third of the patellar ligament. *J Bone Joint Surg* 1991;73-A(2):278-286.
191. O'Conner JJ, Shercliff T, Fitzpatrick D, et al. Geometry of the knee. In: Daniel DM, Akeson WH, O'Conner JJ, eds. *Knee ligaments: structure, function, injury and repair*. New York: Raven Press, 1990:163-199.
192. O'Donoghue DH. Reconstruction for medial instability of the knee, techniques and results in 60 cases. *J Bone Joint Surg* 1973;55A:941-955.
193. O'Donoghue DH. Treatment of injuries to the knee. In: O'Donoghue DH, ed. *Treatment of injuries to athletes*, 4th ed. Philadelphia: WB Saunders, 1987:470-471.
194. Ogden JA. *Skeletal injury in the child*, 2nd ed. Philadelphia: WB Saunders, 1990:808.
195. Outerbridge RE. The etiology of chondromalacia patellae. *J Bone Joint Surg* 1961;43B(4):752-757.
196. Palumbo PM. Dynamic Patella brace: a new orthosis in the management of patellofemoral disorders: a preliminary report. *Am J Sports Med* 1081;9:1.
197. Parker RD, Calabrese GJ. Anterior knee pain. In: Fu FH, Harner CD, Vince KG, eds. *Knee surgery*. Baltimore: Williams & Wilkins, 1994:929-951.
198. Peterson CA, Peterson HA. Analysis of the incidence of injuries to the epiphyseal growth plate. *J Trauma* 1972;12:275.
199. Phillips B. Anterior cruciate ligament injuries. In: Andrews JR, Timmerman LA, eds. *Diagnostic and operative arthroscopy*. Philadelphia: WB Saunders, 1997, 355-390.
200. Pick TP, Howden R, eds. *Gray's anatomy*. Philadelphia: Running Press, 1974.
201. Post W, Fulkerson J. Distal realignment of the patellofemoral joint. *Orthop Clin of NA* October, 1992;23(4).
202. Post W. Surgical decision making in patellofemoral pain and instability. *Operative Tech Sports Med* 1994;2(4):273-284.
203. Post WR, Fulkerson J. Knee pain diagrams: correlation with physical examination findings in patients with anterior knee pain. *Arthroscopy* 1994;10(6):618-623.
204. Rask BP, Micheli LJ. Knee ligament injuries and associated derangements in children and adolescents. In: Fu FH, Harner CD, Vince KG, eds. *Knee surgery*. Baltimore: Williams & Wilkins, 1994:365-381.
205. Reider B, D'Agata SD. Factors predisposing to knee injury. In: DeLee JC, Drez D, eds. *Orthopaedic sports medicine: principles and practice*, vol. 2. Philadelphia: WB Saunders, 1994:1134-1145.
206. Risberg MA, Ekland A. Assessment of functional tests after anterior cruciate ligament surgery. *JOSPT* 1994;19(4):212-217.
207. Reynolds L, Levin TA, Medeiros JM, Adler NS, Hallum A. EMG activity of the vastus medialis oblique and vastus lateralis muscles in their role of patellar alignment. *Am J Phys Med* 1983;62:61-70.
208. Rielly DJ, Martens M. Experimental analysis of the quadriceps force and patellofemoral joint reaction force for various activities. *Acta Orthop Scand* 1972;43:126-137.
209. Roberts TS, Terry GC. Complications of knee surgery. In: DeLee JC, Drez D, eds. *Orthopaedic sports medicine: principles and practice*, vol. 2. Philadelphia: WB Saunders, 1994, 1528-1548.
210. Rockwood CA Jr, Green DP, eds. *Fractures in adults*, vol. 2. Philadelphia: JB Lippincott, 1984.
211. Rose NE, Gold SM. A comparison of accuracy between clinical examination and magnetic resonance imaging in the diagnosis of meniscal and anterior cruciate ligament tears. *Arthroscopy* 1996;12(4):398-405.
212. Roux C. Recurrent dislocations of the patella: operative treatment. *Clin Orthop* 1979;144:4-8.
213. Rovere GD, Adar DM. Medial patellar shelf plica syndrome. Treatment by intrapical steroid injection. *Am J Sports Med* 1985;13:382-386.
214. Rovere GD, Haupt HA, Yates CS. Prophylactic knee bracing in college football. *Am J Sports Med* 1987;15(2):111-116.
215. Ryan JB. Prophylactic knee braces: the West Point experience. Book of abstracts and outlines, AOSM 23rd Annual Meeting, Sun Valley, Idaho, June 22-25, 1997:696-697.
216. Ryder SH, Johnson RJ, Beynon BD, Ettlinger CF. Prevention of ACL injuries. *J Sport Rehab* 1997;6(2):80-96.
217. Satterwhite YE. The anatomy and biomechanics of the medial structures of the knee. *Op Tech Sports Med* 1996;4(3):134-140.
218. Saltzman CL. Results of treatment of displaced patellar fractures by partial patellectomy. *J Bone Joint Surg* 1990;72A: 1279-1285.
219. Saupé H. Primäre Knochemark Seilerung der Kniescheibe. *Deutsche Z Chir* 1943;258:386.
220. Schmitz MA, Rouse LM Jr, DeHaven KE. The management of meniscal tears in the ACL-deficient knee. *Clin Sports Med* 1996;15(3):573-593.
221. Scott WN. *The knee*. St. Louis: Mosby, 1994.
222. Sebastianelli WJ, DeHaven KE. Chondral fractures and intra-articular osteochondroses. In: DeLee JC, Drez D, eds. *Orthopaedic sports medicine: principles and practice*, vol. 2. Philadelphia: WB Saunders, 1994:1444-1467.
223. Seebacher JR, Inglis AE, Marshall JL, Warren RF. The structure of the posterolateral aspect of the knee. *J Bone Joint Surg* 1982;64A(4):536-541.
224. Silbey MB, Fu FH. Knee injuries. In: Fu FH, Stone DA, eds. *Sports injuries: mechanisms, prevention, treatment*. Baltimore: Williams & Wilkins, 1994:249-276.
225. Sgaglione NA, Del Pizzo W, Fox JM, Friedman MJ. Critical analysis of knee ligament rating systems. *Am J Sports Med* 1995;23(6):660-667.
226. Shapiro ET, Richmond JC, Rockett SE, McGrath MM, Donaldson WR. The use of a generic, patient-based health assessment (SF-36) for evaluation of patients with anterior cruciate ligament injuries. *Am J Sports Med* 1996;24(2):196-200.
227. Shelbourne KD, Patel DV, McCarroll Jr. Management of anterior cruciate ligament injuries in skeletally immature adolescents. *Knee Surg Sports Traumatol Arthrosc* 1996;4(2):68-74.
228. Shelbourne KD, Davis TJ, Klootwyk TE. The relationship between intercondylar notch width of the femur and the incidence of ante-

- rior cruciate ligament tears. *Am J Sports Med* 1998;26(3):402-408.
229. Shoemaker SC, Markolf KL. The role of the meniscus in the A-P stability of the loaded anterior cruciate-deficient knee. *J Bone Joint Surg* 1986;68A:71-79.
  230. Shrive NG, O'Connor JJ, Goodfellow JW. Load bearing in the knee joint. *Clin Orthop* 1978;131:279-281.
  231. Sisk DT. Knee realignment and replacement in the recreational athlete. In: DeLee JC, Drez D, eds. *Orthopaedic sports medicine: principles and practice*, vol. 2. Philadelphia: WB Saunders, 1994: 1475-1501.
  232. Slocum DB, James SL, Larson RL, et al. Clinical test for anterolateral rotary instability of the knee. *Clin Orthop* 1976;118:63.
  233. Slocum DB, Larson RL. Rotatory instability of the knee. *J Bone Joint Surg* 1968;50A:211-225.
  234. Smillie IS. *Injuries of the knee joint*. 3rd ed. Baltimore: Williams & Wilkins, 1962.
  235. Smith PA. Physical examination of the knee. In: *The Hughston Clinic sports medicine book*. Baltimore: Williams & Wilkins, 1995:416-425.
  236. Souryal TO, Moore HA, Evans JP. Bilaterality in anterior cruciate ligament injuries: Associated intercondylar notch stenosis. *Am J Sports Med* 1980;8(3):449-454.
  237. Souryal TO, Freeman TR. Intercondylar notch size and anterior cruciate ligament injuries in athletes: a prospective study. *Am J Sports Med* 1993;21(4):535-539.
  238. Summer HM. Patellar chondropathy and apicitis, and muscle imbalances of the lower extremity in competitive sports. *Sports Med* 1988;5:386-394.
  239. Tapper EM, Hoover NW. Late results after meniscectomy. *J Bone Joint Surg* 1969;51A:517-526.
  240. Teitz CC, Hermanson EK, Kronmal RA, Diehr PH. Evaluation of the use of braces to prevent injury to the knee in collegiate football players. *J Bone Joint Surg* 1987;69(1):2-9.
  241. Tegner Y, Lysholm J. Rating systems in the evaluation of knee ligament injuries. *Clin Orthop* 1985;198:43-49.
  242. Terry GC, LaPrade RF. The biceps femoris muscle complex at the knee. Its anatomy and injury patterns associated with acute anterolateral rotatory instability. *Am J Sport Med* 1996;24(1):2-8.
  243. Terry GC, LaPrade RF. The posterolateral aspect of the knee. Anatomy and surgical approach. *Am J Sport Med* 1996;24(6):732-739.
  244. Vainionpää S, Laasonen E, Silvennoinen T. Acute dislocation of the patella: a prospective review of operative treatment. *Acta Orthopaedica Scand* 1986;57:331-333.
  245. Vangness CT Jr, Triffon MJ, Joyce MJ, Moore TM. Soft tissue for allograft reconstruction of the human knee: a survey of the American Association of Tissue Banks. *Am J Sports Med* 1996;24(5):705.
  246. Vaupel G, Dye S. Functional knee anatomy. In: Baker CL, ed. *The Hughston Clinic sports medicine book*. Baltimore: Williams & Wilkins, 1995:403-405.
  247. Veltri DM, Warren RF. Anatomy, biomechanics, and physical findings in posterolateral knee instability. *Clin Sports Med* 1994;13(3):599-614.
  248. Walker P, Erkman M. The role of the menisci in force transmission across the knee. *Clin Orthop* 1975;109:184.
  249. Walsh WM. Patellofemoral joint. In DeLee JC, Drez D, eds. *Orthopaedic sports medicine: principles and practice*. Philadelphia: WB Saunders, 1994:1163-1248.
  250. Ware JE Jr, Kosinski M, Keller SD. *SF-12: How to score the SF-12 physical and mental health summary scales*, 2nd ed. Boston: The Health Institute, New England Medical Center, 1995.
  251. Warren LF, Marshall JL. The supporting structures and layers on the medial side of the knee: an anatomical analysis. *J Bone Joint Surg* 1979;61A:56-62.
  252. Whiteside PA. Men's and women's injuries in comparable sports. *Phys Sportsmed* 1980;8(3):130-140.
  253. Wiberg G. Roentgenographic and anatomic studies of the femoropatellar joint: with special reference to chondromalacia. *Acta Orthop Scand* 1941;12:319-410.
  254. Wilk KE, Andrew JR. Current concepts in the treatment of anterior cruciate ligament disruption. *JOSPT* 1992;15(6):279-293.
  255. Wilk KE, Romaniello WT, Socia SM, Angio CA, Andrews JR. The relationship between subjective knee scores, isokinetic testing, and functional testing in the ACL-reconstructed knee. *JOSPT* 1994;20(2):60-73.
  256. Wilk KE, Zheng N, Fleisig GS, Andrews JR, Clancy WG. Kinetic chain exercise: Implications for the anterior cruciate ligament patient. *J Sport Rehab* 1997;6(2):125-143.
  257. Wiss DA, Schilz JL, Zions L. Type III fractures of the tibial tubercle in adolescents. *J Orthop Trauma* 1991;7(3):591.
  258. Wise HH, Fiebert IM, Kates JL. EMG biofeedback as treatment for patellofemoral pain syndrome. *J Orthop Sports Phys Ther* 1984;6:95-103.
  259. Wojtys EM, Loubert PV, Samson SY, Viviano DM. Use of a knee brace for control of tibial translation and rotation. *J Bone Joint Surg* 1990;72-A:1323-1329.
  260. Wojtys EM, Wylie BB, Huston LJ. The effects of muscle fatigue on neuromuscular function and anterior tibial translation in healthy knees. *Am J Sports Med* 1996;24(5):615-621.
  261. Wojtys EM. The neuromuscular effects of functional bracing. Book of abstracts & outlines, AOSSM, 23rd Annual Meeting, Sun Valley, Idaho, June 22-25, 1997:699-700.
  262. Wojtys EM, Huston LJ, Lindenfeld TN, Hewett TE, Greenfield MLVH. Correlation between the menstrual cycle and ACL injuries in female athletes. Book of abstracts & outlines, AOSSM, Sun Valley, Idaho, June 22-25, 1997.
  263. Woodall W, Welsh J. A biomechanical basis for rehabilitation programs involving the patellofemoral joint. *J Orthop Sports Phys Ther* 1990;11:11.
  264. Yamaguchi GT, Zajac FE. A planar model of the knee joint to characterize the knee extensor mechanism. *J Biomech* 1989;22:1-10.
  265. Zelisko JA, Noble HB, Porter M. A comparison of men's and women's professional basketball injuries. *Am J Sports Med* 1982;10:297-299.
  266. Zillmer DA, Powell JW, and Albright JP. Gender specific injury patterns in high school varsity basketball. *J Women's Health* 1992;1(1):69-76.